A 34-year-old man comes to the office due to shortness of breath. He reports an episodic cough and chest tightness for the past 4 months. The patient was recently on a 2-week vacation in Arizona and reports that he had no symptoms during the trip but that they restarted when he returned home. He has no prior medical conditions and takes no medications. The patient smoked marijuana in his early 20s for several years but does not use tobacco or alcohol. He started working at a chemical manufacturing factory 7 months ago and has had no sick contacts. Temperature is 36.7 C (98 F), blood pressure is 120/80 mm Hg, pulse is 76/min, and respirations are 18/min. On physical examination, expiration is mildly prolonged and there are scattered wheezes. Office spirometry shows an FEV1/FVC of 82%, and chest radiography reveals no abnormalities. Which of the following features is most likely involved in the pathogenesis of this patient's condition?

A. Exposure to inhaled allergens

B. Inhalation of fungal spores

C. Inherited protease inhibitor deficiency

D. Mutation in *BMPR2* gene

E. Necrotizing vasculitis of small vessels

Submit

A 34-year-old man comes to the office due to shortness of breath. He reports an episodic cough and chest tightness for the past 4 months. The patient was recently on a 2-week vacation in Arizona and reports that he had no symptoms during the trip but that they restarted when he returned home. He has no prior medical conditions and takes no medications. The patient smoked marijuana in his early 20s for several years but does not use tobacco or alcohol. He started working at a chemical manufacturing factory 7 months ago and has had no sick contacts. Temperature is 36.7 C (98 F), blood pressure is 120/80 mm Hg, pulse is 76/min, and respirations are 18/min. On physical examination, expiration is mildly prolonged and there are scattered wheezes. Office spirometry shows an FEV1/FVC of 82%, and chest radiography reveals no abnormalities. Which of the following features is most likely involved in the pathogenesis of this patient's condition?

- ✓ A. Exposure to inhaled allergens (67%)
- B. Inhalation of fungal spores (23%)
- C. Inherited protease inhibitor deficiency (5%)
- D. Mutation in *BMPR2* gene (2%)
- E. Necrotizing vasculitis of small vessels (1%)

Omitted
Correct answer
A

67%
Answered correctly

03 secs
Time Spent

02/03/2020
Last Updated

Explanation

This patient with dyspnea, cough, and intermittent chest tightness likely has asthma. The correlation of symptom onset after starting a new job and relief while traveling is suggestive of **occupational asthma** (OA), which accounts for up to 25% of adult-onset asthma. OA is characterized by airway inflammation, bronchial hyperreactivity, and a variable airflow obstruction triggered by a **workplace exposure**. Like other forms of

Explanation

This patient with dyspnea, cough, and intermittent chest tightness likely has asthma. The correlation of symptom onset after starting a new job and relief while traveling is suggestive of **occupational asthma** (OA), which accounts for up to 25% of adult-onset asthma. OA is characterized by airway inflammation, bronchial hyperreactivity, and a variable airflow obstruction triggered by a **workplace exposure**. Like other forms of asthma, patients may have normal chest imaging and pulmonary function tests between exacerbations.

Inciting factors in OA can be categorized as immunologic or nonimmunologic:

- Immunologic: Similar to atopic asthma, exposure to workplace aero-allergens induces a Th2-mediated reaction, which stimulates IgE formation and eosinophilic activation. There is often a **latent period** before symptoms develop during which the patient is sensitized to an allergen. Common causes include cereals, latex, and chemicals (eg, formaldehyde, amines, dyes).
- Nonimmunologic: Exposure to aero-irritants induces denudation of the airway mucosa, resulting in persistent airway inflammation, loss of epithelial relaxation factors, and mast cell degranulation. This typically occurs after large accidental exposures (eg, chemical spill), and symptom onset is sudden and severe. Common causes include chlorine and ammonia.

(Choice B) Coccidioidomycosis is endemic to the southwestern United States. In addition to cough and chest pain, patients commonly have fever, arthralgia, and skin manifestations, and imaging often demonstrates hilar adenopathy. This patient developed symptoms prior to his travel to Arizona.

(Choice C) Alpha-1 antitrypsin deficiency is an inherited disorder that causes panacinar emphysema. Patients present with dyspnea, cough, and wheezing; however, imaging typically reveals basilar bullous changes and spirometry shows an obstructive pattern.

(Choice D) *BMPR2* gene mutations cause idiopathic pulmonary hypertension; symptoms include progressive dyspnea and fatigue. However, cough, wheezing, and the resolution of symptoms while traveling is unexpected. In addition, imaging often reveals enlarged pulmonary arteries.

(Choice E) Eosinophilic granulomatosis with polyangiitis (Churg-Strauss) is a vasculitis of small- or medium-sized arteries characterized by asthma and rhinitis. However, imaging typically demonstrates patchy infiltrates, and symptoms would not be expected to resolve while traveling.

Educational objective:

Occupational asthma is characterized by airway inflammation, bronchial hyperreactivity, and a variable airflow obstruction triggered by workplace

- Immunologic: Similar to atopic asthma, exposure to workplace aero-allergens induces a Th2-mediated reaction, which stimulates IgE formation and eosinophilic activation. There is often a **latent period** before symptoms develop during which the patient is sensitized to an allergen. Common causes include cereals, latex, and chemicals (eg, formaldehyde, amines, dyes).

- Nonimmunologic: Exposure to aero-irritants induces denudation of the airway mucosa, resulting in persistent airway inflammation, loss of epithelial relaxation factors, and mast cell degranulation. This typically occurs after large accidental exposures (eg, chemical spill), and symptom onset is sudden and severe. Common causes include chlorine and ammonia.

(Choice B) Coccidioidomycosis is endemic to the southwestern United States. In addition to cough and chest pain, patients commonly have fever, arthralgia, and skin manifestations, and imaging often demonstrates hilar adenopathy. This patient developed symptoms prior to his travel to Arizona.

(Choice C) Alpha-1 antitrypsin deficiency is an inherited disorder that causes panacinar emphysema. Patients present with dyspnea, cough, and wheezing; however, imaging typically reveals basilar bullous changes and spirometry shows an obstructive pattern.

(Choice D) *BMPR2* gene mutations cause idiopathic pulmonary hypertension; symptoms include progressive dyspnea and fatigue. However, cough, wheezing, and the resolution of symptoms while traveling is unexpected. In addition, imaging often reveals enlarged pulmonary arteries.

(Choice E) Eosinophilic granulomatosis with polyangiitis (Churg-Strauss) is a vasculitis of small- or medium-sized arteries characterized by asthma and rhinitis. However, imaging typically demonstrates patchy infiltrates, and symptoms would not be expected to resolve while traveling.

Educational objective:
Occupational asthma is characterized by airway inflammation, bronchial hyperreactivity, and a variable airflow obstruction triggered by workplace exposure. Exposure can be immunologic (atopic), due to exposure to a workplace aeroallergen causing a Th2-mediated IgE formation, or nonimmunologic, due to exposure to workplace irritants that lead to denudation of the bronchial mucosa.

Pathophysiology	Pulmonary & Critical Care	Asthma
Subject	System	Topic

Copyright © UWorld. All rights reserved.

- Immunologic: Similar to atopic asthma, exposure to workplace aero-allergens induces a Th2-mediated reaction, which stimulates IgE

Exhibit Display

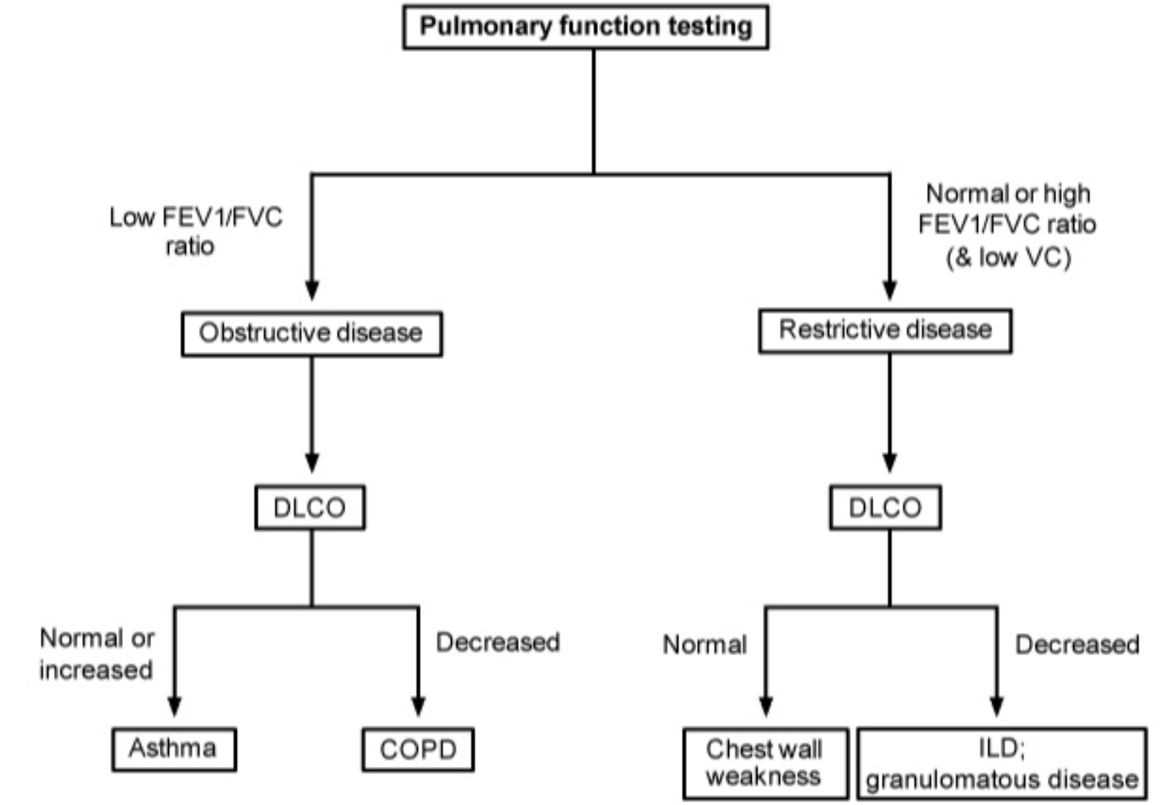

COPD = chronic obstructive pulmonary disease; **DLCO** = diffusion capacity of the lung for carbon monoxide; **FEV1** = forced expiratory volume in 1 second; **FVC** = forced vital capacity; **ILD** = interstitial lung disease; **VC** = vital capacity.

©UWorld

Zoom In | Zoom Out | Reset | Add To New Card | Existing Card

Settings

1
2
3
4
5
6
7
8
9
10
11
12
13
14
15
16
17
18
19
20
21
22
23
24
25
26
27
28
29
30

Item 2 of 40
Question Id: 523

Mark | Previous | Next | Full Screen | Tutorial | Lab Values | Notes | Calculator | Reverse Color | Text Zoom | Settings

A 48-year-old man is evaluated for shortness of breath and dry cough for 1 week. The patient has never had similar symptoms in the past and takes no medications. He has a 5-pack-year smoking history and does not use alcohol or illicit drugs. The patient is a pig farmer in Ohio and has not traveled recently. Temperature is 37.8 C (100 F), blood pressure is 128/85 mm Hg, pulse is 95/min, and respirations are 16/min. Lung auscultation reveals scattered wheezing and crackles. Peripheral blood smear is shown below.

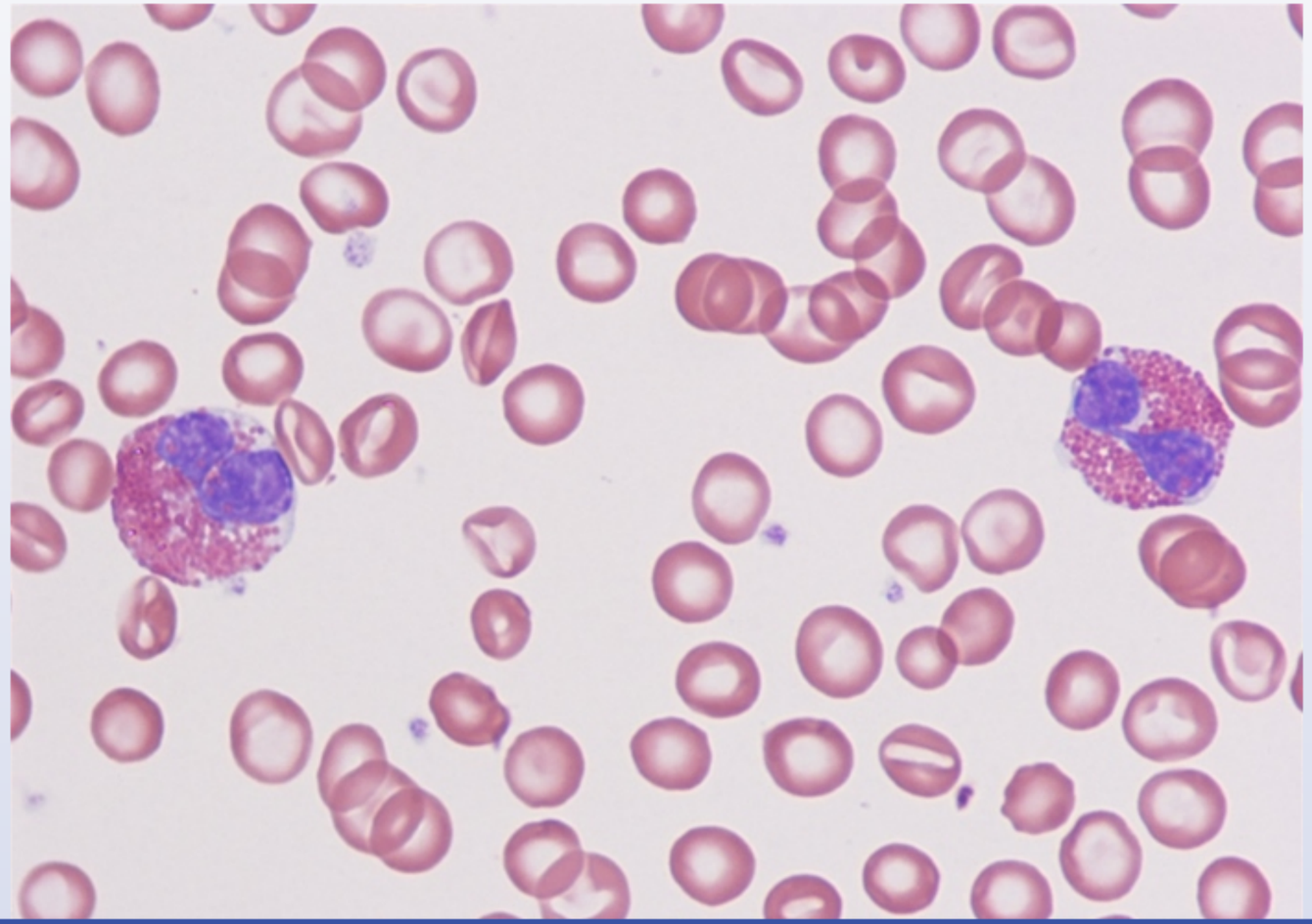

Block Time Remaining: 00:00:05
TUTOR

2 | Feedback | Suspend | End Block

Settings

1
2
3
4
5
6
7
8
9
10
11
12
13
14
15
16
17
18
19
20
21
22
23
24
25
26
27
28
29
30

Item 2 of 40
Question Id: 523

Mark | Previous | Next | Full Screen | Tutorial | Lab Values | Notes | Calculator | Reverse Color | Text Zoom | Settings

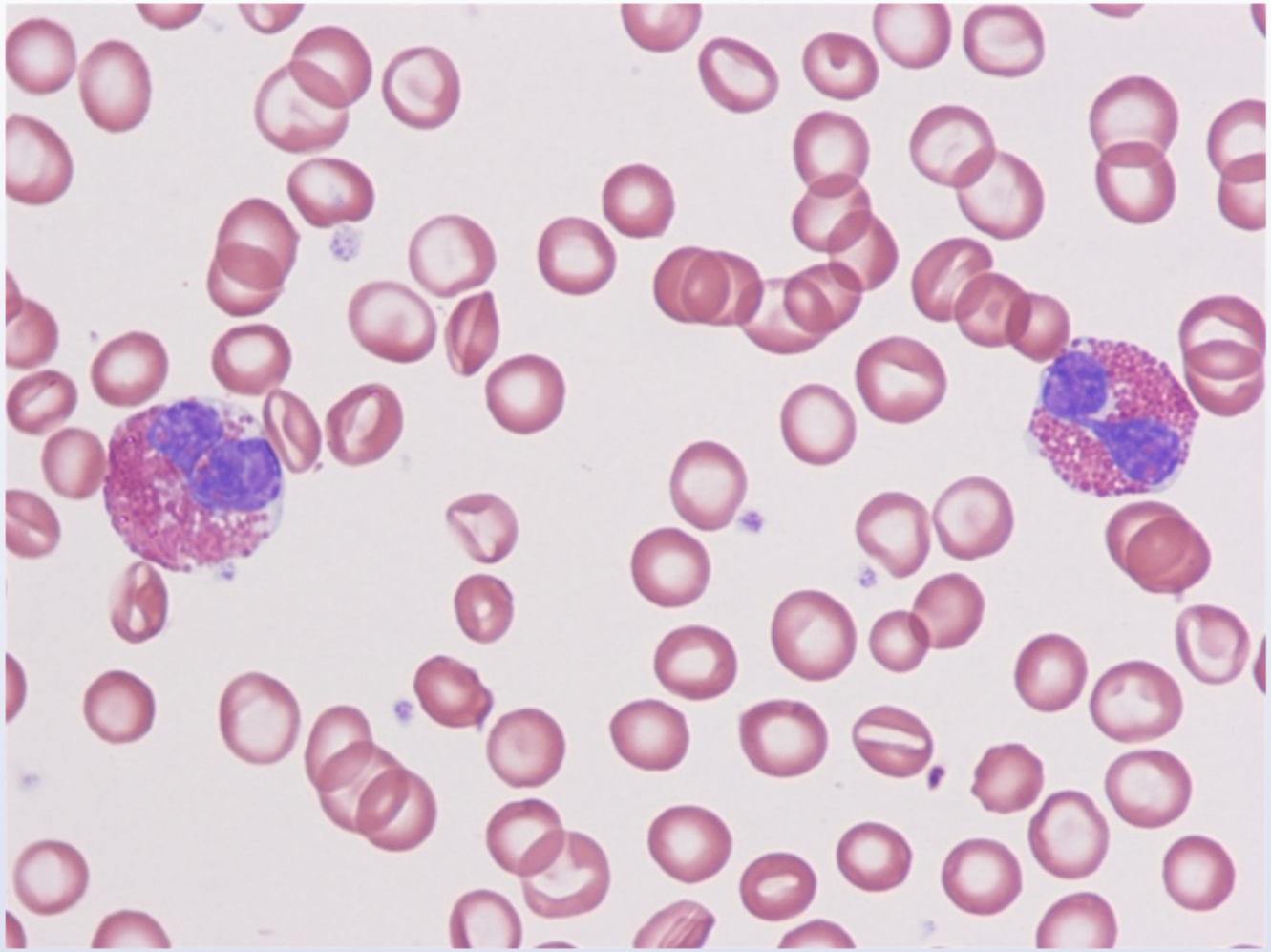

In this patient, the nucleated cells seen on the peripheral smear are most likely helping with which of the following functions?

A. Bacterial opsonization

Block Time Remaining: 00:00:07
TUTOR

2 | Feedback | Suspend | End Block

Settings

1
2
3
4
5
6
7
8
9
10
11
12
13
14
15
16
17
18
19
20
21
22
23
24
25
26
27
28
29
30

Item 2 of 40
Question Id: 523

Mark | Previous | Next | Full Screen | Tutorial | Lab Values | Notes | Calculator | Reverse Color | Text Zoom | Settings

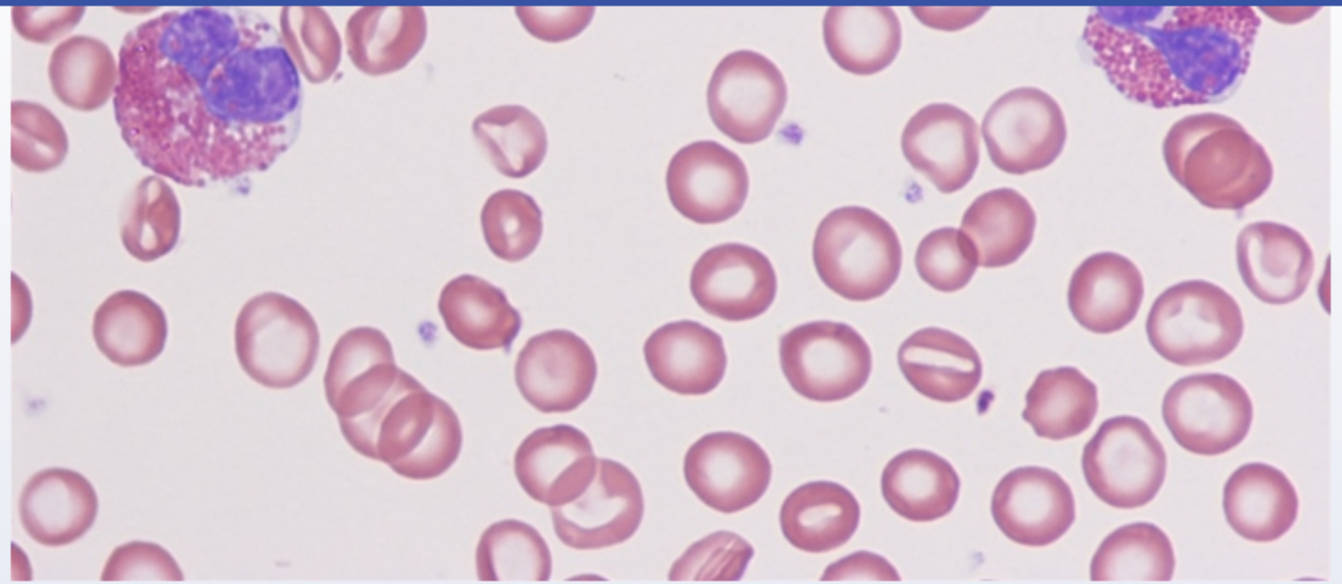

In this patient, the nucleated cells seen on the peripheral smear are most likely helping with which of the following functions?

- A. Bacterial opsonization
- B. Destruction of helminths
- C. Inhibition of fungal growth
- D. Killing of virus-infected cells
- E. Stimulation of fibroblasts

Submit

Block Time Remaining: 00:00:09
TUTOR

2 | Feedback | Suspend | End Block

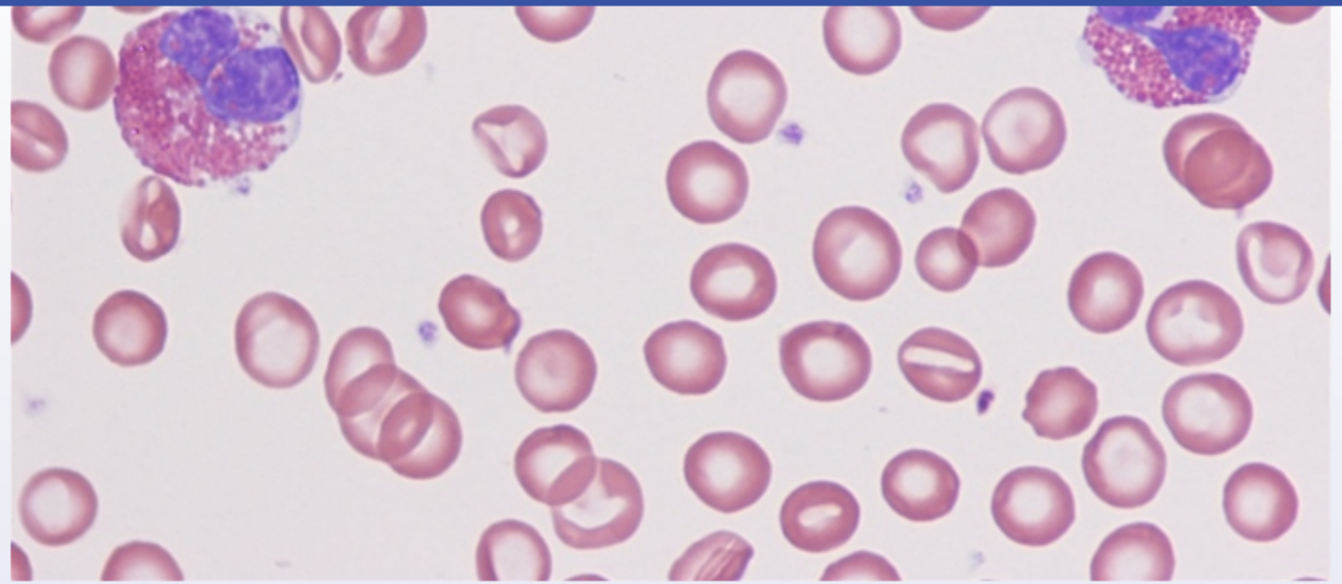

In this patient, the nucleated cells seen on the peripheral smear are most likely helping with which of the following functions?

- A. Bacterial opsonization (12%)
- ✓ B. Destruction of helminths (62%)
- C. Inhibition of fungal growth (17%)
- D. Killing of virus-infected cells (4%)
- E. Stimulation of fibroblasts (3%)

Omitted
Correct answer

62%
Answered correctly

07 secs
Time Spent

06/20/2020
Last Updated

Explanation

This pig farmer with cough and dyspnea has likely developed Löeffler syndrome (eosinophilic invasion of the lungs due to parasitic infection) from infection with the roundworm, *Ascaris*. The patient's peripheral smear shows numerous erythrocytes and a few scattered platelets accompanied by 2 larger cells with **bilobed nuclei** and **eosinophilic granules**; the 2 larger cells are **eosinophils**. Eosinophils play a prominent role in allergic disease (eg, asthma, drug reactions) and in defense against parasitic infection. **Major basic protein** is the predominant substance contained within eosinophilic granules, and it acts as a potent toxin against **helminths** (parasitic worms). Release of major basic protein by eosinophils causes damage to epithelial and endothelial cells and is a major mechanism of chronic lung damage in certain pulmonary conditions (eg, **asthma**, *Ascaris* infection).

(Choice A) Plasma cells produce antibodies that opsonize bacteria to facilitate phagocytosis.

(Choice C) Pattern recognition receptors (eg, dectin-1) on phagocytic cells allow for detection and destruction of fungi by the innate immune system.

(Choice D) Virus-infected cells typically lack MHC class I proteins on their surface; these cells are identified and killed by natural killer cells.

(Choice E) Macrophages secrete transforming growth factor-beta (TGF-β), which stimulates fibroblasts to release collagen and form scar tissue.

Educational objective:
Eosinophils have bilobed nuclei and numerous eosinophilic granules in the cytoplasm and are important in allergic disease and defense against parasitic infection. The eosinophilic granules predominantly contain major basic protein, which, once released, acts as a potent antihelminthic toxin. Major basic protein also damages epithelial and endothelial cells and is a major cause of chronic lung damage in asthma.

Pathophysiology	Pulmonary & Critical Care	Asthma
Subject	System	Topic

Copyright © UWorld. All rights reserved.

A 53-year-old man is being evaluated for dyspnea. The graph on the right shows how the patient's work of breathing varies with respiratory rate, whereas the graph on left represents the work of breathing versus respiratory rate in a normal individual. The minute ventilation is constant and equal in both graphs.

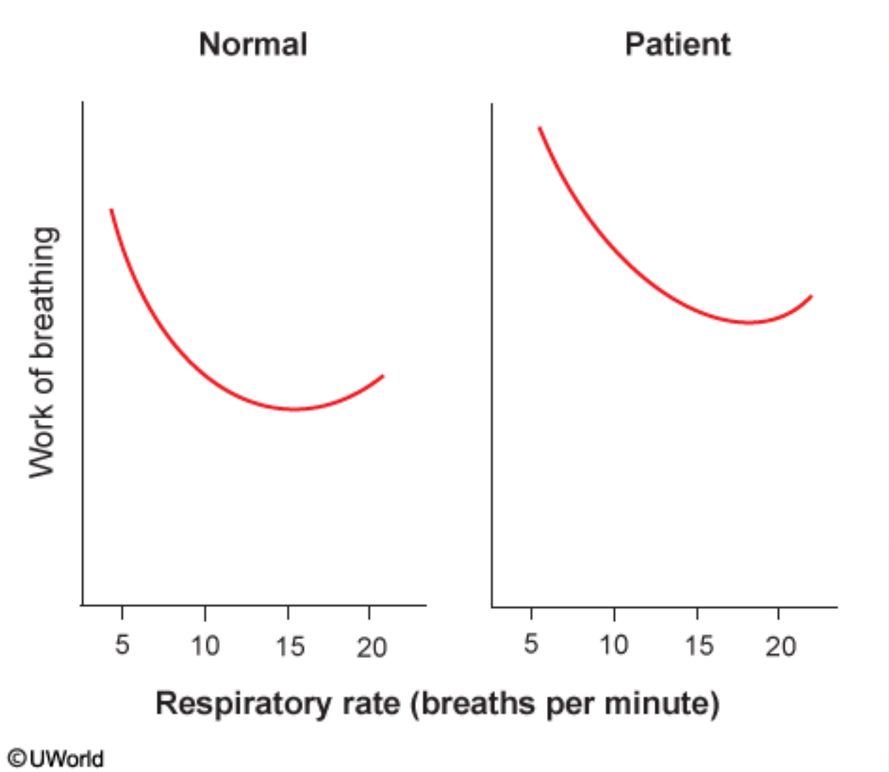

Which of the following is the most likely diagnosis in this patient?

A. Alpha-1 antitrypsin deficiency

B. Anxiety disorder

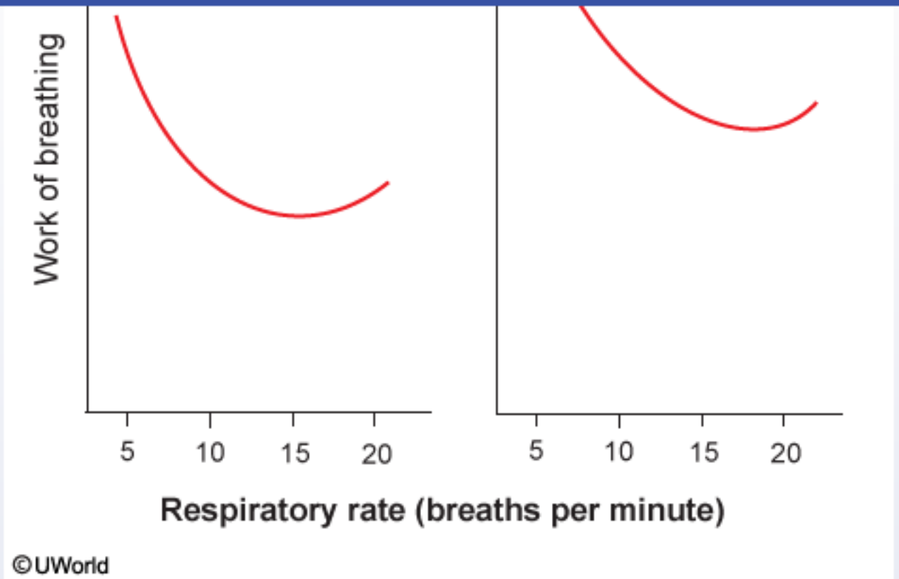

Which of the following is the most likely diagnosis in this patient?

- A. Alpha-1 antitrypsin deficiency
- B. Anxiety disorder
- C. Asthma
- D. Goiter
- E. Pulmonary fibrosis

Submit

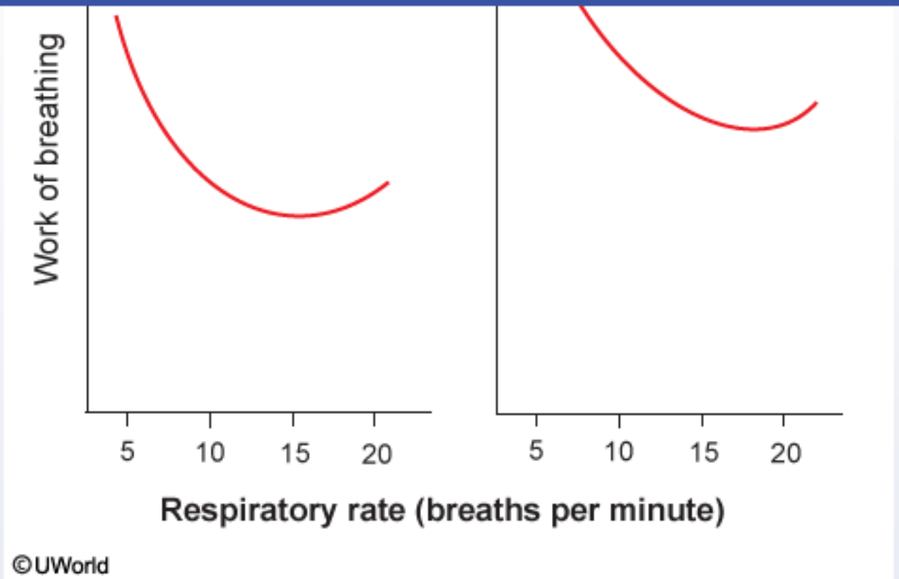

Which of the following is the most likely diagnosis in this patient?

A. Alpha-1 antitrypsin deficiency (17%)

B. Anxiety disorder (3%)

C. Asthma (11%)

D. Goiter (1%)

✓ E. Pulmonary fibrosis (65%)

Omitted
Correct answer

65%
Answered correctly

05 secs
Time Spent

04/26/2020
Last Updated

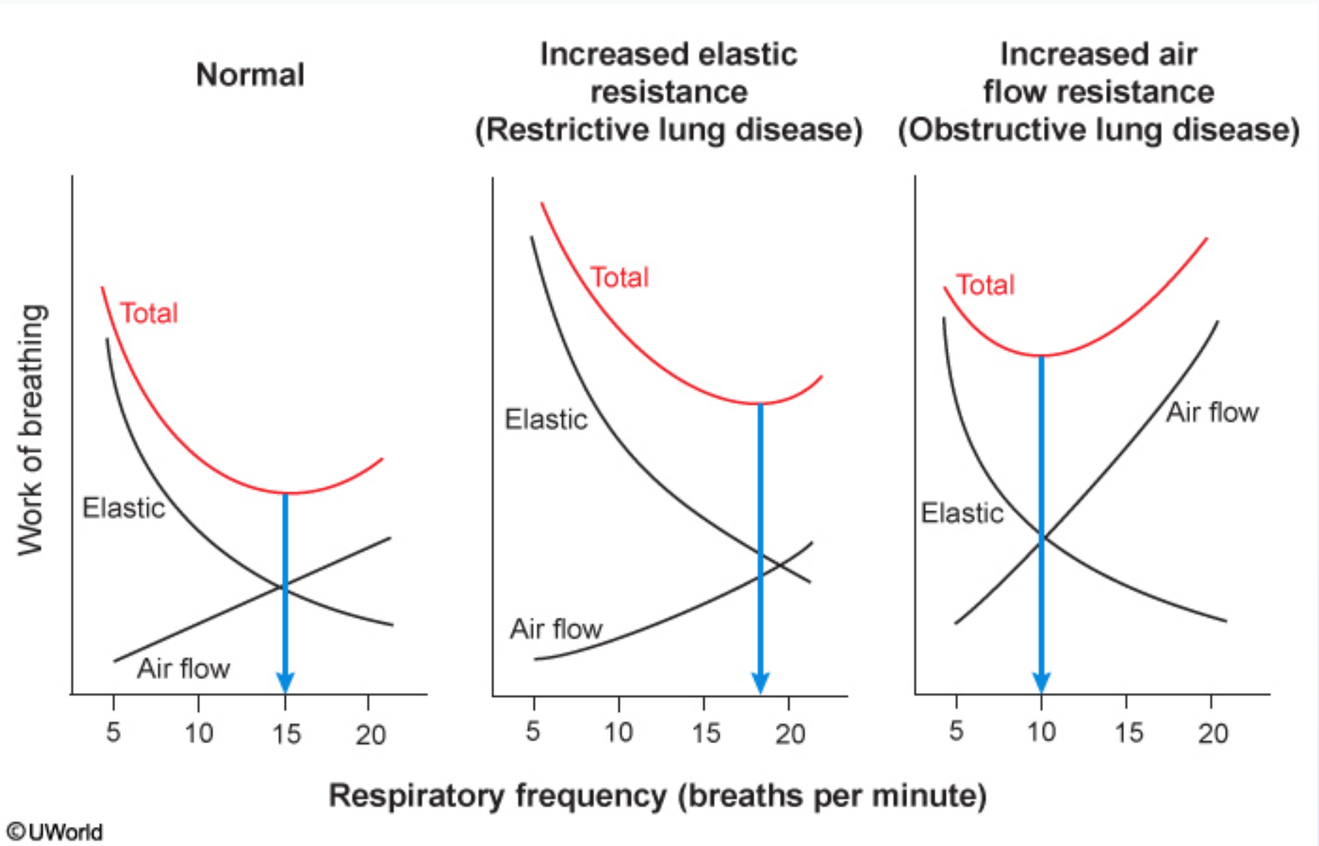

Work of breathing (WOB) is the energy expended during respiration, and comprises the work required to overcome both elastic and airflow resistance:

- **Elastic resistance** is the opposition to lung expansion caused by the intrinsic elastic properties of the lungs and chest wall; it is increased at higher tidal volumes (elastic recoil increases at high lung volumes). **Restrictive lung diseases** (eg, pulmonary fibrosis, severe obesity) are characterized by higher than normal elastic resistance. Interstitial fibrosis increases lung stiffness whereas severe obesity increases chest wall stiffness.

©UWorld

Work of breathing (WOB) is the energy expended during respiration, and comprises the work required to overcome both elastic and airflow resistance:

- **Elastic resistance** is the opposition to lung expansion caused by the intrinsic elastic properties of the lungs and chest wall; it is increased at higher tidal volumes (elastic recoil increases at high lung volumes). **Restrictive lung diseases** (eg, pulmonary fibrosis, severe obesity) are characterized by higher than normal elastic resistance. Interstitial fibrosis increases lung stiffness whereas severe obesity increases chest wall stiffness.
- **Airflow resistance** is the opposition to airflow created by limited airway diameter and turbulent airflow; it is increased at higher respiratory rates (due to faster airflow with increased turbulence) and at low lung volumes (due to reduced airway diameter). **Obstructive lung diseases** (eg, asthma, chronic obstructive pulmonary disease) increase airflow resistance due to bronchoconstriction and/or airway collapse.

To reduce the WOB, the tidal volume and respiratory rate are optimized by the respiratory control centers. In patients with **restrictive lung disease**, the WOB is minimized when the tidal volume is low. Therefore, to compensate for low lung volumes, **rapid**, **shallow breathing** is favored (as in this patient). In contrast, in patients who have obstructive lung disease, the WOB is minimized with lower respiratory rates and higher tidal volumes (ie, relatively slow, deep breathing) **(Choice C)**.

(Choice A) Alpha-1 antitrypsin deficiency causes panacinar emphysema, a type of chronic obstructive pulmonary disease. This causes increased airflow resistance, and slow, deep breaths will be favored to minimize the WOB.

(Choice B) Anxiety disorders (eg, panic attacks) are occasionally associated with rapid, shallow breathing; however, the lungs function normally and, therefore, the WOB versus the respiratory rate curve is normal. Because the breathing rate is higher than the normal optimal rate, the work done against airflow resistance (and total work) is increased.

(Choice D) A fixed upper airway obstruction (eg, caused by a large goiter) leads to increased air flow resistance and favors slow, deep breaths to minimize the WOB.

Educational objective:
The work of breathing is minimized in patients with increased elastic resistance (eg, pulmonary fibrosis) when their respiratory rate is high and tidal

- **Airflow resistance** is the opposition to airflow created by limited airway diameter and turbulent airflow; it is increased at higher respiratory rates (due to faster airflow with increased turbulence) and at low lung volumes (due to reduced airway diameter). **Obstructive lung diseases** (eg, asthma, chronic obstructive pulmonary disease) increase airflow resistance due to bronchoconstriction and/or airway collapse.

To reduce the WOB, the tidal volume and respiratory rate are optimized by the respiratory control centers. In patients with **restrictive lung disease**, the WOB is minimized when the tidal volume is low. Therefore, to compensate for low lung volumes, **rapid**, **shallow breathing** is favored (as in this patient). In contrast, in patients who have obstructive lung disease, the WOB is minimized with lower respiratory rates and higher tidal volumes (ie, relatively slow, deep breathing) **(Choice C)**.

(Choice A) Alpha-1 antitrypsin deficiency causes panacinar emphysema, a type of chronic obstructive pulmonary disease. This causes increased airflow resistance, and slow, deep breaths will be favored to minimize the WOB.

(Choice B) Anxiety disorders (eg, panic attacks) are occasionally associated with rapid, shallow breathing; however, the lungs function normally and, therefore, the WOB versus the respiratory rate curve is normal. Because the breathing rate is higher than the normal optimal rate, the work done against airflow resistance (and total work) is increased.

(Choice D) A fixed upper airway obstruction (eg, caused by a large goiter) leads to increased air flow resistance and favors slow, deep breaths to minimize the WOB.

Educational objective:
The work of breathing is minimized in patients with increased elastic resistance (eg, pulmonary fibrosis) when their respiratory rate is high and tidal volume is low (fast, shallow breaths). In contrast, patients with diseases that increase airflow resistance (eg, asthma, chronic obstructive pulmonary disease) breathe at a lower respiratory rate and higher tidal volume (slow, deep breaths) to minimize the work of breathing.

Pathophysiology	Pulmonary & Critical Care	Interstitial lung disease
Subject	System	Topic

Copyright © UWorld. All rights reserved.

A 63-year-old man undergoes a sleep study, during which he is closely observed for a full night. Several physiologic parameters, such as oxygen saturation, heart rhythm, cerebral electrical activity, respiratory airflow, and movements of the chest and upper abdominal walls, are continuously recorded. The following graph depicts a recording obtained over a period of several minutes:

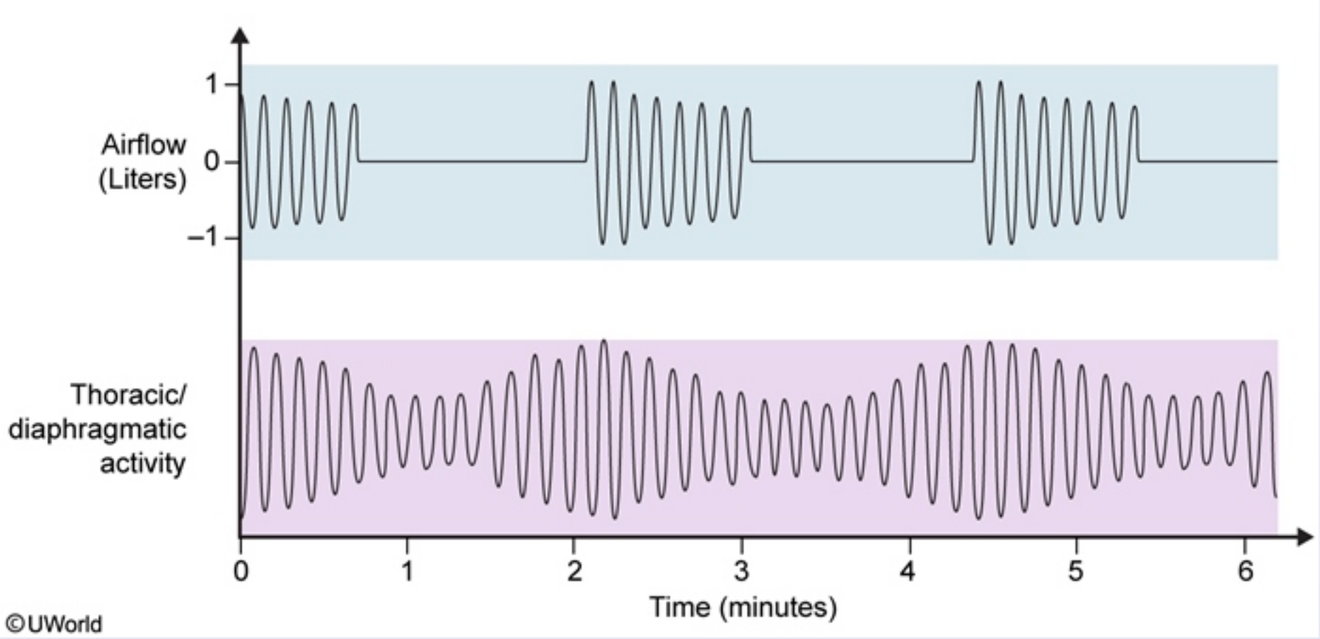

Which of the following is the most likely cause of the observed findings?

A. Advanced heart failure

B. Diffuse lung fibrosis

C. Neuromuscular weakness

D. Severe ketoacidosis

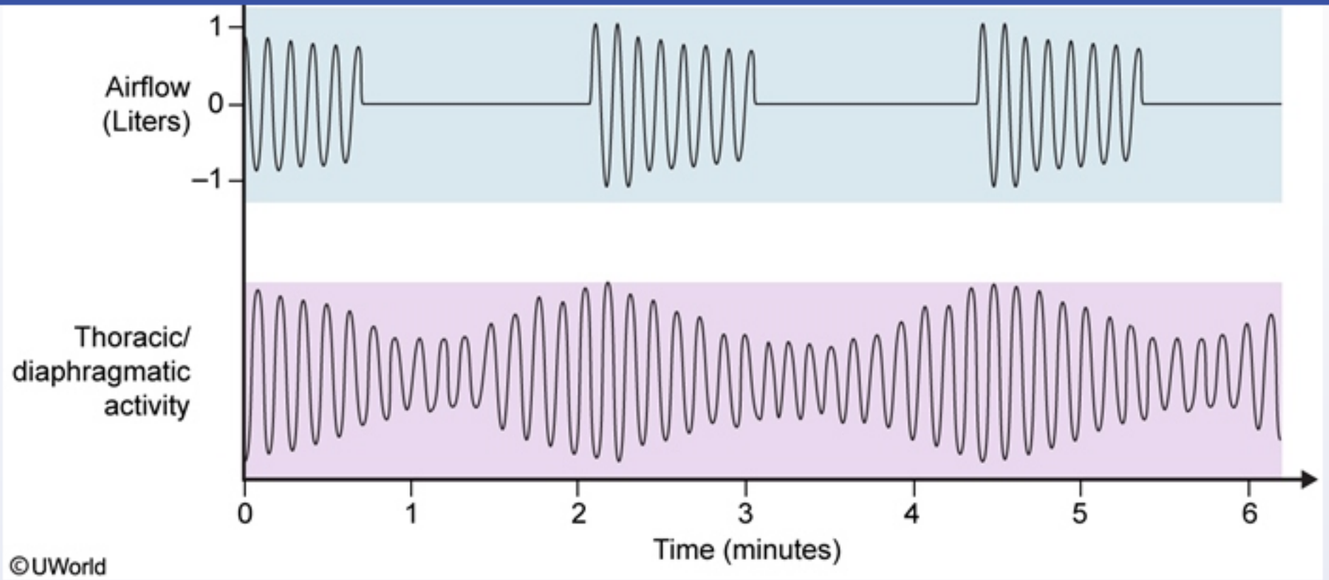

Which of the following is the most likely cause of the observed findings?

- A. Advanced heart failure
- B. Diffuse lung fibrosis
- C. Neuromuscular weakness
- D. Severe ketoacidosis
- E. Upper airway obstruction

Submit

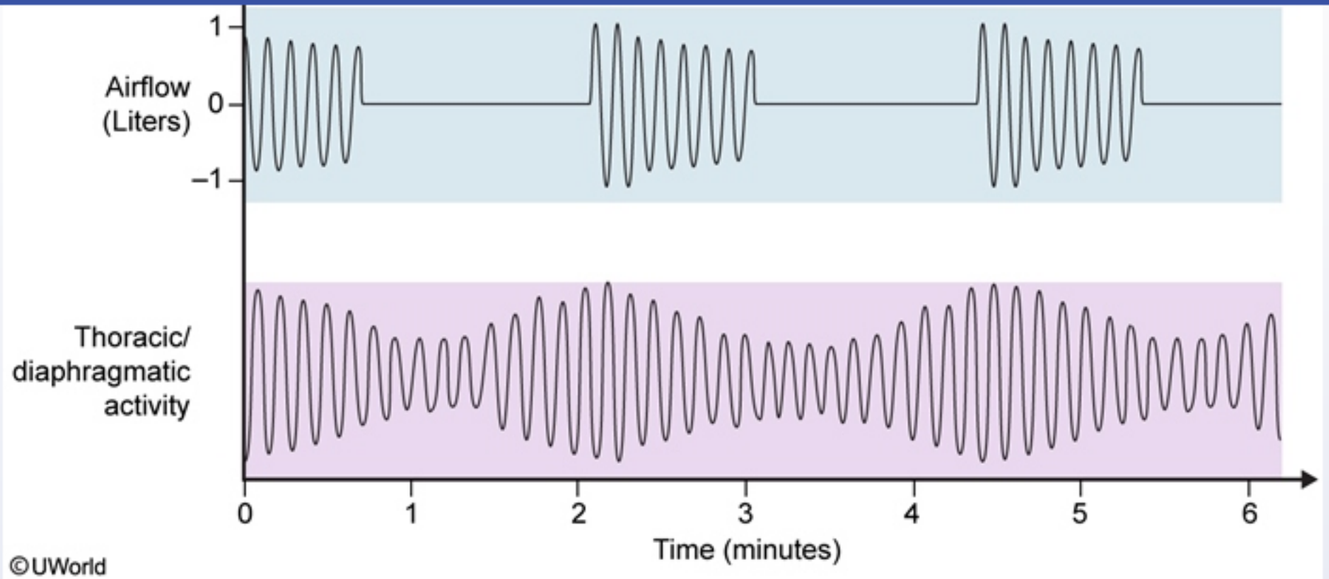

Which of the following is the most likely cause of the observed findings?

- A. Advanced heart failure (9%)
- B. Diffuse lung fibrosis (5%)
- C. Neuromuscular weakness (18%)
- D. Severe ketoacidosis (4%)
- ✓ E. Upper airway obstruction (62%)

Omitted
Correct answer

62%
Answered correctly

06 secs
Time Spent

05/06/2020
Last Updated

Explanation

This patient with prolonged pauses in airflow despite continued thoracic and diaphragmatic activity has **obstructive sleep apnea** (OSA). OSA, the most common sleep-related breathing disorder, is characterized by **recurrent obstruction of the upper airway**.

During sleep, there is relaxation of the oropharyngeal and/or soft palate musculature. In patients with OSA, this results in a **functional airway collapse** that produces periods of reduced (hypopnea) or absent **(apnea)** airflow despite continued breathing efforts. Apneic episodes may last anywhere from 10 seconds to >1 minute, resulting in **hypoxia** and **hypercapnia**. This eventually triggers chemoreceptors in the carotid body and brainstem, leading to transient arousal and resumption of breathing.

Patients may not be aware of apnea, but bed partners commonly report **loud snoring** with intermittent episodes of silence. This pattern occurs hundreds of times per night, leading to poor sleep quality and **chronic fatigue**. Risk factors for OSA include obesity, large neck circumference, and reduced oropharyngeal diameter (eg, enlarged tonsils or tongue, retro- or micrognathia).

(Choice A) Patients with advanced heart failure may exhibit Cheyne-Stokes breathing, a cyclic breathing pattern in which apnea is followed by gradually increasing then decreasing tidal volumes (crescendo-decrescendo) until the next apneic period.

(Choice B) Reduced lung compliance in pulmonary fibrosis limits tidal volume (TV) per breath. Patients exhibit rapid, shallow breathing (without apnea) to restore minute ventilation (TV × respiratory rate) and minimize the work of breathing.

(Choice C) Neuromuscular weakness (eg, Guillain-Barré syndrome) results in reduced thoracic and diaphragmatic muscle activity with rapid, shallow breathing; recurrent apnea does not occur.

(Choice D) Severe diabetic ketoacidosis can result in Kussmaul breathing (ie, deep, rapid breathing with associated increased thoracic and diaphragmatic activity). It occurs as a respiratory compensation for severe metabolic acidosis.

Educational objective:
Obstructive sleep apnea, the most common sleep-related breathing disorder, is characterized by recurrent obstruction of the upper airways. Relaxation of the oropharyngeal and/or soft palate musculature during sleep results in a functional collapse of the airway, producing periods of reduced (hypopnea) or absent (apnea) airflow despite continued breathing efforts.

References

Explanation

Exhibit Display

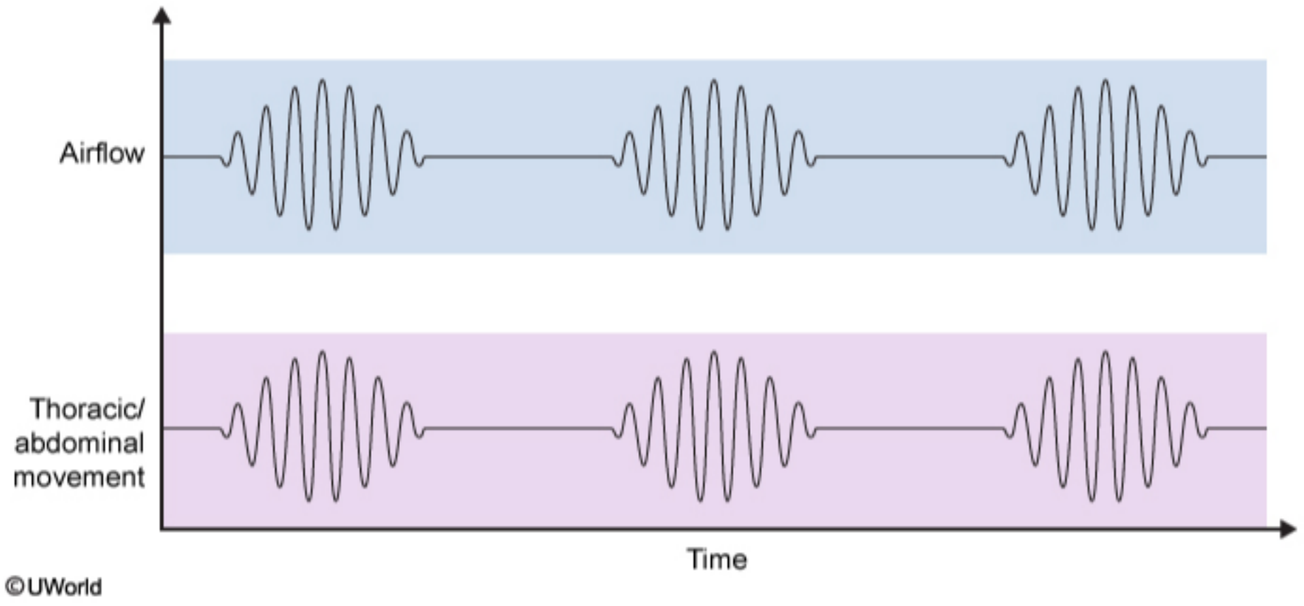

Zoom In | Zoom Out | Reset | Add To New Card | Existing Card

References

Explanation

Exhibit Display

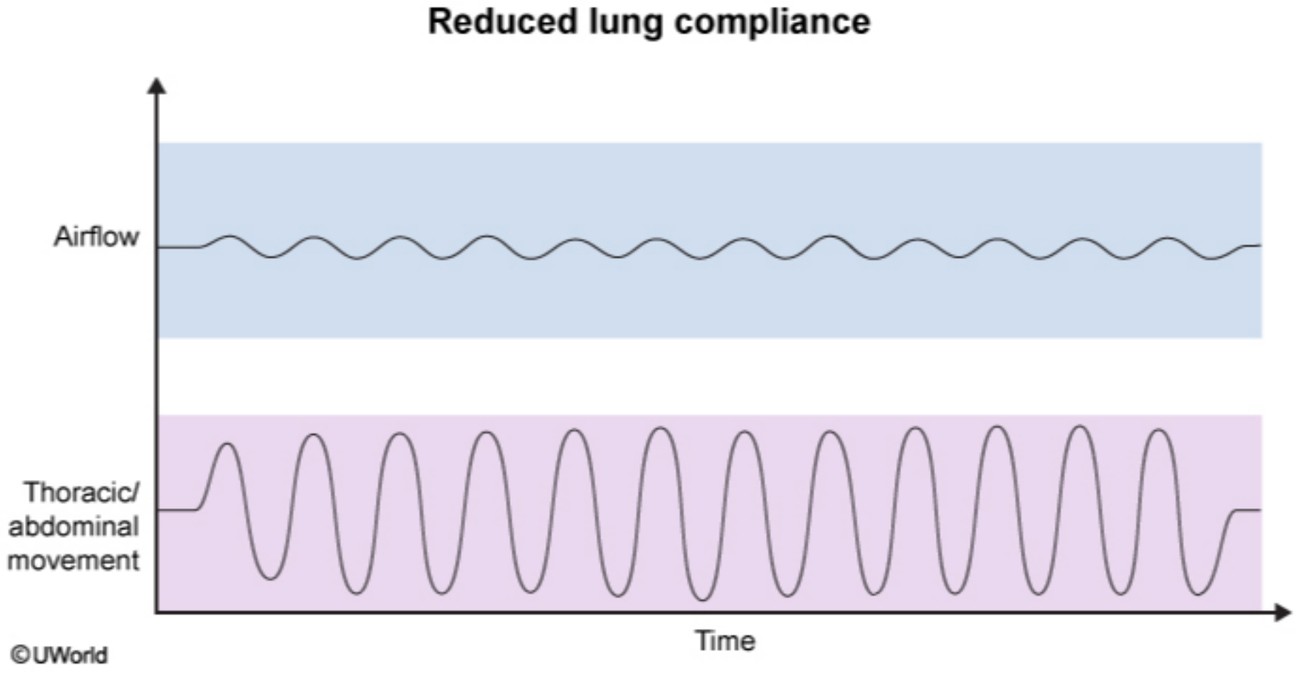

Zoom In | Zoom Out | Reset | Add To New Card | Existing Card

References

Explanation

Exhibit Display

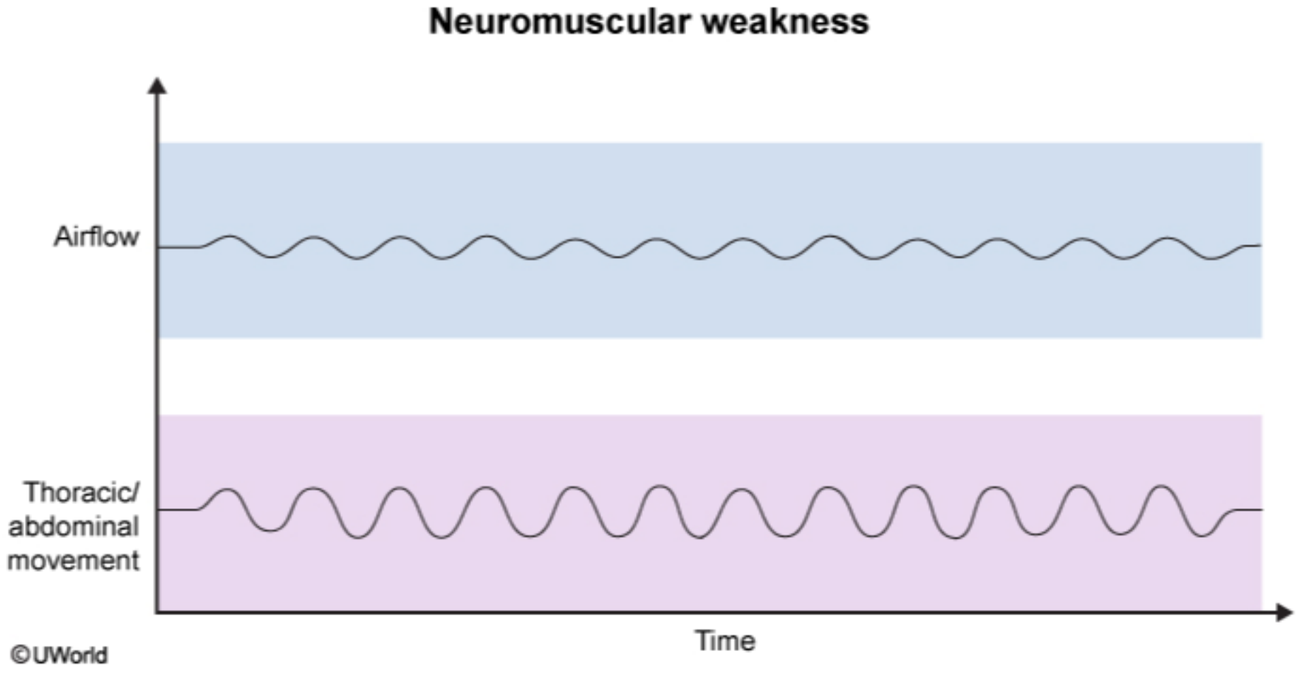

Zoom In | Zoom Out | Reset | Add To New Card | Existing Card

References

Explanation

Exhibit Display

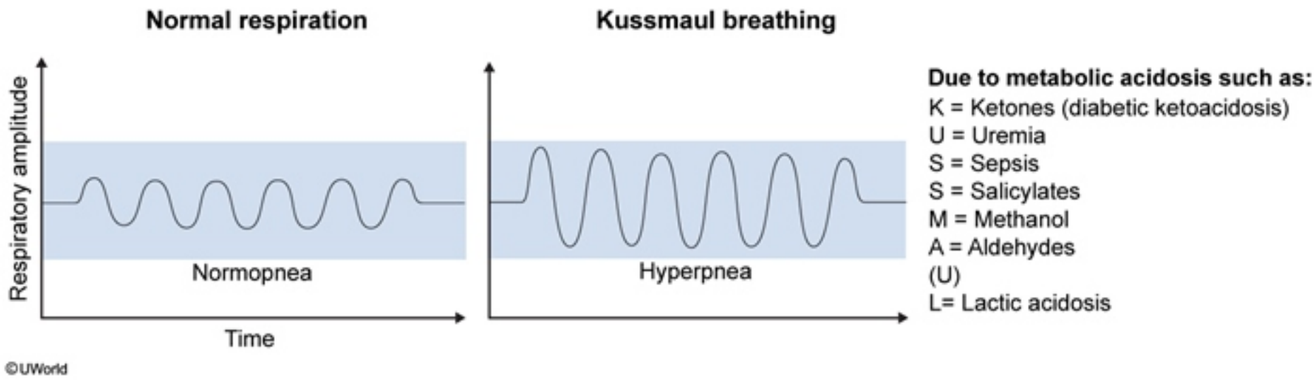

Zoom In | Zoom Out | Reset | Add To New Card | Existing Card

References

anywhere from 10 seconds to 1 minute, resulting in **hypoxia** and **hypercapnia**. This eventually triggers chemoreceptors in the carotid body and brainstem, leading to transient arousal and resumption of breathing.

Patients may not be aware of apnea, but bed partners commonly report **loud snoring** with intermittent episodes of silence. This pattern occurs hundreds of times per night, leading to poor sleep quality and **chronic fatigue**. Risk factors for OSA include obesity, large neck circumference, and reduced oropharyngeal diameter (eg, enlarged tonsils or tongue, retro- or micrognathia).

(Choice A) Patients with advanced heart failure may exhibit Cheyne-Stokes breathing, a cyclic breathing pattern in which apnea is followed by gradually increasing then decreasing tidal volumes (crescendo-decrescendo) until the next apneic period.

(Choice B) Reduced lung compliance in pulmonary fibrosis limits tidal volume (TV) per breath. Patients exhibit rapid, shallow breathing (without apnea) to restore minute ventilation (TV × respiratory rate) and minimize the work of breathing.

(Choice C) Neuromuscular weakness (eg, Guillain-Barré syndrome) results in reduced thoracic and diaphragmatic muscle activity with rapid, shallow breathing; recurrent apnea does not occur.

(Choice D) Severe diabetic ketoacidosis can result in Kussmaul breathing (ie, deep, rapid breathing with associated increased thoracic and diaphragmatic activity). It occurs as a respiratory compensation for severe metabolic acidosis.

Educational objective:
Obstructive sleep apnea, the most common sleep-related breathing disorder, is characterized by recurrent obstruction of the upper airways. Relaxation of the oropharyngeal and/or soft palate musculature during sleep results in a functional collapse of the airway, producing periods of reduced (hypopnea) or absent (apnea) airflow despite continued breathing efforts.

References

- Obstructive sleep apnea syndrome: a literature review.

Pathophysiology	Pulmonary & Critical Care	Obstructive sleep apnea
Subject	System	Topic

Copyright © UWorld. All rights reserved.

A 62-year-old man comes to the office due to shortness of breath. His symptoms have progressed over the last few months and have begun to limit his daily activities. He has no other medical problems and takes no medications. The patient drinks 3 or 4 alcoholic beverages a week and has a 50-pack-year smoking history. Physical examination reveals decreased breath sounds and scattered wheezes bilaterally. Chest x-ray is shown below.

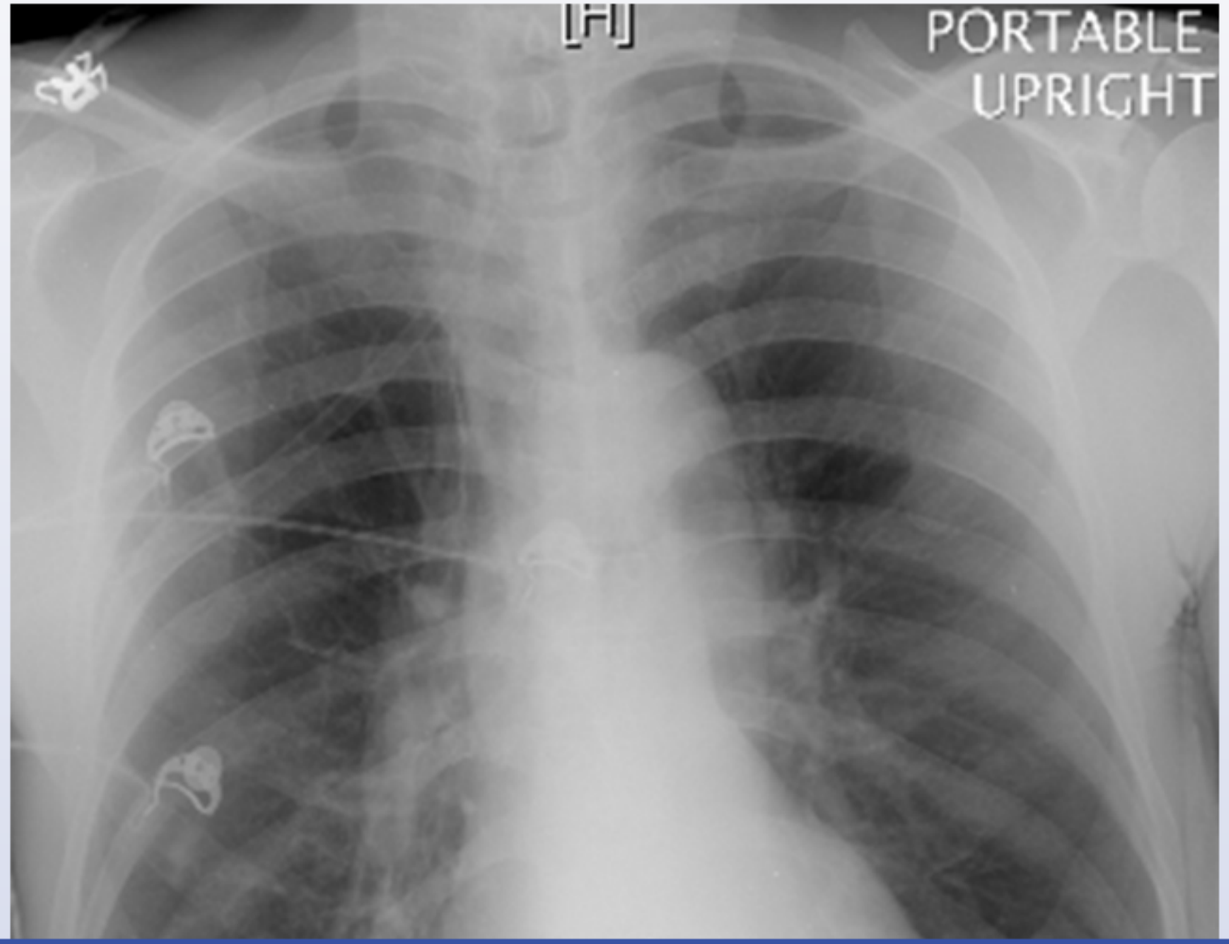

Settings

1
2
3
4
5
6
7
8
9
10
11
12
13
14
15
16
17
18
19
20
21
22
23
24
25
26
27
28
29
30

Item 5 of 40
Question Id: 522

Mark | Previous | Next | Full Screen | Tutorial | Lab Values | Notes | Calculator | Reverse Color | Text Zoom | Settings

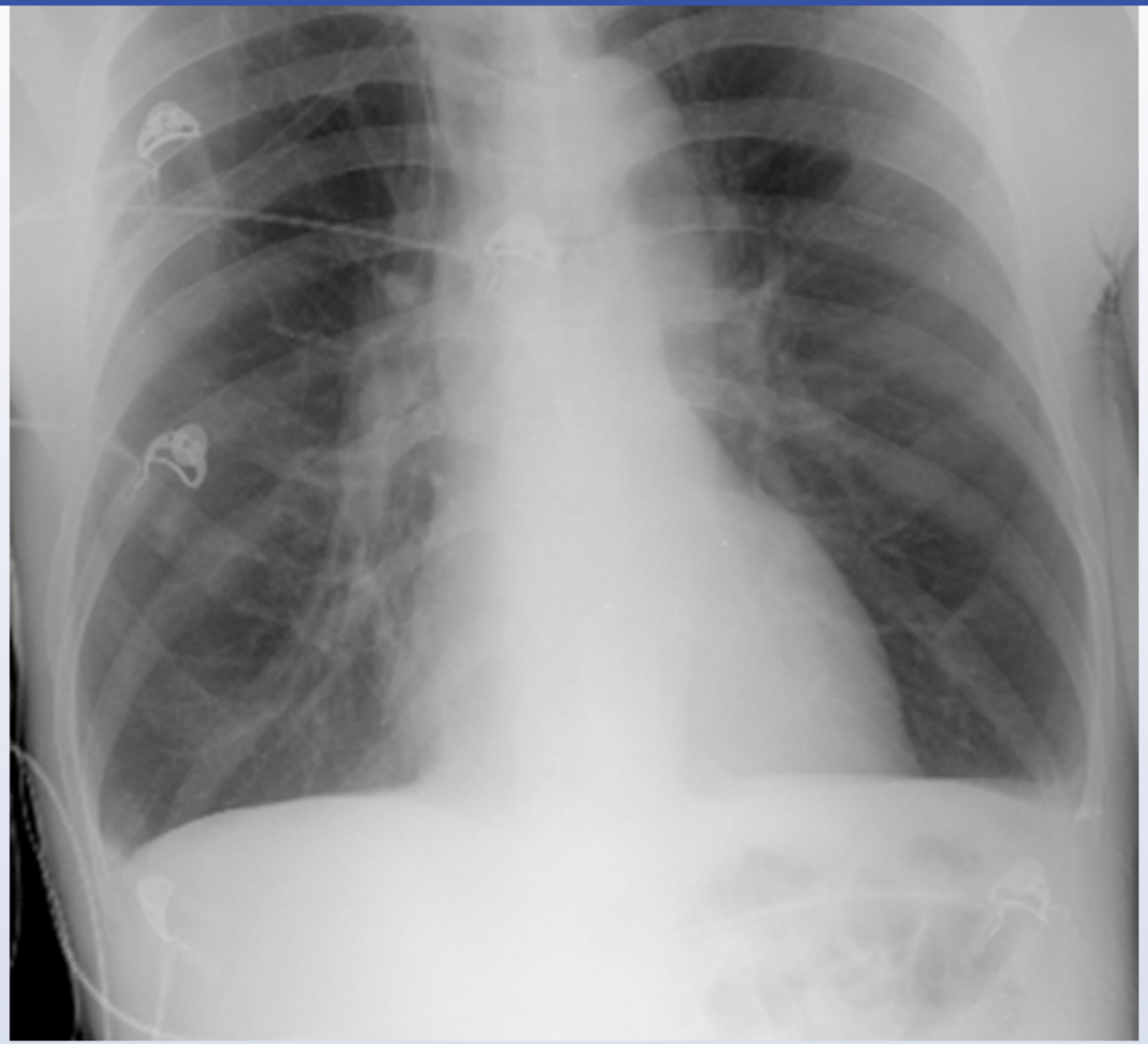

Which of the following parameters is most likely to be increased in this patient?

Block Time Remaining: 00:00:24
TUTOR

3 | Feedback | Suspend | End Block

Settings

1
2
3
4
5
6
7
8
9
10
11
12
13
14
15
16
17
18
19
20
21
22
23
24
25
26
27
28
29
30

Item 5 of 40
Question Id: 522

Mark | Previous | Next | Full Screen | Tutorial | Lab Values | Notes | Calculator | Reverse Color | Text Zoom | Settings

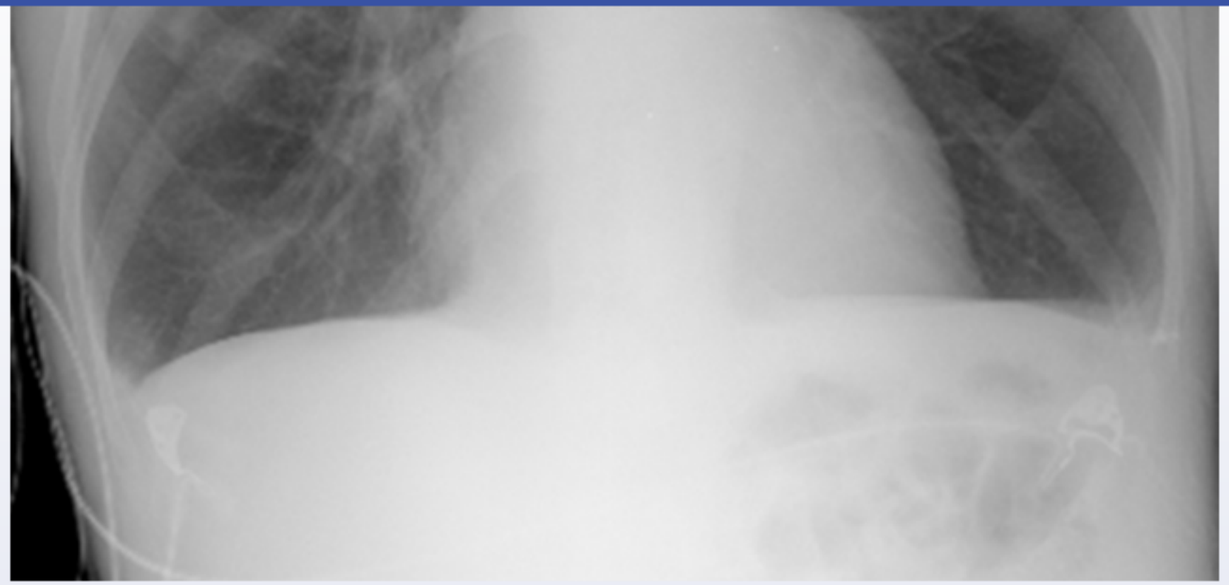

Which of the following parameters is most likely to be increased in this patient?

A. Carbon monoxide diffusion capacity

B. Expiratory flow rates

C. Forced vital capacity

D. Functional residual capacity

E. Lung elastic recoil

Submit

Block Time Remaining: 00:00:26
TUTOR

3 | Feedback | Suspend | End Block

Settings

1 2 3 4 5 6 7 8 9 10 11 12 13 14 15 16 17 18 19 20 21 22 23 24 25 26 27 28 29 30

Item 5 of 40
Question Id: 522

Mark | Previous | Next | Full Screen | Tutorial | Lab Values | Notes | Calculator | Reverse Color | Text Zoom | Settings

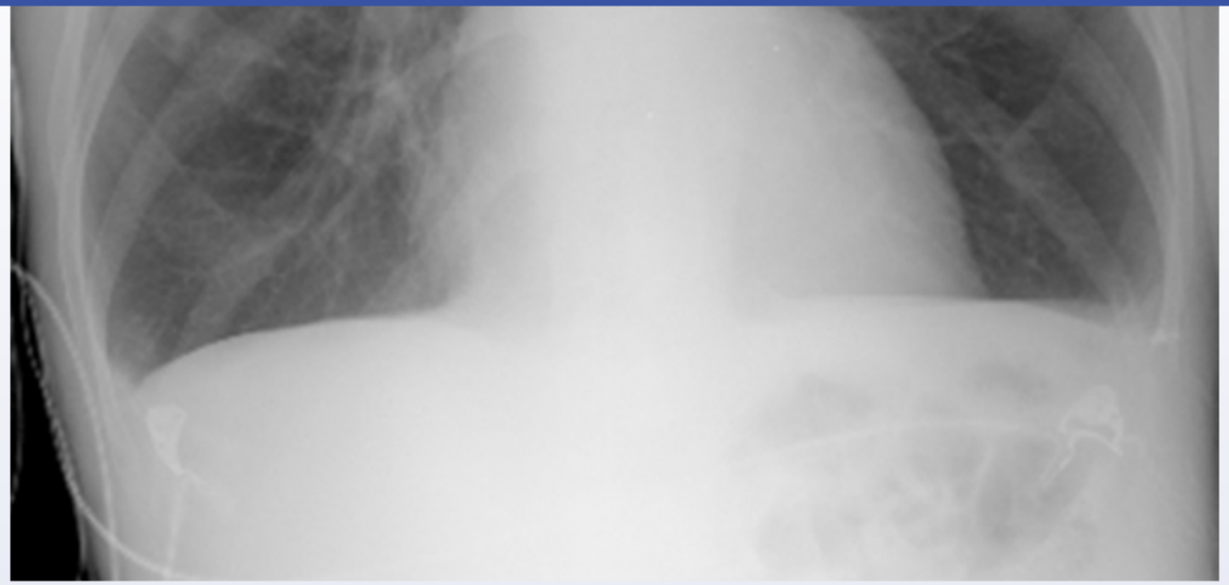

Which of the following parameters is most likely to be increased in this patient?

A. Carbon monoxide diffusion capacity (4%)

B. Expiratory flow rates (4%)

C. Forced vital capacity (5%)

✓ D. Functional residual capacity (78%)

E. Lung elastic recoil (6%)

Omitted
Correct answer

78%
Answered correctly

07 secs
Time Spent

01/25/2020
Last Updated

Block Time Remaining: 00:00:28
TUTOR

3 | Feedback | Suspend | End Block

Increased functional residual capacity (FRC) in COPD

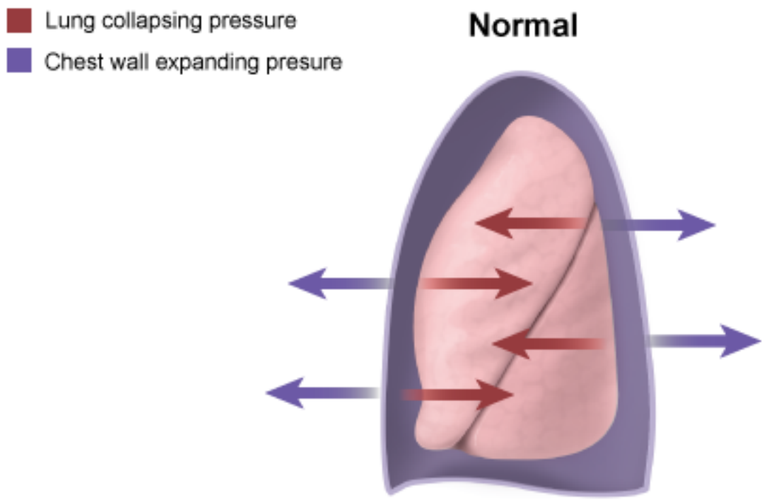

Pressures are in equilibrium at FRC

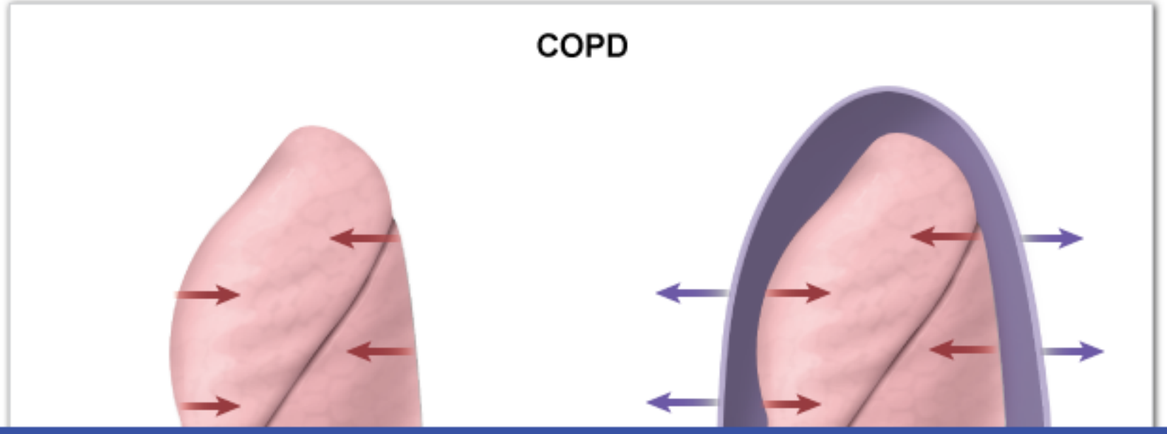

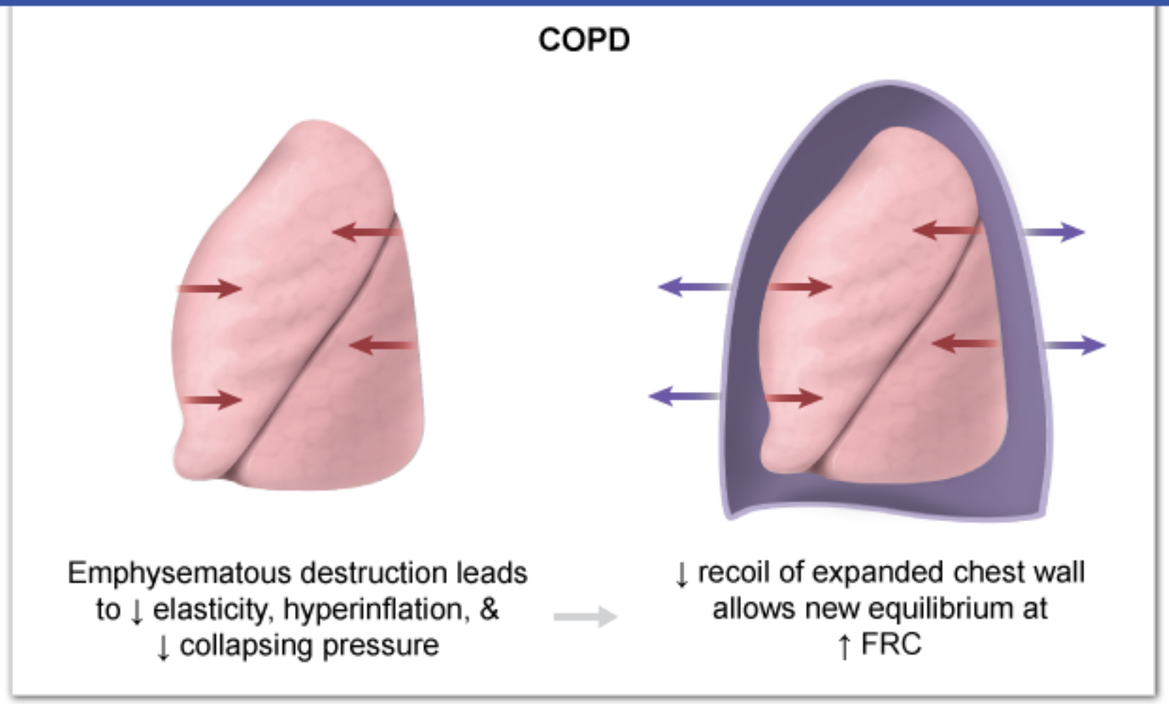

©UWorld

This patient's chest x-ray reveals **hyperinflated lungs** and a **flattened diaphragm** (compared to normal), consistent with **chronic obstructive pulmonary disease** (COPD). COPD involves components of chronic bronchitis and emphysema, both of which contribute to air-trapping and hyperinflation.

The outward expanding pressure created by the chest wall and the inward collapsing pressure created by the lungs are in equilibrium at the **functional residual capacity** (FRC). In patients with COPD, **decreased elasticity** of the alveoli (from emphysema) results in decreased collapsing pressure created by the lungs to expel air. Bronchial airway thickening and obstruction (from chronic bronchitis) further impairs lung collapse by impeding the expulsion of air. The decrease in collapsing pressure causes the chest wall to **expand outward** until the expanding pressure of the chest is balanced by the collapsing pressure of the lungs. A new pressure equilibrium is reached at a higher lung volume (ie, **higher FRC**) and, as a result, residual volume and total lung capacity are also increased.

This patient's chest x-ray reveals **hyperinflated lungs** and a **flattened diaphragm** (compared to normal), consistent with **chronic obstructive pulmonary disease** (COPD). COPD involves components of chronic bronchitis and emphysema, both of which contribute to air-trapping and hyperinflation.

The outward expanding pressure created by the chest wall and the inward collapsing pressure created by the lungs are in equilibrium at the **functional residual capacity** (FRC). In patients with COPD, **decreased elasticity** of the alveoli (from emphysema) results in decreased collapsing pressure created by the lungs to expel air. Bronchial airway thickening and obstruction (from chronic bronchitis) further impairs lung collapse by impeding the expulsion of air. The decrease in collapsing pressure causes the chest wall to **expand outward** until the expanding pressure of the chest is balanced by the collapsing pressure of the lungs. A new pressure equilibrium is reached at a higher lung volume (ie, **higher FRC**) and, as a result, residual volume and total lung capacity are also increased.

(Choice A) The diffusing capacity of the lung for carbon monoxide (DLCO) largely depends on the thickness and total surface area of the alveolar capillary membrane. In emphysema, interalveolar wall destruction decreases the alveolar-capillary surface area, reducing DLCO. Patients with emphysema may have decreased DLCO even when there is little evidence of expiratory airflow obstruction on spirometry.

(Choice B) Expiratory airflow rates are reduced in COPD due to inflammatory and fibrotic narrowing of the bronchi (chronic bronchitis) and decreased alveolar elastic recoil (emphysema).

(Choice C) In COPD, forced vital capacity is usually decreased due to expiratory airflow obstruction limiting the total expiratory volume.

(Choice E) Emphysema causes lung elastic recoil to decrease secondary to destruction of interalveolar walls.

Educational objective:
Chronic obstructive pulmonary disease involves components of chronic bronchitis and emphysema. Bronchial airway obstruction from chronic bronchitis and decreased alveolar elasticity from emphysema result in air-trapping and lung hyperinflation. The functional residual capacity is increased, as are residual volume and total lung capacity.

References

- Why does the lung hyperinflate?

Pathophysiology Pulmonary & Critical Care COPD

Settings

1 2 3 4 5 6 7 8 9 10 11 12 13 14 15 16 17 18 19 20 21 22 23 24 25 26 27 28 29 30

Item 5 of 40
Question Id: 522

Mark | Previous | Next | Full Screen | Tutorial | Lab Values | Notes | Calculator | Reverse Color | Text Zoom | Settings

This patient's chest x-ray reveals **hyperinflated lungs** and a **flattened diaphragm** (compared to normal), consistent with **chronic obstructive**

Exhibit Display

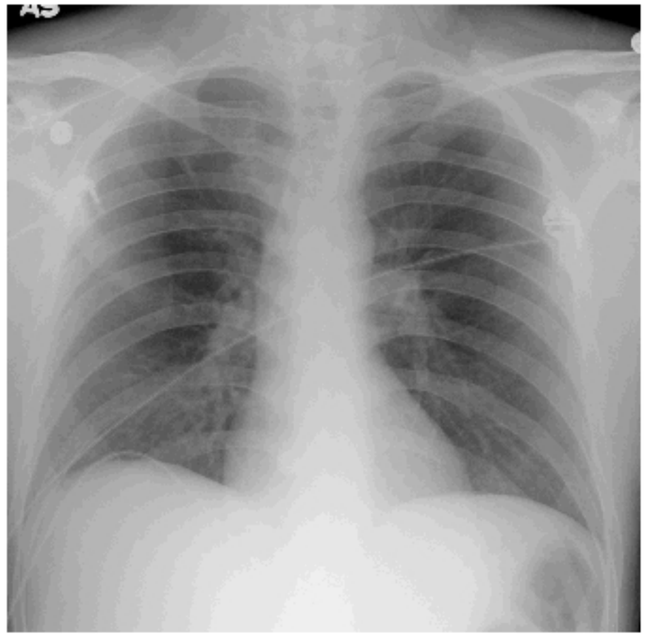

Zoom In | Zoom Out | Reset | Add To New Card | Existing Card

Pathophysiology | Pulmonary & Critical Care | COPD

Block Time Remaining: 00:00:28
TUTOR

3 | Feedback | Suspend | End Block

This patient's chest x-ray reveals **hyperinflated lungs** and a **flattened diaphragm** (compared to normal), consistent with **chronic obstructive**

Exhibit Display

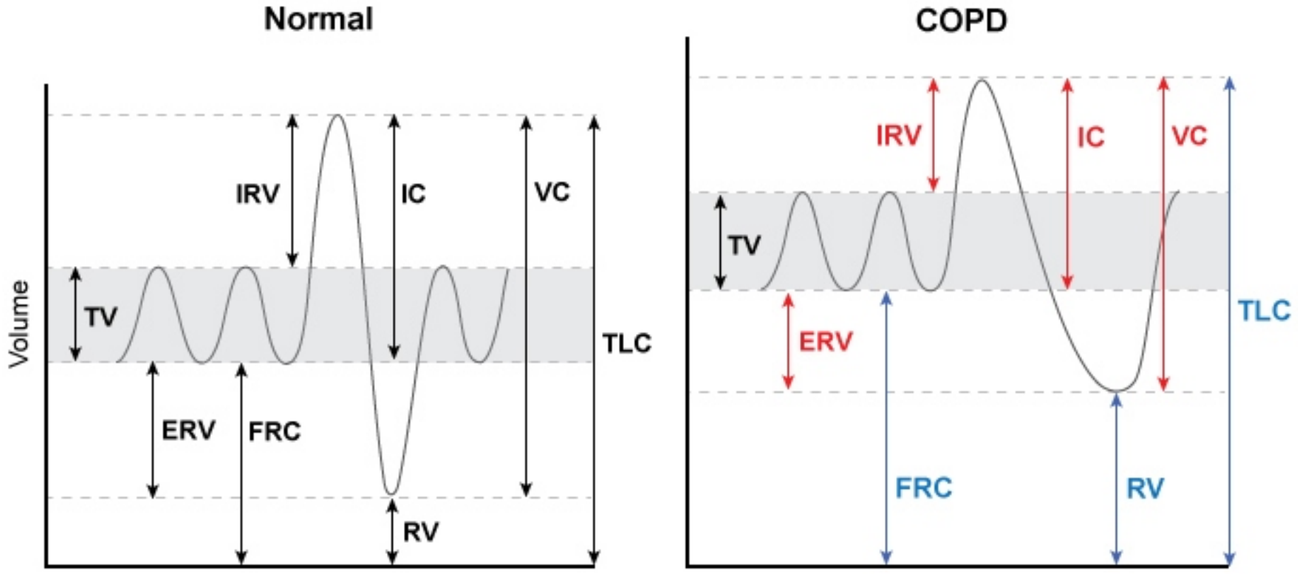

COPD = chronic obstructive pulmonary disease; **ERV** = expiratory reserve volume; **IC** = inspiratory capacity; **IRV** = inspiratory reserve volume; **FRC** = functional residual capacity; **RV** = residual volume; **TLC** = total lung capacity; **TV** = tidal volume; **VC** = vital capacity.

©UWorld

Zoom In | Zoom Out | Reset | Add To New Card | Existing Card

Pathophysiology | Pulmonary & Critical Care | COPD

hyperinflation.

The outward expanding pressure created by the chest wall and the inward collapsing pressure created by the lungs are in equilibrium at the **functional residual capacity** (FRC). In patients with COPD, **decreased elasticity** of the alveoli (from emphysema) results in decreased collapsing pressure created by the lungs to expel air. Bronchial airway thickening and obstruction (from chronic bronchitis) further impairs lung collapse by impeding the expulsion of air. The decrease in collapsing pressure causes the chest wall to **expand outward** until the expanding pressure of the chest is balanced by the collapsing pressure of the lungs. A new pressure equilibrium is reached at a higher lung volume (ie, **higher FRC**) and, as a result, residual volume and total lung capacity are also increased.

(Choice A) The diffusing capacity of the lung for carbon monoxide (DLCO) largely depends on the thickness and total surface area of the alveolar capillary membrane. In emphysema, interalveolar wall destruction decreases the alveolar-capillary surface area, reducing DLCO. Patients with emphysema may have decreased DLCO even when there is little evidence of expiratory airflow obstruction on spirometry.

(Choice B) Expiratory airflow rates are reduced in COPD due to inflammatory and fibrotic narrowing of the bronchi (chronic bronchitis) and decreased alveolar elastic recoil (emphysema).

(Choice C) In COPD, forced vital capacity is usually decreased due to expiratory airflow obstruction limiting the total expiratory volume.

(Choice E) Emphysema causes lung elastic recoil to decrease secondary to destruction of interalveolar walls.

Educational objective:
Chronic obstructive pulmonary disease involves components of chronic bronchitis and emphysema. Bronchial airway obstruction from chronic bronchitis and decreased alveolar elasticity from emphysema result in air-trapping and lung hyperinflation. The functional residual capacity is increased, as are residual volume and total lung capacity.

References

- Why does the lung hyperinflate?

Pathophysiology	Pulmonary & Critical Care	COPD
Subject	System	Topic

A 42-year-old man comes to the emergency department due to several hours of dyspnea. He is a long-haul truck driver who became acutely short of breath during a 36-hour trip but previously had been healthy. The patient smokes a pack of cigarettes daily and drinks a 6-pack of beer on weekends. Pulmonary examination reveals vesicular breath sounds bilaterally with the overlying areas resonant to percussion. CT pulmonary angiogram shows a right lower lobe pulmonary artery occlusion consistent with pulmonary embolism but no evidence of pulmonary infarction. Which of the following is the most likely reason for the lack of lung tissue necrosis in this patient?

A. Collateral circulation

B. Decreased surfactant

C. Endothelial tissue plasminogen activator

D. Increased pulmonary venous pressure

E. Intrapulmonary shunting

Submit

A 42-year-old man comes to the emergency department due to several hours of dyspnea. He is a long-haul truck driver who became acutely short of breath during a 36-hour trip but previously had been healthy. The patient smokes a pack of cigarettes daily and drinks a 6-pack of beer on weekends. Pulmonary examination reveals vesicular breath sounds bilaterally with the overlying areas resonant to percussion. CT pulmonary angiogram shows a right lower lobe pulmonary artery occlusion consistent with pulmonary embolism but no evidence of pulmonary infarction. Which of the following is the most likely reason for the lack of lung tissue necrosis in this patient?

- ✓ A. Collateral circulation (77%)
- B. Decreased surfactant (0%)
- C. Endothelial tissue plasminogen activator (1%)
- D. Increased pulmonary venous pressure (1%)
- E. Intrapulmonary shunting (19%)

Omitted
Correct answer
A

77%
Answered correctly

03 secs
Time Spent

04/25/2020
Last Updated

Explanation

Bronchopulmonary anastomosis

Settings

1
2
3
4
5
6
7
8
9
10
11
12
13
14
15
16
17
18
19
20
21
22
23
24
25
26
27
28
29
30

Item 6 of 40
Question Id: 11774

Mark

Previous Next Full Screen Tutorial Lab Values Notes Calculator Reverse Color Text Zoom Settings

Bronchopulmonary anastomosis

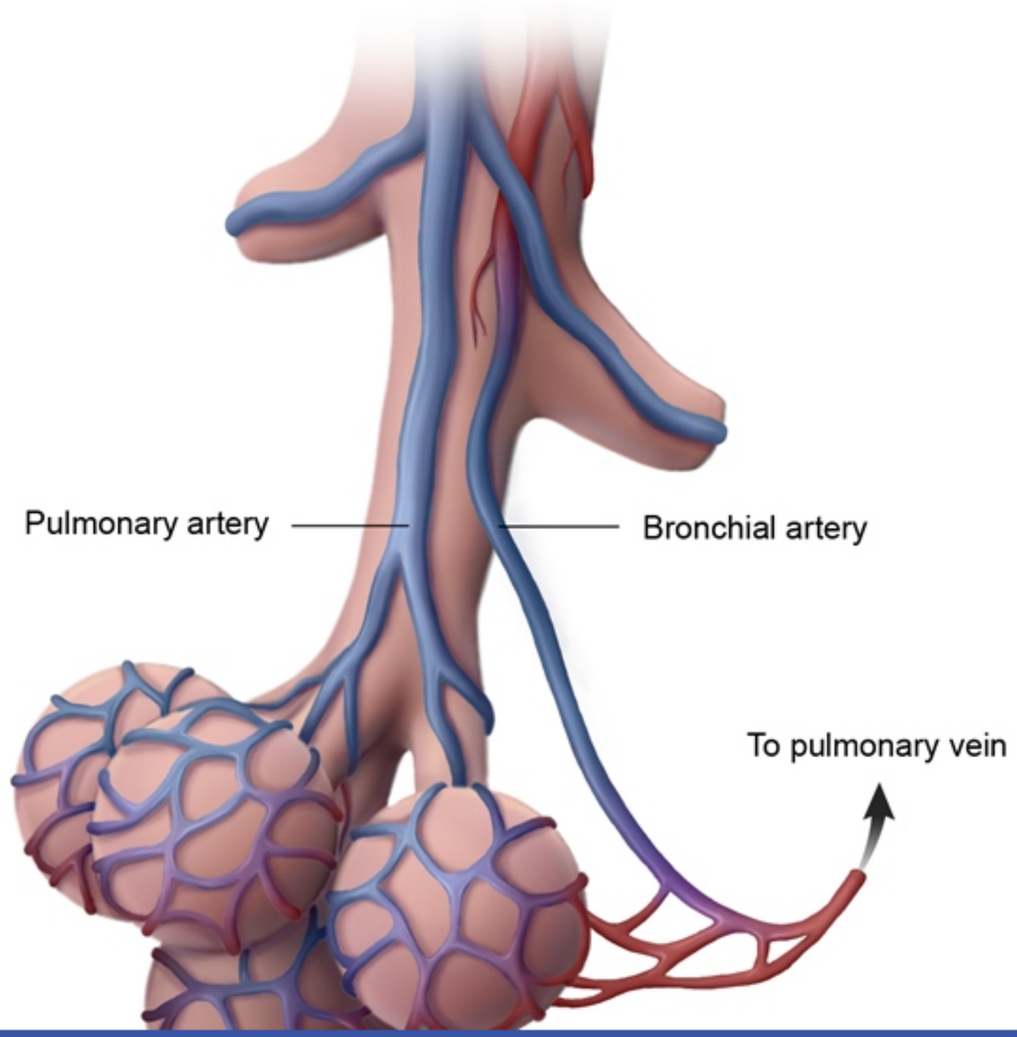

Block Time Remaining: 00:00:31
TUTOR

3 Feedback Suspend End Block

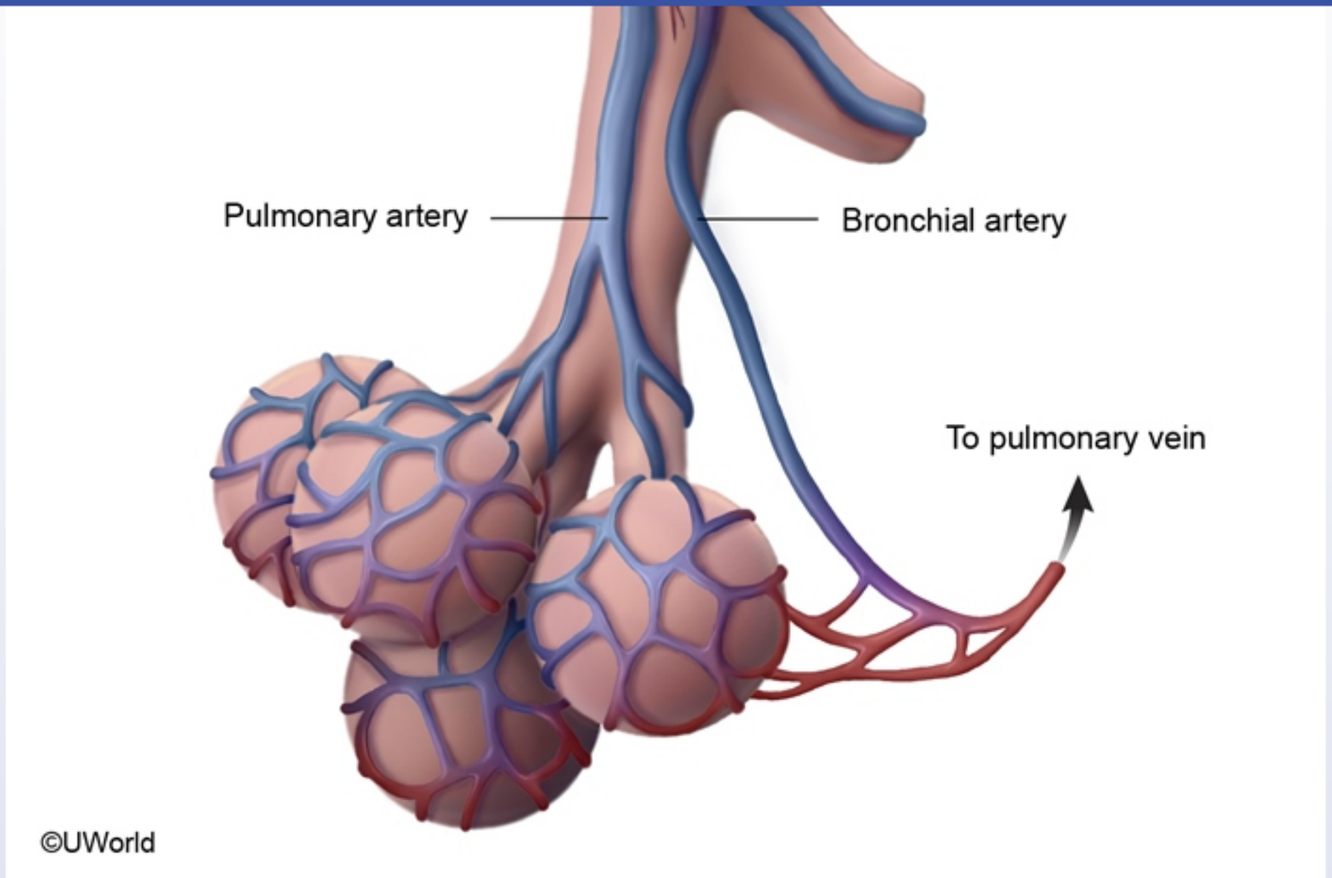

The lung is supplied by **dual circulation** from both the pulmonary arteries and bronchial arteries. This collateral circulation can help **protect against lung infarction** as a complication of **pulmonary embolism** (PE).

The pulmonary arteries are the major suppliers of blood to the lungs, providing deoxygenated blood for gas exchange; the bronchial arteries supply nutrients, remove waste from the bronchi, and provide collateral blood flow to the remainder of the lung parenchyma. When a clot occludes the pulmonary system, the bronchial system continues to supply nutrients to pulmonary tissue and can even backfill the pulmonary capillaries to partially maintain gas exchange in the area of the thromboembolism.

©UWorld

The lung is supplied by **dual circulation** from both the pulmonary arteries and bronchial arteries. This collateral circulation can help **protect against lung infarction** as a complication of **pulmonary embolism** (PE).

The pulmonary arteries are the major suppliers of blood to the lungs, providing deoxygenated blood for gas exchange; the bronchial arteries supply nutrients, remove waste from the bronchi, and provide collateral blood flow to the remainder of the lung parenchyma. When a clot occludes the pulmonary system, the bronchial system continues to supply nutrients to pulmonary tissue and can even backfill the pulmonary capillaries to partially maintain gas exchange in the area of the thromboembolism.

Distal PEs in small arteries (≤3 mm) are more likely to cause infarction as they may occlude areas distal to the pulmonary-bronchial anastomoses. When a pulmonary infarction does occur, it is typically **hemorrhagic** (red) rather than ischemic (white) due to the relatively low density of lung tissue and the dual blood supply.

(Choice B) Alveolar inflammation triggered by PE can eventually lead to decreased surfactant and some degree of atelectasis. This process can take up to 2 days to develop, and the resulting intrapulmonary shunting makes a small contribution to the hypoxemia that occurs with PE.

(Choice C) Recombinant tissue plasminogen activator (TPA) may be used to treat PE in patients who are hemodynamically unstable. However, endothelial-derived TPA is limited primarily to the bronchial circulation, and spontaneous recanalization of the pulmonary artery is a slow process.

(Choice D) PE leads to increased pulmonary arterial pressure; however, the pulmonary venous pressure is unchanged or decreased as blood flow through the proximal pulmonary circulation is obstructed. Patients with an underlying elevation in pulmonary venous pressure (eg, decompensated heart failure) may be more likely to experience lung infarction with PE due to the high pulmonary venous pressure impairing collateral flow from the bronchial circulation.

(Choice E) Intrapulmonary shunting occurs when an area of the lung is adequately perfused but poorly ventilated. PE causes intrapulmonary shunting due to redistribution of blood away from segments directly affected by the clot; the remaining accessible alveoli are unable to fully oxygenate all the blood passing through the pulmonary circulation, resulting in hypoxemia. In contrast, areas distal to the clot receive adequate ventilation but poor perfusion (ie, dead space ventilation).

Educational objective:

The lungs are supplied by dual circulation from both the pulmonary and bronchial arteries. This collateral circulation can help protect against lung

Distal PEs in small arteries (≤3 mm) are more likely to cause infarction as they may occlude areas distal to the pulmonary-bronchial anastomoses.

Exhibit Display

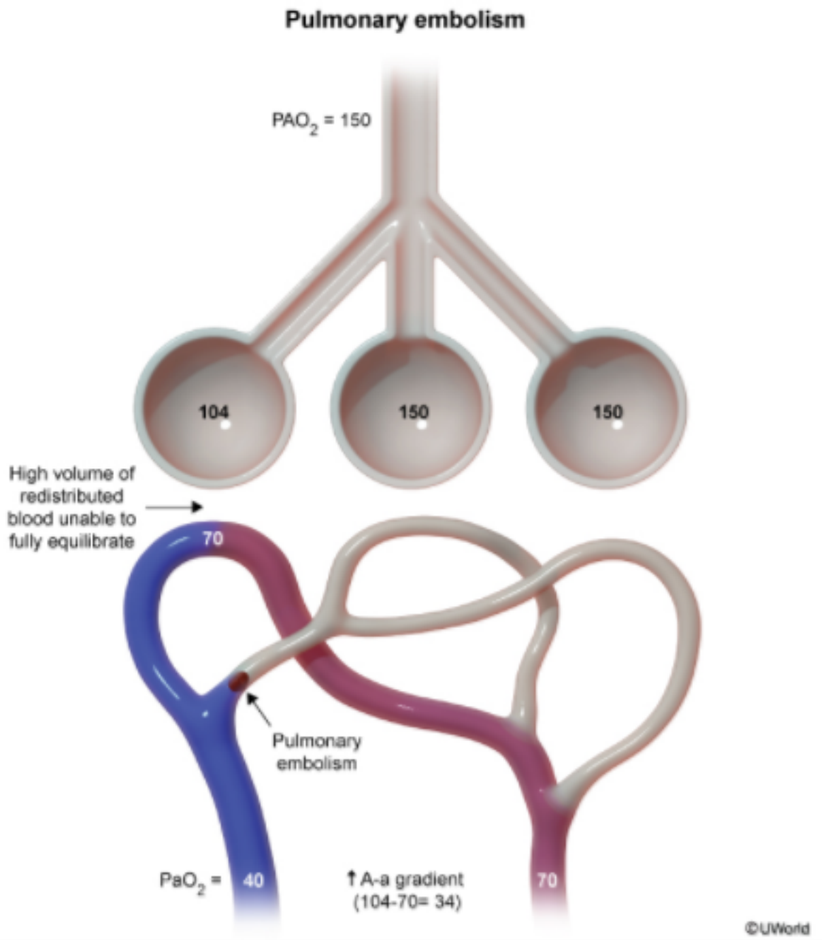

Zoom In Zoom Out Reset Add To New Card | Existing Card

Pathophysiology Pulmonary & Critical Care Pulmonary embolism

A 62-year-old man comes to the emergency department due to a 2-week history of worsening shortness of breath. The patient reports feeling dyspneic while lying flat and has been sleeping upright in his recliner. Temperature is 36.7 C (98.1 F), blood pressure is 110/70 mm Hg, pulse is 88/min, and respirations are 20/min. On physical examination, jugular venous distension is present. Heart sounds are normal. Decreased breath sounds and dullness to percussion can be heard at the bilateral bases. Pitting edema is present in the bilateral lower extremities. Chest x-ray shows cardiomegaly and bilateral pleural effusions. Serum protein is 6 g/dL and serum lactate dehydrogenase (LDH) is 60 U/L. Which of the following sets of pleural fluid findings is most likely to be seen in this patient?

	Protein (g/dL)	LDH (U/L)	Glucose (mg/dL)	Total nucleated cell count (per mm^3)
A.	2	30	90	500
B.	2	90	10	10,000
C.	2	90	90	500
D.	4	90	10	10,000
E.	4	30	90	500

Submit

A 62-year-old man comes to the emergency department due to a 2-week history of worsening shortness of breath. The patient reports feeling dyspneic while lying flat and has been sleeping upright in his recliner. Temperature is 36.7 C (98.1 F), blood pressure is 110/70 mm Hg, pulse is 88/min, and respirations are 20/min. On physical examination, jugular venous distension is present. Heart sounds are normal. Decreased breath sounds and dullness to percussion can be heard at the bilateral bases. Pitting edema is present in the bilateral lower extremities. Chest x-ray shows cardiomegaly and bilateral pleural effusions. Serum protein is 6 g/dL and serum lactate dehydrogenase (LDH) is 60 U/L. Which of the following sets of pleural fluid findings is most likely to be seen in this patient?

	Protein (g/dL)	LDH (U/L)	Glucose (mg/dL)	Total nucleated cell count (per mm^3)
✓ A. (60%)	2	30	90	500
B. (6%)	2	90	10	10,000
C. (14%)	2	90	90	500
D. (8%)	4	90	10	10,000
E. (9%)	4	30	90	500

Omitted
Correct answer

60%
Answered correctly

02 secs
Time Spent

02/09/2020
Last Updated

Exudative & transudative pleural effusions		
	Exudate	**Transudate**
Light criteria	• Pleural fluid protein/serum protein ratio >0.5 OR • Pleural fluid LDH/serum LDH ratio >0.6 OR • Pleural fluid LDH >two-thirds upper limit of normal of serum LDH	• Exudate criteria not met
Pathophysiology	• Inflammation	• Hydrostatic or oncotic pressure
Common causes	• Infection (eg, pneumonia) • Malignancy • Rheumatologic disease	• Heart failure • Cirrhosis (hepatic hydrothorax) • Nephrotic syndrome

LDH = lactate dehydrogenase.

This patient with dyspnea, orthopnea, jugular venous distension, and lower extremity swelling likely has an acute **heart failure** exacerbation. Heart failure commonly leads to **pleural effusion** due to poor forward blood flow from the left ventricle and a subsequent **increase in** pulmonary venous and **pulmonary capillary hydrostatic pressure**. Pleural effusions that result from such pressure changes are typically transudative, whereas those that result from an inflammatory increase in vascular membrane permeability are typically exudative.

Because transudative and exudative pleural effusions have differing underlying causes, they also tend to differ in chemical makeup. The Light criteria are used to differentiate the 2 types via analysis of the **total protein** and **lactate dehydrogenase** (LDH) levels. Exudative effusions have a high pleural fluid/serum ratio of these proteins due to increased capillary permeability, while **transudative effusions** are associated with a **low pleural fluid/serum ratio**.

Glucose levels and leukocyte counts can suggest the degree of inflammation in a pleural effusion. Because leukocytes metabolize glucose, highly inflammatory effusions typically have low glucose levels. Transudative effusions are not inflammatory and almost always have low nucleated cell

This patient with dyspnea, orthopnea, jugular venous distension, and lower extremity swelling likely has an acute **heart failure** exacerbation. Heart failure commonly leads to **pleural effusion** due to poor forward blood flow from the left ventricle and a subsequent **increase in** pulmonary venous and **pulmonary capillary hydrostatic pressure**. Pleural effusions that result from such pressure changes are typically transudative, whereas those that result from an inflammatory increase in vascular membrane permeability are typically exudative.

Because transudative and exudative pleural effusions have differing underlying causes, they also tend to differ in chemical makeup. The Light criteria are used to differentiate the 2 types via analysis of the **total protein** and **lactate dehydrogenase** (LDH) levels. Exudative effusions have a high pleural fluid/serum ratio of these proteins due to increased capillary permeability, while **transudative effusions** are associated with a **low pleural fluid/serum ratio**.

Glucose levels and leukocyte counts can suggest the degree of inflammation in a pleural effusion. Because leukocytes metabolize glucose, highly inflammatory effusions typically have low glucose levels. Transudative effusions are not inflammatory and almost always have low nucleated cell counts and normal (or high) glucose levels.

(Choices B and D) These effusions meet Light criteria for an exudate. The low glucose levels (<60 mg/dL) suggest consumption of glucose by an abundance of metabolically active cells, as can occur with highly inflammatory exudative effusions resulting from bacterial infection, malignancy, or rheumatologic disease.

(Choices C and E) These effusions meet Light criteria for an exudate. The normal glucose levels and low cell counts suggest a relatively low-inflammation exudative effusion such as an uncomplicated parapneumonic effusion or effusion due to pulmonary embolism.

Educational objective:
Transudative pleural effusions result from increased intracapillary pressure (eg, heart failure) and exudative effusions develop from inflammatory disruption of the vascular membrane. Transudative pleural effusions have low fluid/serum ratios of total protein and lactate dehydrogenase and low absolute levels of lactate dehydrogenase compared to exudative effusions.

Pathophysiology	Pulmonary & Critical Care	Pleural effusion
Subject	System	Topic

Copyright © UWorld. All rights reserved.

A 34-year-old woman comes to the office due to progressive exertional dyspnea for the past 6 months. She has no chest pain, lightheadedness, or syncope. Medical history is unremarkable and the patient takes no medications. She does not use tobacco, alcohol, or illicit drugs. The patient's mother died of pulmonary arterial hypertension at age 32. Blood pressure is 125/74 mm Hg and pulse is 75/min. BMI is 23 kg/m^2. On physical examination, breath sounds are clear without wheezes or crackles. There is a loud S2 at the left upper sternal border. Chest x-ray reveals clear lungs. ECG shows right axis deviation. If this patient's condition is inherited, which of the following is the most likely direct cause of her disease?

- A. Elevated left atrial pressure
- B. Hypoxic vasoconstriction
- C. Right ventricular hypertrophy
- D. Thrombotic occlusion of pulmonary arteries
- E. Vascular smooth muscle proliferation

Submit

A 34-year-old woman comes to the office due to progressive exertional dyspnea for the past 6 months. She has no chest pain, lightheadedness, or syncope. Medical history is unremarkable and the patient takes no medications. She does not use tobacco, alcohol, or illicit drugs. The patient's mother died of pulmonary arterial hypertension at age 32. Blood pressure is 125/74 mm Hg and pulse is 75/min. BMI is 23 kg/m^2. On physical examination, breath sounds are clear without wheezes or crackles. There is a loud S2 at the left upper sternal border. Chest x-ray reveals clear lungs. ECG shows right axis deviation. If this patient's condition is inherited, which of the following is the most likely direct cause of her disease?

- A. Elevated left atrial pressure (5%)
- B. Hypoxic vasoconstriction (4%)
- C. Right ventricular hypertrophy (20%)
- D. Thrombotic occlusion of pulmonary arteries (3%)
- ✓ E. Vascular smooth muscle proliferation (65%)

Omitted
Correct answer
E

65%
Answered correctly

02 secs
Time Spent

03/09/2020
Last Updated

Explanation

Pathogenesis of pulmonary arterial hypertension

Settings

1
2
3
4
5
6
7
8
9
10
11
12
13
14
15
16
17
18
19
20
21
22
23
24
25
26
27
28
29
30

Item 8 of 40
Question Id: 530

Mark | Previous | Next | Full Screen | Tutorial | Lab Values | Notes | Calculator | Reverse Color | Text Zoom | Settings

Pathogenesis of pulmonary arterial hypertension

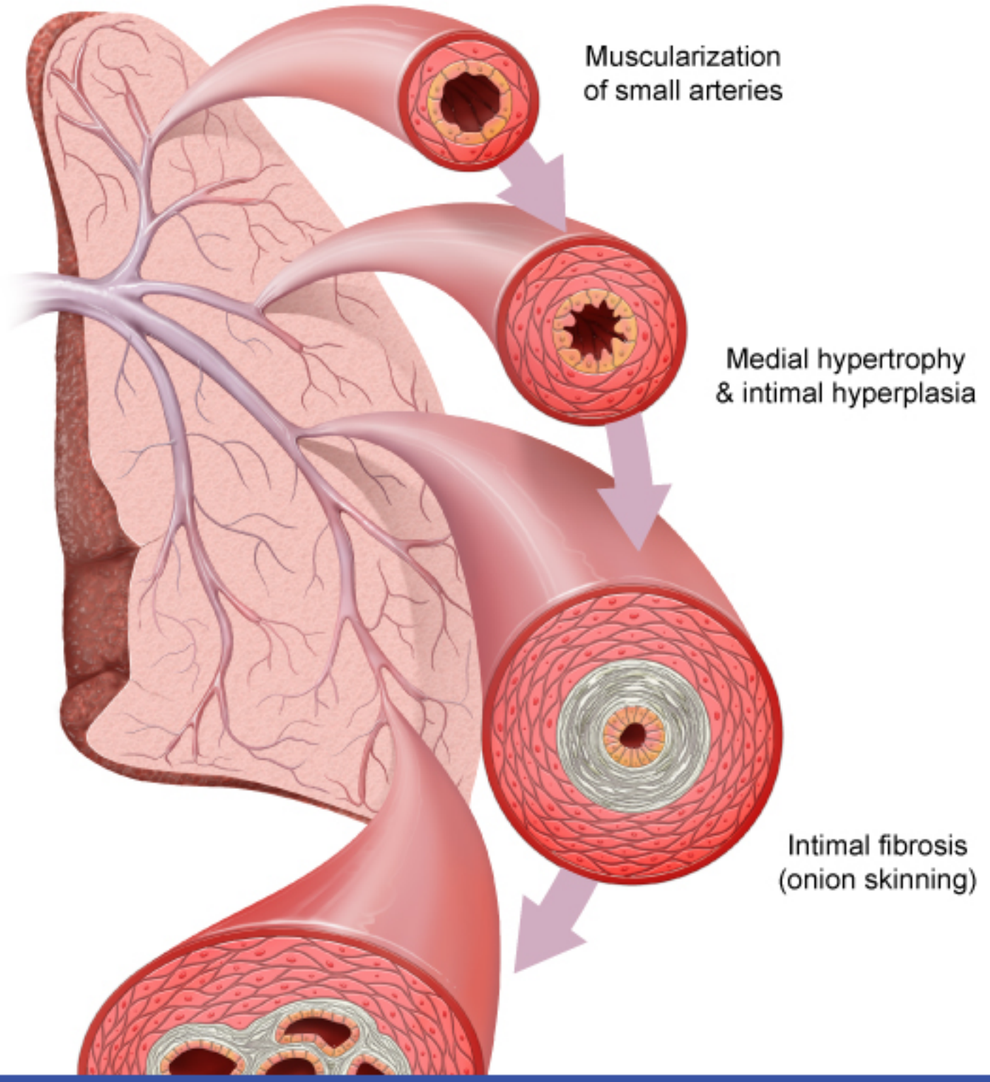

Block Time Remaining: 00:00:35
TUTOR

3 | Feedback | Suspend | End Block

1 2 3 4 5 6 7 8 9 10 11 12 13 14 15 16 17 18 19 20 21 22 23 24 25 26 27 28 29 30

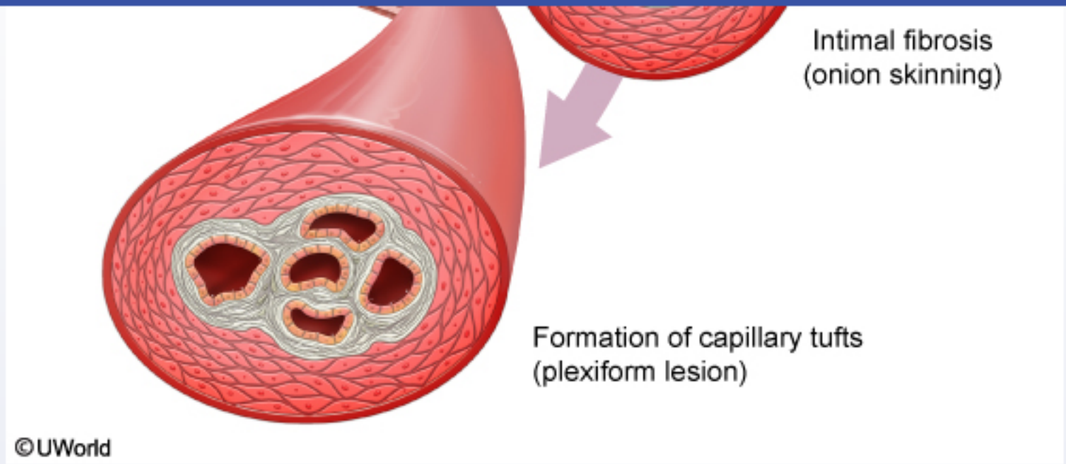

This patient's presentation and family history are suggestive of **pulmonary arterial hypertension** (PAH). Hereditary PAH is most often due to an inactivating mutation in ***BMPR2***, which is transmitted in an autosomal dominant manner with variable penetrance. Patients with this mutation have a predisposition for dysfunctional endothelial and **smooth muscle cell proliferation**. An insult (eg, infection, drugs) is thought to then activate the disease process, which involves increased levels of vasoconstrictive, proliferative mediators (eg, endothelin) and decreased levels of vasodilative, antiproliferative mediators (eg, nitric oxide, prostacyclin). The end result is vasoconstriction with vascular smooth muscle proliferation, intimal thickening and fibrosis, increased pulmonary vascular resistance, and progressive pulmonary hypertension.

Increased pulmonary artery pressure can cause dyspnea and fatigue and can often be detected as a **loud pulmonic component of S2**. Significant pulmonary hypertension leads to compensatory right ventricular hypertrophy **(Choice C)**, which may cause right axis deviation on ECG. Right-sided heart failure can eventually occur, evidenced by elevated jugular venous pressure, hepatic congestion, and peripheral edema. The lungs remain clear in PAH as the lung parenchyma is unaffected.

(Choice A) Elevated left atrial pressure is indicative of heart failure, most commonly due to left ventricular dysfunction. The elevated pressure transmits back to the pulmonary venous system and can lead to pulmonary hypertension; however, evidence of pulmonary edema (eg, crackles, pulmonary congestion on chest x-ray) would be expected.

(Choice B) Excessive hypoxic vasoconstriction of the pulmonary arteries can lead to pulmonary hypertension in patients with severe hypoxic lung disease, including chronic obstructive pulmonary disease, interstitial lung disease, and obesity hypoventilation syndrome. However, this patient's

thickening and fibrosis, increased pulmonary vascular resistance, and progressive pulmonary hypertension.

Increased pulmonary artery pressure can cause dyspnea and fatigue and can often be detected as a **loud pulmonic component of S2**. Significant pulmonary hypertension leads to compensatory right ventricular hypertrophy **(Choice C)**, which may cause right axis deviation on ECG. Right-sided heart failure can eventually occur, evidenced by elevated jugular venous pressure, hepatic congestion, and peripheral edema. The lungs remain clear in PAH as the lung parenchyma is unaffected.

(Choice A) Elevated left atrial pressure is indicative of heart failure, most commonly due to left ventricular dysfunction. The elevated pressure transmits back to the pulmonary venous system and can lead to pulmonary hypertension; however, evidence of pulmonary edema (eg, crackles, pulmonary congestion on chest x-ray) would be expected.

(Choice B) Excessive hypoxic vasoconstriction of the pulmonary arteries can lead to pulmonary hypertension in patients with severe hypoxic lung disease, including chronic obstructive pulmonary disease, interstitial lung disease, and obesity hypoventilation syndrome. However, this patient's normal chest x-ray and BMI rule out these disorders.

(Choice D) Chronic pulmonary arterial thromboembolism decreases the cross-sectional area of the pulmonary vasculature and can lead to pulmonary hypertension. However, PAH is more likely in this patient with a positive family history and no evidence of venous thromboembolism.

Educational objective:
Hereditary pulmonary arterial hypertension develops in 2 steps. An abnormal *BMPR2* gene predisposes affected individuals to excessive endothelial and smooth muscle cell proliferation. An insult (eg, infection, drugs) is thought to then activate the disease process, resulting in vascular remodeling, increased pulmonary vascular resistance, and progressive pulmonary hypertension.

References

- Pulmonary arterial hypertension.

Pathophysiology	Pulmonary & Critical Care	Pulmonary Arterial Hypertension
Subject	System	Topic

Copyright © UWorld. All rights reserved.

A 28-year-old man is found unresponsive by his roommate and is brought to the emergency department. He has a history of injection drug use. On physical examination, the patient is obtunded and hypopneic. The pupils are pinpoint. Lung auscultation reveals decreased breath sounds bilaterally. Endotracheal intubation is planned for airway protection and arterial blood gas analysis is performed prior to the procedure while the patient is breathing room air. This patient's current acid-base status is best represented by which of the following points on the below graph?

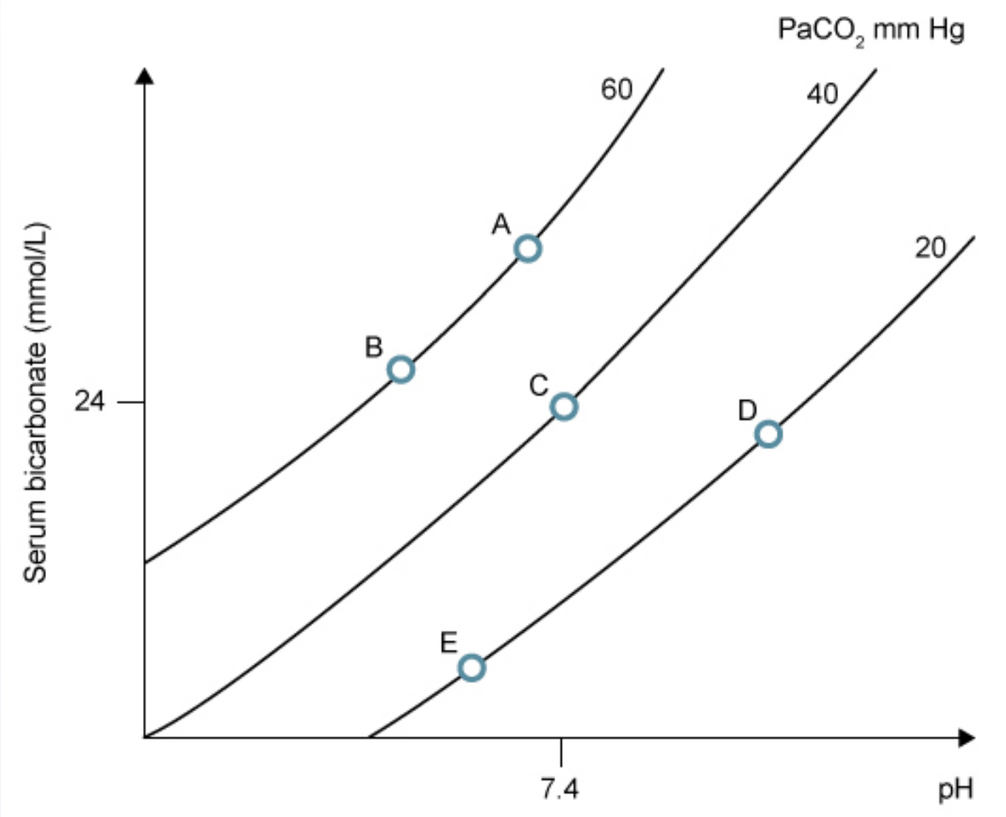

A. A

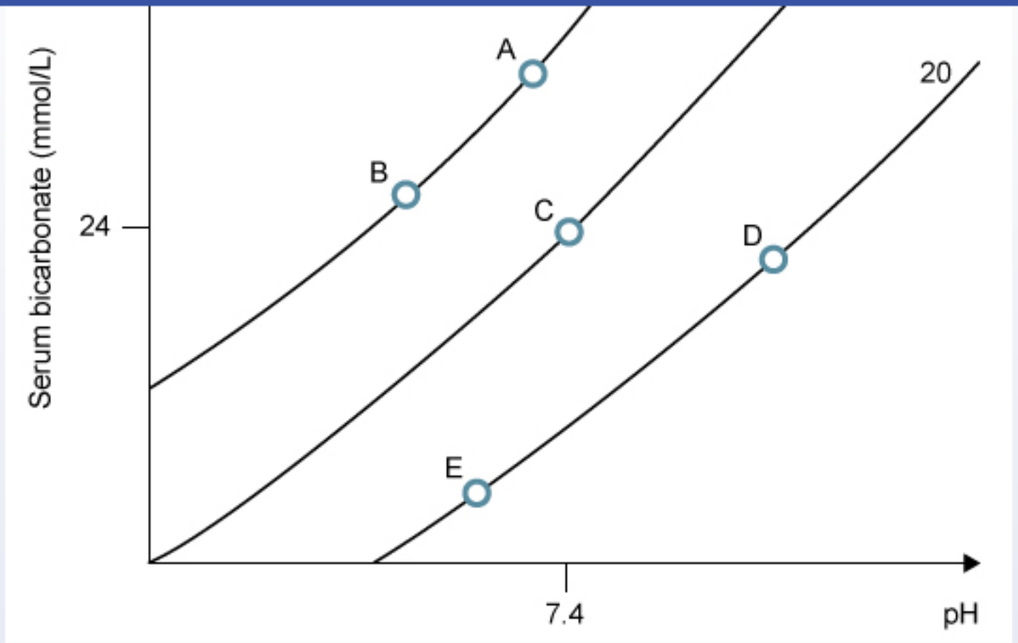

A. A
B. B
C. C
D. D
E. E

Submit

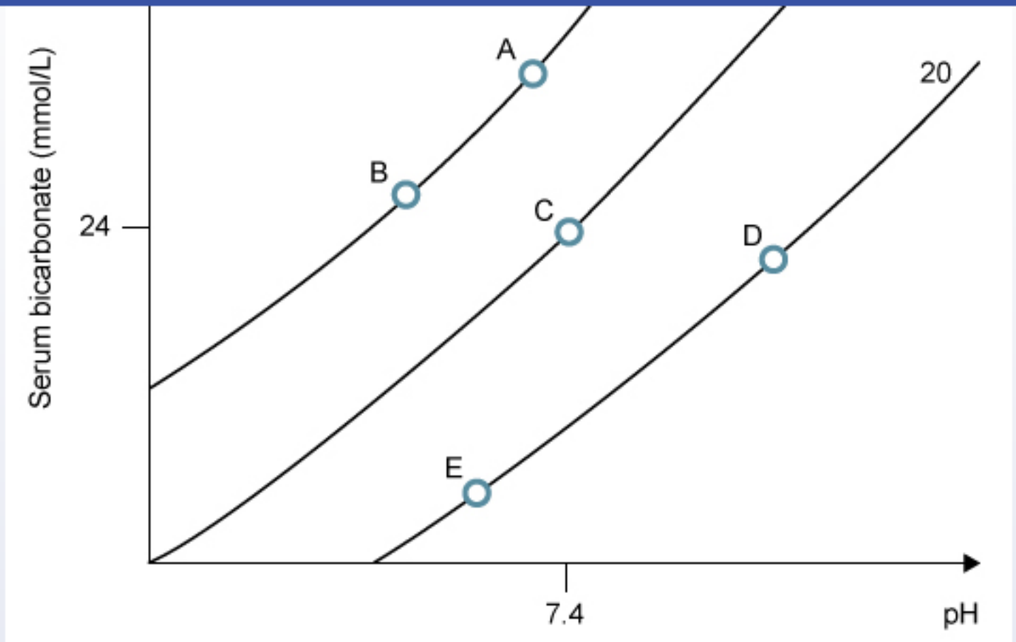

A. A (12%)

✓ B. B (77%)

C. C (0%)

D. D (3%)

E. E (6%)

Omitted
Correct answer

77%
Answered correctly

08 secs
Time Spent

03/31/2020
Last Updated

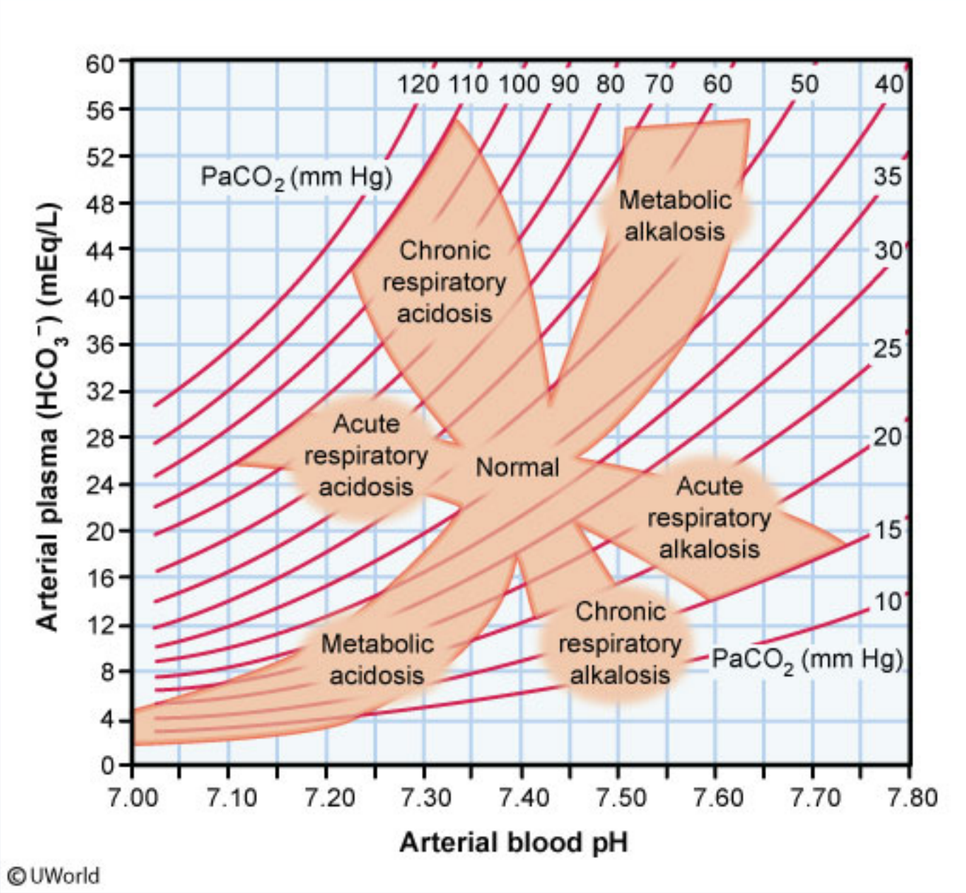

This patient's altered consciousness, pinpoint pupils, decreased breath sounds, and history of intravenous drug abuse strongly suggest **acute opioid overdose**. In addition to causing sedation, opioids cause **respiratory depression** by suppressing central respiratory drive in the medulla. The resulting **hypoventilation** leads to CO_2 retention and **acute respiratory acidosis**, characterized by **low pH** and **high $PaCO_2$**. To compensate for respiratory acidosis, the kidneys retain additional bicarbonate; however, metabolic renal compensation for an acid-base disturbance is a relatively slow process (taking place over several days) and is minimally evident in the acute setting.

This patient's altered consciousness, pinpoint pupils, decreased breath sounds, and history of intravenous drug abuse strongly suggest **acute opioid overdose**. In addition to causing sedation, opioids cause **respiratory depression** by suppressing central respiratory drive in the medulla. The resulting **hypoventilation** leads to CO_2 retention and **acute respiratory acidosis**, characterized by **low pH** and **high $PaCO_2$**. To compensate for respiratory acidosis, the kidneys retain additional bicarbonate; however, metabolic renal compensation for an acid-base disturbance is a relatively slow process (taking place over several days) and is minimally evident in the acute setting.

(Choice A) A high $PaCO_2$ with high serum bicarbonate and near normal pH is consistent with chronic respiratory acidosis with a compensatory metabolic alkalosis, such as occurs in severe chronic obstructive pulmonary disease. Although acute opioid overdose is expected to cause a rapid increase in $PaCO_2$, serum bicarbonate is near normal because there has not been time for metabolic compensation.

(Choice C) Normal acid-base values include pH 7.4, $PaCO_2$ 40 mm Hg, and serum bicarbonate 24 mEq/L. Significant deviation from these values represents an acid-base disturbance.

(Choice D) A high pH with low $PaCO_2$ and slightly low serum bicarbonate is consistent with acute respiratory alkalosis, such as occurs with the hyperventilation seen in acute pulmonary embolism or acute anxiety. Serum bicarbonate is only slightly low because the kidneys have had little time to compensate by increasing bicarbonate excretion.

(Choice E) A low pH with low serum bicarbonate and low $PaCO_2$ is consistent with acute metabolic acidosis, such as occurs with lactic acidosis in sepsis. The lungs quickly compensate for the acidemia with hyperventilation to increase exhalation of CO_2 and help normalize pH. Severe metabolic acidosis can lead to respiratory failure if the lungs are unable to keep up with the need to exhale CO_2.

Educational objective:
Acute opioid overdose is characterized by altered level of consciousness, pinpoint pupils, and central respiratory depression. Patients are expected to have acute respiratory acidosis (low pH, high $PaCO_2$) due to hypoventilation. Serum bicarbonate is typically near normal as there is not time for metabolic compensation in the acute setting.

Pathophysiology	Pulmonary & Critical Care	Opioids
Subject	System	Topic

Copyright © UWorld. All rights reserved.

This patient's altered consciousness, pinpoint pupils, decreased breath sounds, and history of intravenous drug abuse strongly suggest **acute**

Exhibit Display

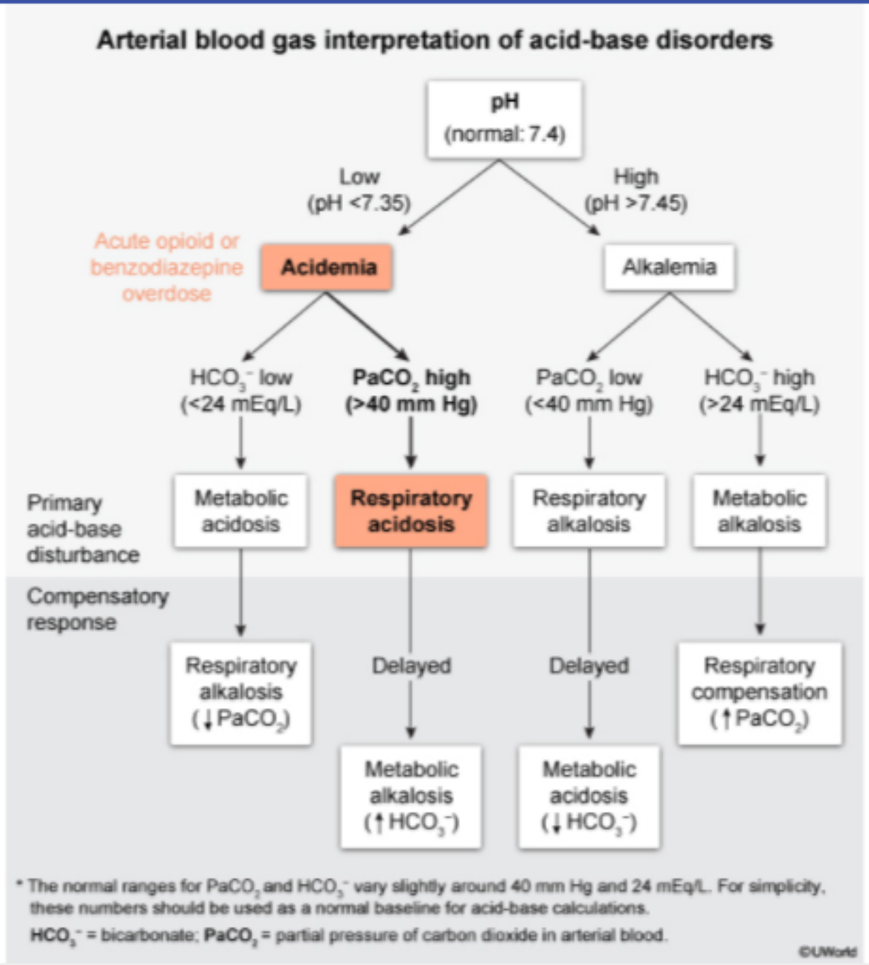

Zoom In | Zoom Out | Reset | Add To New Card | Existing Card

Copyright © UWorld. All rights reserved.

A 55-year-old man comes to the emergency department due to sudden-onset dyspnea. Medical history is significant for hypertension, hyperlipidemia, type 2 diabetes mellitus, and chronic kidney disease. The patient takes multiple medications and has no drug allergies. He works for an international bank and returned from a business trip in Australia a day ago. Blood pressure is 110/70 mm Hg and pulse is 110/min. Physical examination shows a moderately overweight man with tachypnea. The lungs are clear on auscultation. ECG shows sinus tachycardia. Ventilation/perfusion scanning is ordered. Which of the following findings would help confirm the suspected diagnosis in this patient?

- A. Absence of ventilation and perfusion abnormalities
- B. An area showing both ventilation and perfusion defects
- C. A perfusion defect without an associated ventilation defect
- D. A ventilation defect without an associated perfusion defect
- E. Several small areas of matched perfusion and ventilation defects

Submit

A 55-year-old man comes to the emergency department due to sudden-onset dyspnea. Medical history is significant for hypertension, hyperlipidemia, type 2 diabetes mellitus, and chronic kidney disease. The patient takes multiple medications and has no drug allergies. He works for an international bank and returned from a business trip in Australia a day ago. Blood pressure is 110/70 mm Hg and pulse is 110/min. Physical examination shows a moderately overweight man with tachypnea. The lungs are clear on auscultation. ECG shows sinus tachycardia. Ventilation/perfusion scanning is ordered. Which of the following findings would help confirm the suspected diagnosis in this patient?

- A. Absence of ventilation and perfusion abnormalities (1%)
- B. An area showing both ventilation and perfusion defects (5%)
- ✓ C. A perfusion defect without an associated ventilation defect (86%)
- D. A ventilation defect without an associated perfusion defect (4%)
- E. Several small areas of matched perfusion and ventilation defects (1%)

Omitted
Correct answer
C

86%
Answered correctly

02 secs
Time Spent

04/20/2020
Last Updated

Explanation

Perfusion defect without ventilation defect

Perfusion defect without ventilation defect

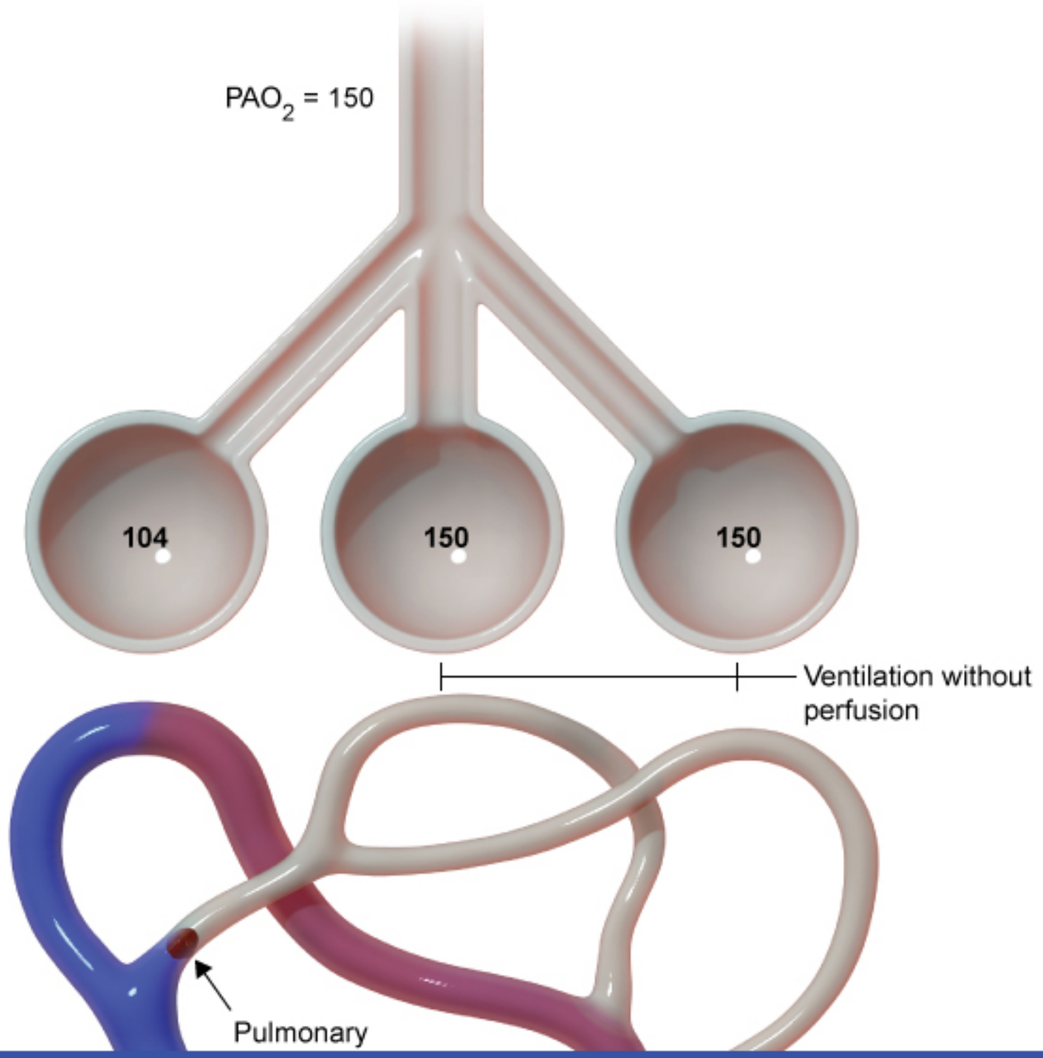

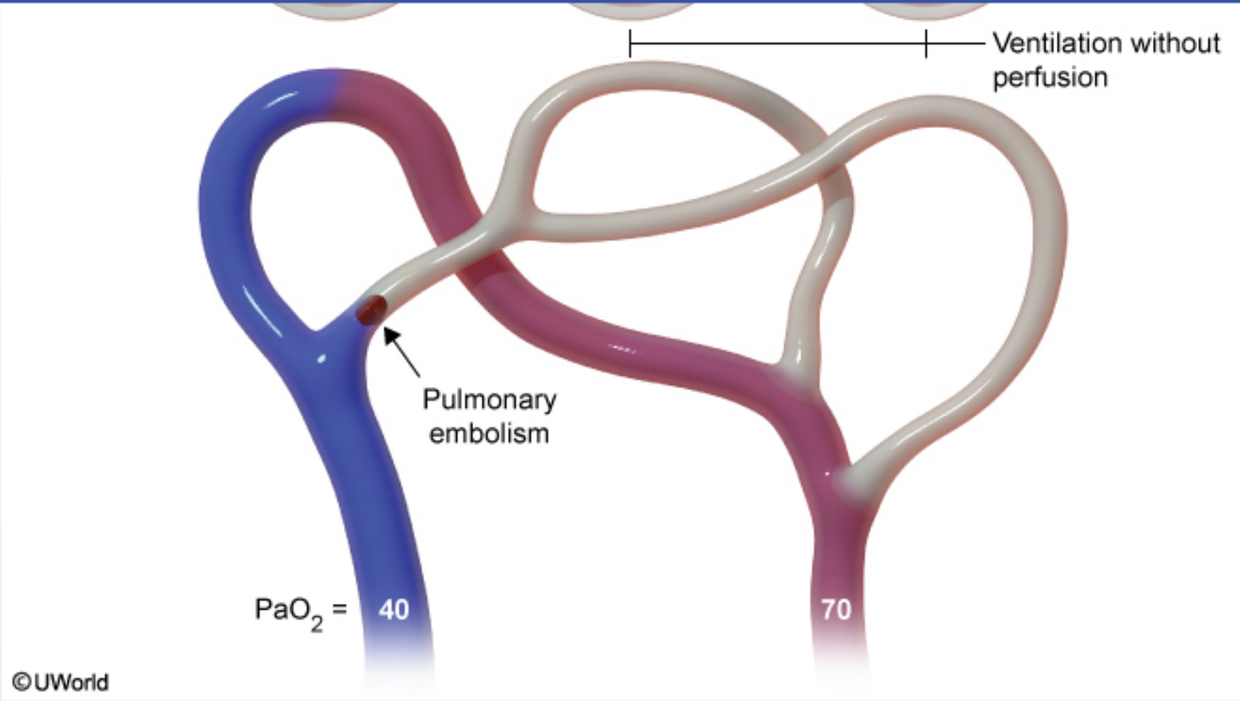

Pulmonary embolism (PE) should be suspected in this patient with recent extended travel (prolonged immobilization) who now has acute-onset dyspnea and tachypnea, normal lung examination, and sinus tachycardia on ECG. In most patients, **CT angiography**, which requires intravenous contrast administration, is the diagnostic test of choice. However, the contrast used in CT studies should be avoided in patients with chronic kidney disease due to the increased risk of contrast-induced nephropathy; in such patients, a **ventilation/perfusion (V/Q) scan** is the preferred diagnostic study.

A V/Q scan is a nuclear medicine study that uses a radioactive tracer placed in both inhaled gas and the bloodstream to visualize areas of ventilation and perfusion in the lung. In patients with PE, ventilation is preserved but the embolus prevents adequate blood perfusion to the affected areas of the lung. Therefore, the most definitive diagnostic finding for PE on V/Q scan is a large area showing a **perfusion defect without ventilation defect** (mismatched perfusion defect).

(Choice A) The absence of perfusion abnormalities is a useful finding on V/Q scan, as it likely rules out significant PE

Pulmonary embolism (PE) should be suspected in this patient with recent extended travel (prolonged immobilization) who now has acute-onset dyspnea and tachypnea, normal lung examination, and sinus tachycardia on ECG. In most patients, **CT angiography**, which requires intravenous contrast administration, is the diagnostic test of choice. However, the contrast used in CT studies should be avoided in patients with chronic kidney disease due to the increased risk of contrast-induced nephropathy; in such patients, a **ventilation/perfusion (V/Q) scan** is the preferred diagnostic study.

A V/Q scan is a nuclear medicine study that uses a radioactive tracer placed in both inhaled gas and the bloodstream to visualize areas of ventilation and perfusion in the lung. In patients with PE, ventilation is preserved but the embolus prevents adequate blood perfusion to the affected areas of the lung. Therefore, the most definitive diagnostic finding for PE on V/Q scan is a large area showing a **perfusion defect without ventilation defect** (mismatched perfusion defect).

(Choice A) The absence of perfusion abnormalities is a useful finding on V/Q scan, as it likely rules out significant PE.

(Choices B and E) Matched ventilation and perfusion defects may result from chronic lung abnormalities (eg, airway inflammation or obstruction, atelectasis) that lead to localized areas of poor ventilation with corresponding hypoxic vasoconstriction, or they may represent a PE that happens to be in an area of poor ventilation. These results are often inconclusive and necessitate additional testing to confirm or rule out PE.

(Choice D) An area of ventilation defect without perfusion defect is suggestive of conditions that lead to acute alveolar filling (eg, pneumonia, pulmonary edema).

Educational objective:
Ventilation/perfusion scanning can be useful for diagnosing pulmonary embolism. A large perfusion defect without ventilation defect is the characteristic positive test result.

References

- Value of the ventilation/perfusion scan in acute pulmonary embolism: results of the prospective investigation of pulmonary embolism diagnosis (PIOPED).
- Current status of ventilation-perfusion scintigraphy for suspected pulmonary embolism.

Settings

1 2 3 4 5 6 7 8 9 10 11 12 13 14 15 16 17 18 19 20 21 22 23 24 25 26 27 28 29 30

Item 10 of 40
Question Id: 12184

Mark | Previous | Next | Full Screen | Tutorial | Lab Values | Notes | Calculator | Reverse Color | Text Zoom | Settings

Exhibit Display

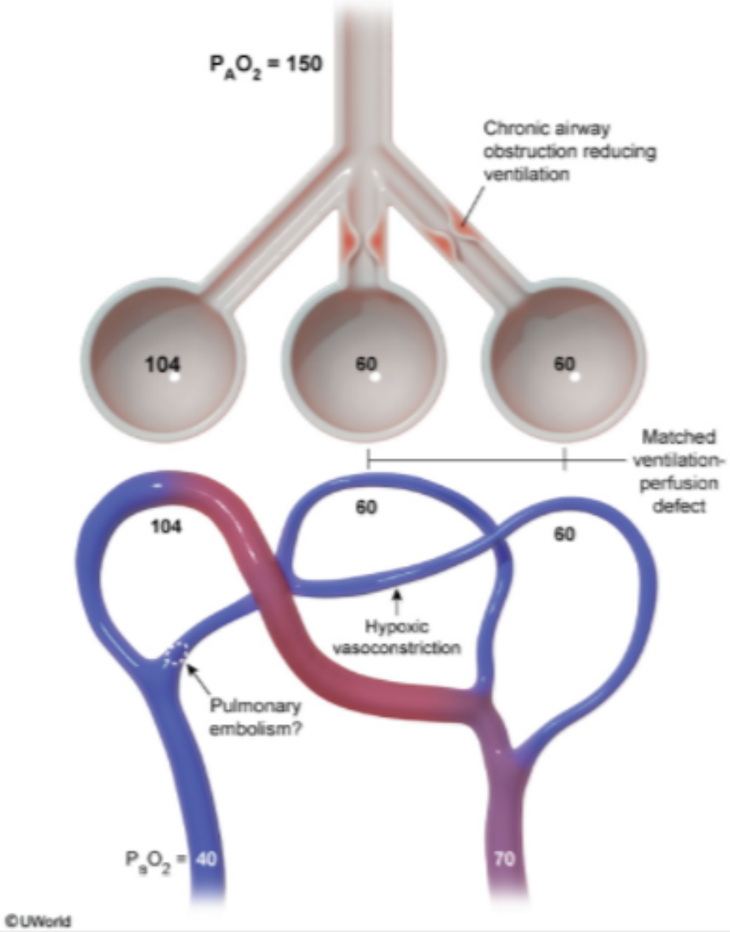

Zoom In | Zoom Out | Reset | Add To New Card | Existing Card

Block Time Remaining: 00:00:45
TUTOR

5 | Feedback | Suspend | End Block

Settings

1 2 3 4 5 6 7 8 9 10 11 12 13 14 15 16 17 18 19 20 21 22 23 24 25 26 27 28 29 30

Item 10 of 40
Question Id: 12184

Mark | Previous | Next | Full Screen | Tutorial | Lab Values | Notes | Calculator | Reverse Color | Text Zoom | Settings

Exhibit Display

Ventilation defect without perfusion defect

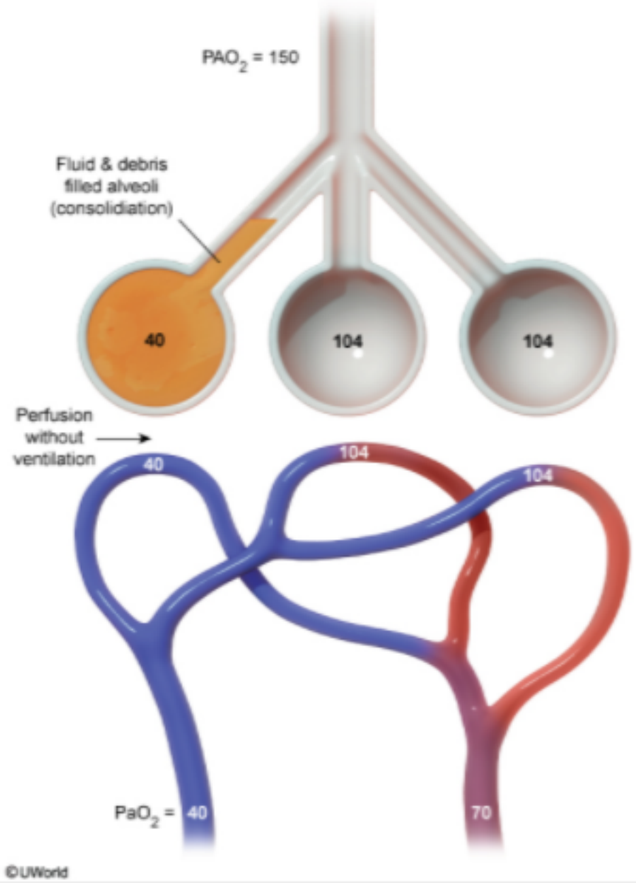

Zoom In | Zoom Out | Reset | Add To New Card | Existing Card

Block Time Remaining: 00:00:45
TUTOR

5 | Feedback | Suspend | End Block

A 63-year-old man comes to the emergency department due to a 1-week history of progressively worsening shortness of breath and cough. The shortness of breath is exacerbated when the patient lies flat in bed; he has to prop himself up with 3 pillows to sleep well at night. He was treated for a myocardial infarction 2 weeks ago and had 2 stents placed in the left anterior descending artery. The patient's other medical conditions include long-standing hypertension and type 2 diabetes mellitus. Blood pressure is 120/80 mm Hg, pulse is 92/min, and respirations are 22/min. Pulse oximetry is 89% on room air. Physical examination reveals bilateral crackles at the lung bases and an S3. Which of the following is most likely present in this patient?

A. Decreased alveolar surface tension

B. Decreased lung compliance

C. Increased dead space ventilation

D. Increased functional residual capacity

E. Left-to-right cardiac shunting

Submit

1 2 3 4 5 6 7 8 9 10 11 12 13 14 15 16 17 18 19 20 21 22 23 24 25 26 27 28 29 30

A 63-year-old man comes to the emergency department due to a 1-week history of progressively worsening shortness of breath and cough. The shortness of breath is exacerbated when the patient lies flat in bed; he has to prop himself up with 3 pillows to sleep well at night. He was treated for a myocardial infarction 2 weeks ago and had 2 stents placed in the left anterior descending artery. The patient's other medical conditions include long-standing hypertension and type 2 diabetes mellitus. Blood pressure is 120/80 mm Hg, pulse is 92/min, and respirations are 22/min. Pulse oximetry is 89% on room air. Physical examination reveals bilateral crackles at the lung bases and an S3. Which of the following is most likely present in this patient?

A. Decreased alveolar surface tension (12%)

✓ B. Decreased lung compliance (38%)

C. Increased dead space ventilation (31%)

D. Increased functional residual capacity (6%)

E. Left-to-right cardiac shunting (11%)

Omitted
Correct answer
B

38%
Answered correctly

02 secs
Time Spent

03/22/2020
Last Updated

Explanation

This patient's dyspnea, orthopnea, bibasilar crackles, and S3 suggest **left-sided heart failure** due to recent myocardial infarction (MI). Atherosclerotic plaque rupture in the left anterior descending or left circumflex artery can infarct large areas of the left ventricular myocardium, leading to decreased contractility and reduced cardiac output. This can result in **elevation of end-diastolic pressure** that impairs diastolic return from the pulmonary veins, leading to increased hydrostatic pressure in the pulmonary capillaries with transudation of fluid into the lung.

This patient's dyspnea, orthopnea, bibasilar crackles, and S3 suggest **left-sided heart failure** due to recent myocardial infarction (MI). Atherosclerotic plaque rupture in the left anterior descending or left circumflex artery can infarct large areas of the left ventricular myocardium, leading to decreased contractility and reduced cardiac output. This can result in **elevation of end-diastolic pressure** that impairs diastolic return from the pulmonary veins, leading to increased hydrostatic pressure in the pulmonary capillaries with transudation of fluid into the lung parenchyma **(pulmonary edema)**.

Pulmonary edema in the alveoli impairs ventilation and causes intrapulmonary shunting. In addition, edema in the lung interstitium makes the lungs heavy and stiff, restricting pulmonary expansion during inspiration. This **decreased lung compliance** can mimic that seen with other causes of restrictive lung physiology (eg, interstitial lung disease).

(Choice A) Surfactant decreases the surface tension of the fluid layer that lines alveolar cells, helping prevent alveolar collapse. Pulmonary edema dilutes pulmonary surfactant, increasing both alveolar surface tension and the tendency for alveolar collapse.

(Choice C) Ventilation-perfusion (V/Q) mismatch exists on a spectrum with intrapulmonary shunting (perfusion without ventilation) and dead space ventilation (ventilation without perfusion) on either end. Pulmonary edema causes V/Q mismatch via increased intrapulmonary shunting with a corresponding decrease in dead space ventilation. V/Q mismatch via increased dead space ventilation is seen with pulmonary embolism.

(Choice D) Functional residual capacity is the volume of air in the lungs at the end of normal expiration. It is increased in conditions with increased lung compliance (eg, chronic obstructive pulmonary disease) and decreased in conditions such as pulmonary edema that reduce lung compliance.

(Choice E) Interventricular septal rupture is a mechanical complication of MI that causes left-to-right cardiac shunting. However, this complication usually occurs within 3-5 days following MI and precipitates a dramatic and acute, rather than gradual, presentation of heart failure.

Educational objective:
Left-sided heart failure is common following myocardial infarction affecting the left ventricle. The resulting accumulation of edema in the pulmonary interstitium makes the lungs heavy and stiff, restricting inspiratory expansion and decreasing lung compliance.

Pathophysiology | Pulmonary & Critical Care | Acute heart failure

leading to decreased contractility and reduced cardiac output. This can result in **elevation of end-diastolic pressure** that impairs diastolic return from the pulmonary veins, leading to increased hydrostatic pressure in the pulmonary capillaries with transudation of fluid into the lung parenchyma **(pulmonary edema)**.

Pulmonary edema in the alveoli impairs ventilation and causes intrapulmonary shunting. In addition, edema in the lung interstitium makes the lungs heavy and stiff, restricting pulmonary expansion during inspiration. This **decreased lung compliance** can mimic that seen with other causes of restrictive lung physiology (eg, interstitial lung disease).

(Choice A) Surfactant decreases the surface tension of the fluid layer that lines alveolar cells, helping prevent alveolar collapse. Pulmonary edema dilutes pulmonary surfactant, increasing both alveolar surface tension and the tendency for alveolar collapse.

(Choice C) Ventilation-perfusion (V/Q) mismatch exists on a spectrum with intrapulmonary shunting (perfusion without ventilation) and dead space ventilation (ventilation without perfusion) on either end. Pulmonary edema causes V/Q mismatch via increased intrapulmonary shunting with a corresponding decrease in dead space ventilation. V/Q mismatch via increased dead space ventilation is seen with pulmonary embolism.

(Choice D) Functional residual capacity is the volume of air in the lungs at the end of normal expiration. It is increased in conditions with increased lung compliance (eg, chronic obstructive pulmonary disease) and decreased in conditions such as pulmonary edema that reduce lung compliance.

(Choice E) Interventricular septal rupture is a mechanical complication of MI that causes left-to-right cardiac shunting. However, this complication usually occurs within 3-5 days following MI and precipitates a dramatic and acute, rather than gradual, presentation of heart failure.

Educational objective:
Left-sided heart failure is common following myocardial infarction affecting the left ventricle. The resulting accumulation of edema in the pulmonary interstitium makes the lungs heavy and stiff, restricting inspiratory expansion and decreasing lung compliance.

Pathophysiology	Pulmonary & Critical Care	Acute heart failure
Subject	System	Topic

Copyright © UWorld. All rights reserved.

A research study is conducted to evaluate the effects of various serum proteins in health and disease states. Healthy volunteers and patients with various medical conditions are recruited. In an experiment, purified insoluble elastin is exposed to stimulated neutrophils, which results in the degradation of the elastin molecules into smaller peptides. This process can be inhibited by adding serum from healthy volunteers but not from a specific patient population. Which of the following is the strongest recommendation for patients in this specific population?

- A. Avoidance of competitive sports participation
- B. Avoidance of immunosuppressive agents
- C. Avoidance of second-hand smoke
- D. Periodic aortic diameter monitoring
- E. Regular bone density measurement
- F. Regular ophthalmologic examinations

Submit

A research study is conducted to evaluate the effects of various serum proteins in health and disease states. Healthy volunteers and patients with various medical conditions are recruited. In an experiment, purified insoluble elastin is exposed to stimulated neutrophils, which results in the degradation of the elastin molecules into smaller peptides. This process can be inhibited by adding serum from healthy volunteers but not from a specific patient population. Which of the following is the strongest recommendation for patients in this specific population?

- A. Avoidance of competitive sports participation (4%)
- B. Avoidance of immunosuppressive agents (4%)
- ✓ C. Avoidance of second-hand smoke (76%)
- D. Periodic aortic diameter monitoring (11%)
- E. Regular bone density measurement (1%)
- F. Regular ophthalmologic examinations (2%)

Omitted
Correct answer
C

76%
Answered correctly

02 secs
Time Spent

01/24/2020
Last Updated

Explanation

Neutrophil elastase is released by both neutrophils and macrophages and is the primary protease responsible for extracellular elastin degradation. The major serum inhibitor of elastase is **alpha-1 antitrypsin** (AAT). In this study, the patients whose serum is unable to inhibit elastin degradation likely have **AAT deficiency**, a condition characterized by early-onset **panacinar emphysema** due to the unopposed action of neutrophil elastase on alveolar walls.

Explanation

Neutrophil elastase is released by both neutrophils and macrophages and is the primary protease responsible for extracellular elastin degradation. The major serum inhibitor of elastase is **alpha-1 antitrypsin** (AAT). In this study, the patients whose serum is unable to inhibit elastin degradation likely have **AAT deficiency**, a condition characterized by early-onset **panacinar emphysema** due to the unopposed action of neutrophil elastase on alveolar walls.

Tobacco exposure dramatically **accelerates** the **development of emphysema** in patients with AAT deficiency by inducing inflammation (increasing neutrophil and macrophage activation) and permanently inactivating the already low quantities of AAT through oxidation of a crucial methionine residue. Therefore, patients with AAT deficiency should be counseled to avoid smoking and exposure to second-hand smoke.

(Choice A) Patients with hypertrophic cardiomyopathy are at risk for sudden cardiac arrest with exertion and are typically counseled to avoid participation in most competitive sports.

(Choice B) Patients with chronic granulomatous disease (impaired phagocytic intracellular killing due to a defect in nicotinamide adenine dinucleotide phosphate [NADPH] oxidase) should avoid certain immunosuppressive agents (eg, tumor necrosis factor-alpha blockers) due to risk of overwhelming infection.

(Choice D) Periodic aortic diameter monitoring is indicated in patients with Marfan syndrome (impaired fibrillin synthesis), who are at risk for both aortic dissection and chronic aortic regurgitation due to aortic root dilation.

(Choice E) Patients with osteogenesis imperfecta (decreased production of type 1 collagen) are at high risk of developing osteoporosis and should undergo regular bone density monitoring.

(Choice F) Patients with Ehlers-Danlos syndrome (impaired collagen synthesis) are at risk for scleral fragility, ocular globe rupture, and retinal detachment and should undergo routine ophthalmologic exams.

Educational objective:
The major serum inhibitor of extracellular elastase is alpha-1 antitrypsin (AAT); patients with AAT deficiency typically develop early-onset panacinar emphysema due to unchecked elastase activity. Exposure to tobacco smoke dramatically accelerates the development of emphysema in patients with AAT deficiency and should be avoided.

(Choice A) Patients with hypertrophic cardiomyopathy are at risk for sudden cardiac arrest with exertion and are typically counseled to avoid participation in most competitive sports.

(Choice B) Patients with chronic granulomatous disease (impaired phagocytic intracellular killing due to a defect in nicotinamide adenine dinucleotide phosphate [NADPH] oxidase) should avoid certain immunosuppressive agents (eg, tumor necrosis factor-alpha blockers) due to risk of overwhelming infection.

(Choice D) Periodic aortic diameter monitoring is indicated in patients with Marfan syndrome (impaired fibrillin synthesis), who are at risk for both aortic dissection and chronic aortic regurgitation due to aortic root dilation.

(Choice E) Patients with osteogenesis imperfecta (decreased production of type 1 collagen) are at high risk of developing osteoporosis and should undergo regular bone density monitoring.

(Choice F) Patients with Ehlers-Danlos syndrome (impaired collagen synthesis) are at risk for scleral fragility, ocular globe rupture, and retinal detachment and should undergo routine ophthalmologic exams.

Educational objective:
The major serum inhibitor of extracellular elastase is alpha-1 antitrypsin (AAT); patients with AAT deficiency typically develop early-onset panacinar emphysema due to unchecked elastase activity. Exposure to tobacco smoke dramatically accelerates the development of emphysema in patients with AAT deficiency and should be avoided.

References

- Diagnosis and management of patients with a1-antitrypsin (A1AT) deficiency.
- Alpha-1 antitrypsin deficiency.

Pathophysiology	Pulmonary & Critical Care	Alpha1 antitrypsin deficiency
Subject	System	Topic

Copyright © UWorld. All rights reserved.

1 2 3 4 5 6 7 8 9 10 11 12 13 14 15 16 17 18 19 20 21 22 23 24 25 26 27 28 29 30

A 6-year-old Caucasian boy is brought to the office by his mother due to recurrent episodes of sinusitis. He also has a chronic cough that never seems to go away. The mother says that his previous pediatrician performed a "sweat test" to help determine the cause of his frequent infections, but results were normal. DNA testing was inconclusive. Despite these results, the new physician suspects that the patient has an inherited disorder and orders nasal transepithelial potential difference measurements. In this test, an isotonic solution of sodium chloride is applied to the nasal mucosal surface, and the electrical potential overlying the mucosa is compared with that of the interstitial fluid. The results show a transepithelial potential difference that is more negative than normal. This patient's nasal mucosa is most likely to demonstrate which of the following physiologic changes?

A. Decreased bicarbonate secretion

B. Increased chloride secretion

C. Increased mucus water content

D. Increased sodium absorption

E. Intracellular potassium depletion

Submit

A 6-year-old Caucasian boy is brought to the office by his mother due to recurrent episodes of sinusitis. He also has a chronic cough that never seems to go away. The mother says that his previous pediatrician performed a "sweat test" to help determine the cause of his frequent infections, but results were normal. DNA testing was inconclusive. Despite these results, the new physician suspects that the patient has an inherited disorder and orders nasal transepithelial potential difference measurements. In this test, an isotonic solution of sodium chloride is applied to the nasal mucosal surface, and the electrical potential overlying the mucosa is compared with that of the interstitial fluid. The results show a transepithelial potential difference that is more negative than normal. This patient's nasal mucosa is most likely to demonstrate which of the following physiologic changes?

A. Decreased bicarbonate secretion (6%)

B. Increased chloride secretion (38%)

C. Increased mucus water content (7%)

✓ D. Increased sodium absorption (40%)

E. Intracellular potassium depletion (7%)

Omitted
Correct answer
D

40%
Answered correctly

02 secs
Time Spent

01/12/2020
Last Updated

Explanation

Respiratory mucosa

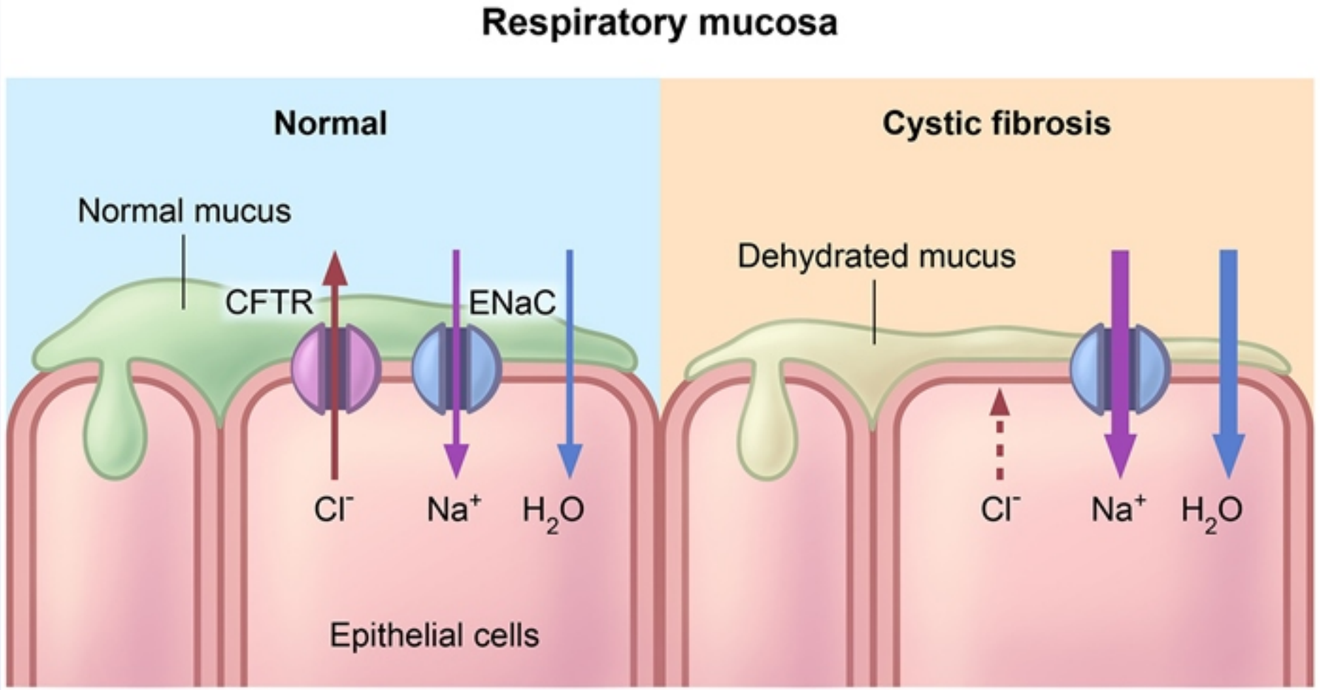

CFTR = cystic fibrosis transmembrane conductance regulator; **ENaC** = epithelial sodium channel.

©UWorld

Chronic cough and recurrent sinusitis in a young Caucasian patient should raise suspicion for **cystic fibrosis** (CF). The diagnosis of CF typically is based on elevated sweat chloride concentrations, characteristic clinical findings (**recurrent sinopulmonary infections**, pancreatic insufficiency), and/or a positive family history. However, patients with mild mutations of the CF transmembrane conductance regulator (*CFTR*) gene may have normal sweat testing. In these cases, a useful diagnostic adjunct involves measuring the nasal transepithelial potential difference.

In intestinal and **respiratory epithelia**, the CFTR channel secretes chloride ions into the lumen and also has a tonic inhibitory effect on the opening of the epithelial sodium channel (ENaC), which decreases sodium reabsorption into the cell. This high luminal salt content helps retain water in the lumen, forming well-hydrated mucus. During the **nasal transepithelial potential difference** test, a saline solution is applied to the nose. Because patients with CF have **increased sodium absorption** via the ENaC, sodium is absorbed intracellularly but chloride in the saline

©UWorld

Chronic cough and recurrent sinusitis in a young Caucasian patient should raise suspicion for **cystic fibrosis** (CF). The diagnosis of CF typically is based on elevated sweat chloride concentrations, characteristic clinical findings (**recurrent sinopulmonary infections**, pancreatic insufficiency), and/or a positive family history. However, patients with mild mutations of the CF transmembrane conductance regulator (*CFTR*) gene may have normal sweat testing. In these cases, a useful diagnostic adjunct involves measuring the nasal transepithelial potential difference.

In intestinal and **respiratory epithelia**, the CFTR channel secretes chloride ions into the lumen and also has a tonic inhibitory effect on the opening of the epithelial sodium channel (ENaC), which decreases sodium reabsorption into the cell. This high luminal salt content helps retain water in the lumen, forming well-hydrated mucus. During the **nasal transepithelial potential difference** test, a saline solution is applied to the nose. Because patients with CF have **increased sodium absorption** via the ENaC, sodium is absorbed intracellularly but chloride in the saline solution is retained in the lumen. The higher relative amounts of negatively charged chloride on the epithelial surface result in a **more negative** transepithelial voltage difference.

CFTR channel functioning is reversed in sweat ducts compared with that in respiratory and intestinal glands. CFTR reduces the salt content of sweat by reabsorbing luminal chloride and stimulating ENaC to increase sodium absorption from the lumen into the cells. *CFTR* mutations therefore result in the production of sweat with high chloride and sodium content.

(Choice A) *CFTR* mutations lower the rate of bicarbonate secretion in the pancreatic ducts, promoting mucin precipitation and the formation of intraductal concretions that cause exocrine pancreatic insufficiency. However, this effect is not related to the nasal transepithelial potential difference test.

(Choice B) *CFTR* mutations impair the passive transport of chloride along its concentration gradient, decreasing chloride secretion by respiratory epithelial cells.

(Choice C) The water content of mucus is decreased (not increased) in patients with CF, resulting in dehydrated mucus that predisposes to the formation of mucus plugs and chronic sinopulmonary infections.

(Choice E) *CFTR* mutations do not significantly alter transmembrane potassium transport.

Educational objective:
In cystic fibrosis, impairment of the cystic fibrosis transmembrane conductance regulator (CFTR) protein reduces chloride secretion and increases

transepithelial voltage difference.

CFTR channel functioning is reversed in sweat ducts compared with that in respiratory and intestinal glands. CFTR reduces the salt content of sweat by reabsorbing luminal chloride and stimulating ENaC to increase sodium absorption from the lumen into the cells. *CFTR* mutations therefore result in the production of sweat with high chloride and sodium content.

(Choice A) *CFTR* mutations lower the rate of bicarbonate secretion in the pancreatic ducts, promoting mucin precipitation and the formation of intraductal concretions that cause exocrine pancreatic insufficiency. However, this effect is not related to the nasal transepithelial potential difference test.

(Choice B) *CFTR* mutations impair the passive transport of chloride along its concentration gradient, decreasing chloride secretion by respiratory epithelial cells.

(Choice C) The water content of mucus is decreased (not increased) in patients with CF, resulting in dehydrated mucus that predisposes to the formation of mucus plugs and chronic sinopulmonary infections.

(Choice E) *CFTR* mutations do not significantly alter transmembrane potassium transport.

Educational objective:
In cystic fibrosis, impairment of the cystic fibrosis transmembrane conductance regulator (CFTR) protein reduces chloride secretion and increases sodium absorption by the respiratory epithelia, resulting in dehydrated mucus. When saline is applied to the nasal mucosa, the increased sodium absorption in patients with CF causes a more negative nasal transepithelial potential difference, which can be used to diagnose cystic fibrosis.

References

- Nasal potential difference measurements to assess CFTR ion channel activity.
- Cystic fibrosis.

Pathophysiology	Pulmonary & Critical Care	Cystic fibrosis
Subject	System	Topic

Copyright © UWorld. All rights reserved.

transepithelial voltage difference.

Exhibit Display

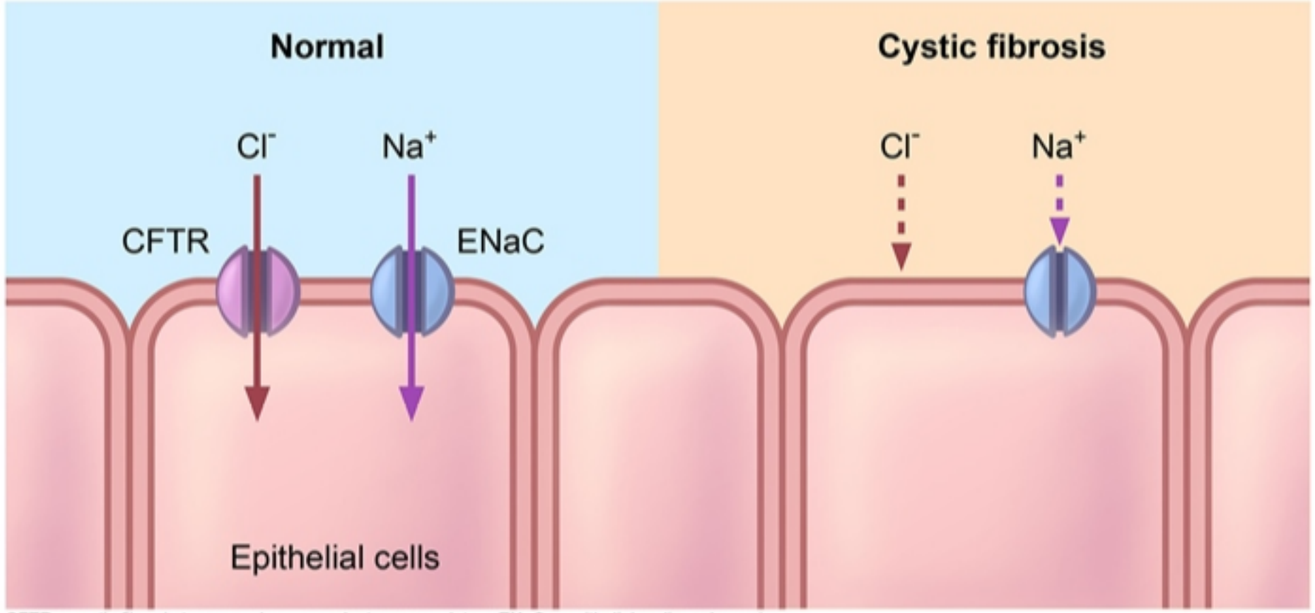

CFTR = cystic fibrosis transmembrane conductance regulator; **ENaC** = epithelial sodium channel.

©UWorld

Zoom In | Zoom Out | Reset | Add To New Card | Existing Card

Copyright © UWorld. All rights reserved.

An 18-year-old man is evaluated for recurrent episodes of shortness of breath, wheezing, runny nose, and watery eyes. The patient reports that his symptoms have recently worsened since he started training outdoors for an upcoming marathon. He does not use tobacco, alcohol, or illicit drugs. Skin testing is performed to determine symptom triggers. A pricking device is used to apply allergen extract underneath the skin. After 15 minutes, the patient develops raised, erythematous plaques with surrounding erythema at the application site. Which of the following mediators is the first to be released during the pathogenesis of this patient's skin findings?

A. Histamine

B. Leukotriene D4

C. Major basic proteins

D. Platelet-activating factor

E. Prostaglandin D2

Submit

An 18-year-old man is evaluated for recurrent episodes of shortness of breath, wheezing, runny nose, and watery eyes. The patient reports that his symptoms have recently worsened since he started training outdoors for an upcoming marathon. He does not use tobacco, alcohol, or illicit drugs. Skin testing is performed to determine symptom triggers. A pricking device is used to apply allergen extract underneath the skin. After 15 minutes, the patient develops raised, erythematous plaques with surrounding erythema at the application site. Which of the following mediators is the first to be released during the pathogenesis of this patient's skin findings?

- ✓ A. Histamine (86%)
- B. Leukotriene D4 (5%)
- C. Major basic proteins (4%)
- D. Platelet-activating factor (0%)
- E. Prostaglandin D2 (1%)

Omitted
Correct answer
A

86%
Answered correctly

02 secs
Time Spent

07/05/2020
Last Updated

Explanation

Pathogenesis of asthma

Initial exposure | **Repeat exposure**

Pathogenesis of asthma

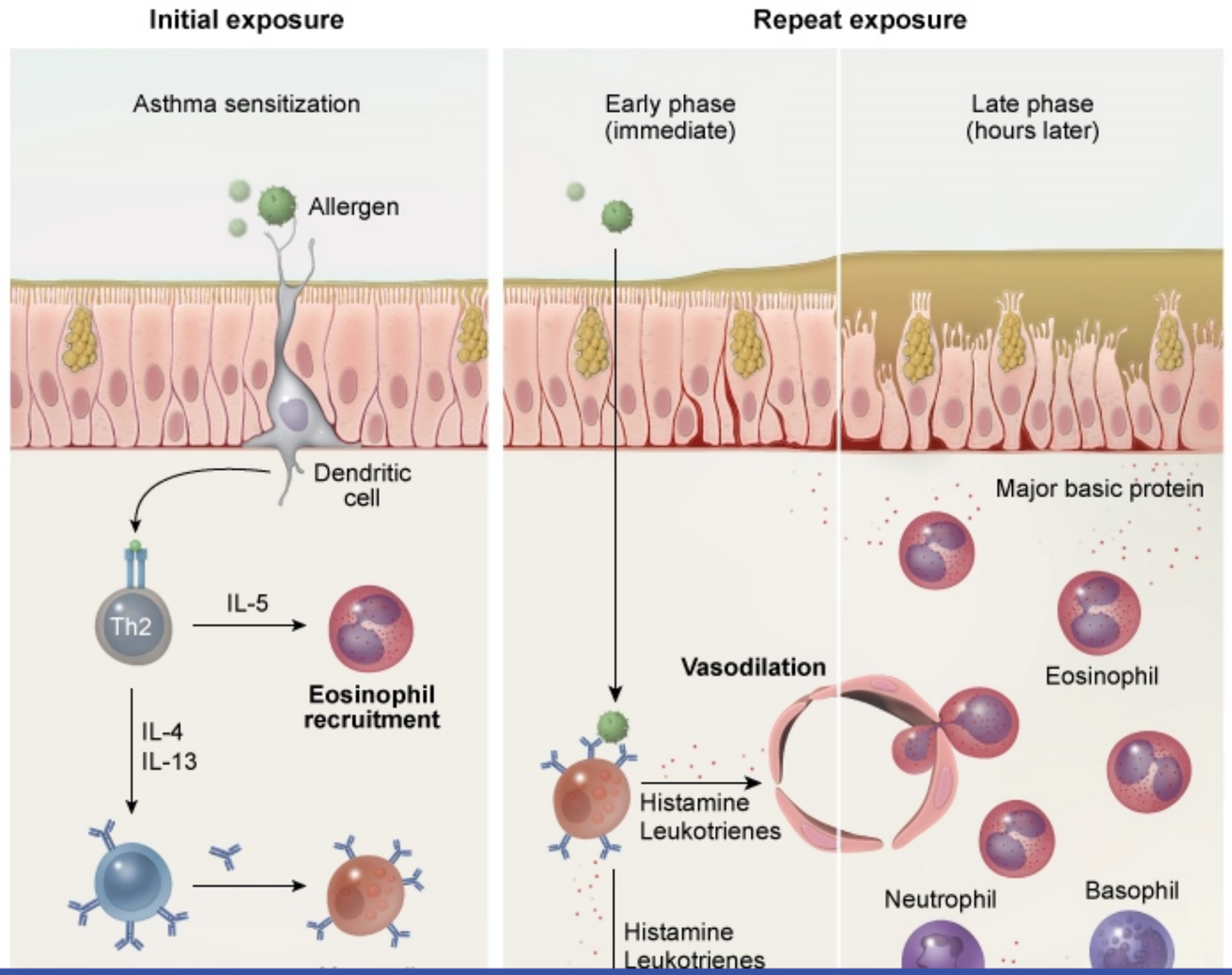

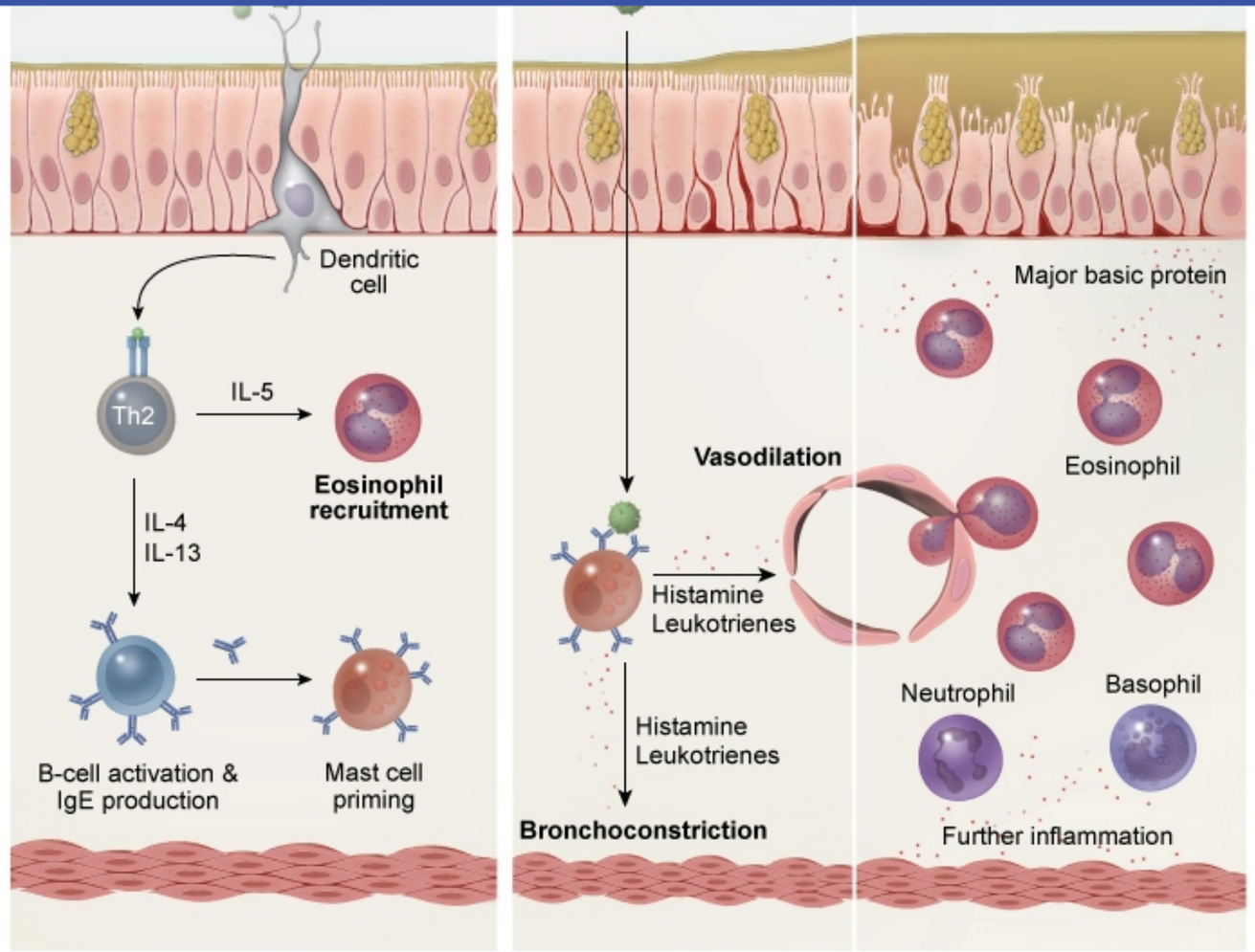

©UWorld

This patient's shortness of breath and wheezing are suggestive of **asthma**, and his rhinorrhea and watery eyes are suggestive of **allergic rhinitis**. Both of these conditions are examples of **type I hypersensitivity**, which involves the triggering of an allergic response via the binding of previously recognized antigen to IgE antibodies on **mast cells**. Many type I hypersensitivity reactions are composed of both an early and late

©UWorld

This patient's shortness of breath and wheezing are suggestive of **asthma**, and his rhinorrhea and watery eyes are suggestive of **allergic rhinitis**. Both of these conditions are examples of **type I hypersensitivity**, which involves the triggering of an allergic response via the binding of previously recognized antigen to IgE antibodies on **mast cells**. Many type I hypersensitivity reactions are composed of both an early and late phase.

Histamine is housed in **preformed granules** of unactivated mast cells and plays an important role in the early phase of type I hypersensitivity. Upon activation, mast cells rapidly release histamine via degranulation, making histamine the first chemical mediator to take effect. Once released, histamine triggers smooth muscle contraction leading to bronchoconstriction, increases vascular permeability leading to edema, and increases mucus secretion from glandular tissue.

(Choice B) Leukotriene D4, along with the other cysteinyl leukotrienes (C4 and E4), are not preformed but require synthesis via the 5-lipoxygenase pathway of arachidonic acid metabolism. Therefore, these mediators are released by mast cells later than histamine. Once released, the cysteinyl leukotrienes are potent mediators of vasoconstriction, bronchoconstriction, and increased vascular permeability.

(Choice C) Major basic protein is released from eosinophils in the late stage of a type I hypersensitivity reaction and causes localized tissue damage.

(Choice D) Platelet-activating factor is a secondary inflammatory mediator that must be synthesized from phospholipid prior to being released from activated mast cells and basophils. Once released, it stimulates bronchospasm and increased vascular permeability.

(Choice E) Prostaglandin D2 is synthesized via the cyclooxygenase pathway of arachidonic acid metabolism prior to being released from mast cells. Once released, it causes bronchospasm and vasodilation.

Educational objective:
Type I hypersensitivity reactions are an allergic response triggered by the binding of previously recognized antigen to IgE antibodies on mast cells. In the early phase of the response, histamine, already stored in preformed granules in mast cells, is the first chemical mediator released. Once released, histamine stimulates smooth muscle contraction (bronchoconstriction), increases vascular permeability (edema), and increases mucus secretion.

References

©UWorld

Exhibit Display

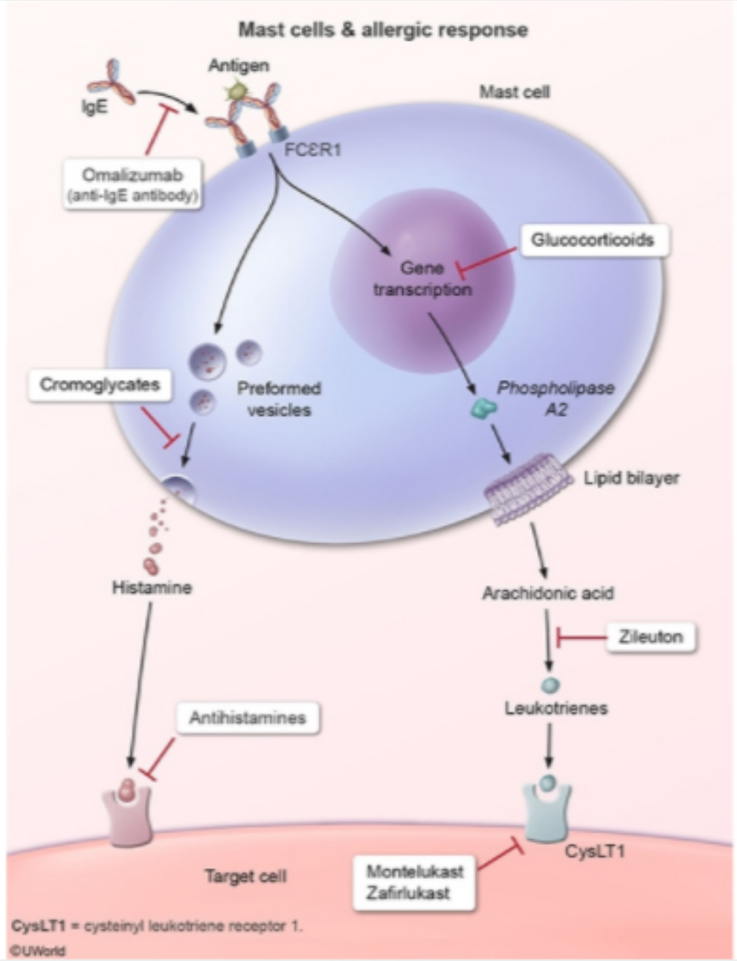

Zoom In | Zoom Out | Reset | Add To New Card | Existing Card

References

©UWorld

Exhibit Display

Arachidonic acid metabolic pathways

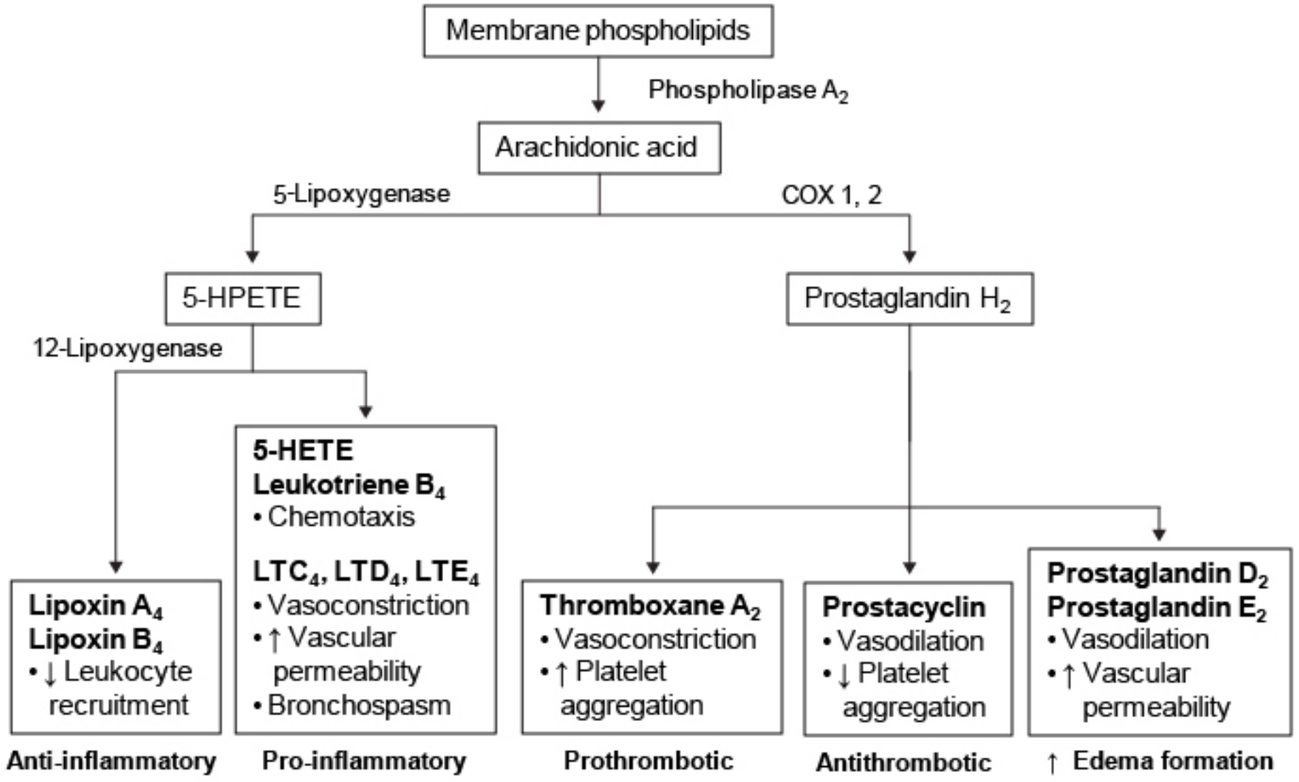

©UWorld

Zoom In | Zoom Out | Reset | Add To New Card | Existing Card

References

Upon activation, mast cells rapidly release histamine via degranulation, making histamine the first chemical mediator to take effect. Once released, histamine triggers smooth muscle contraction leading to bronchoconstriction, increases vascular permeability leading to edema, and increases mucus secretion from glandular tissue.

(Choice B) Leukotriene D4, along with the other cysteinyl leukotrienes (C4 and E4), are not preformed but require synthesis via the 5-lipoxygenase pathway of arachidonic acid metabolism. Therefore, these mediators are released by mast cells later than histamine. Once released, the cysteinyl leukotrienes are potent mediators of vasoconstriction, bronchoconstriction, and increased vascular permeability.

(Choice C) Major basic protein is released from eosinophils in the late stage of a type I hypersensitivity reaction and causes localized tissue damage.

(Choice D) Platelet-activating factor is a secondary inflammatory mediator that must be synthesized from phospholipid prior to being released from activated mast cells and basophils. Once released, it stimulates bronchospasm and increased vascular permeability.

(Choice E) Prostaglandin D2 is synthesized via the cyclooxygenase pathway of arachidonic acid metabolism prior to being released from mast cells. Once released, it causes bronchospasm and vasodilation.

Educational objective:

Type I hypersensitivity reactions are an allergic response triggered by the binding of previously recognized antigen to IgE antibodies on mast cells. In the early phase of the response, histamine, already stored in preformed granules in mast cells, is the first chemical mediator released. Once released, histamine stimulates smooth muscle contraction (bronchoconstriction), increases vascular permeability (edema), and increases mucus secretion.

References

- The development of allergic inflammation.

Pathophysiology	Pulmonary & Critical Care	Allergic rhinitis
Subject	System	Topic

Copyright © UWorld. All rights reserved.

A 76-year-old man is brought to the emergency department after being involved in a motor vehicle collision. He is found to have a laceration of the spleen and is taken for emergent laparotomy. During surgery, the patient goes into cardiac arrest and dies, despite aggressive resuscitation efforts. Autopsy examination is performed and shows areas of thickening inside the chest wall as shown below.

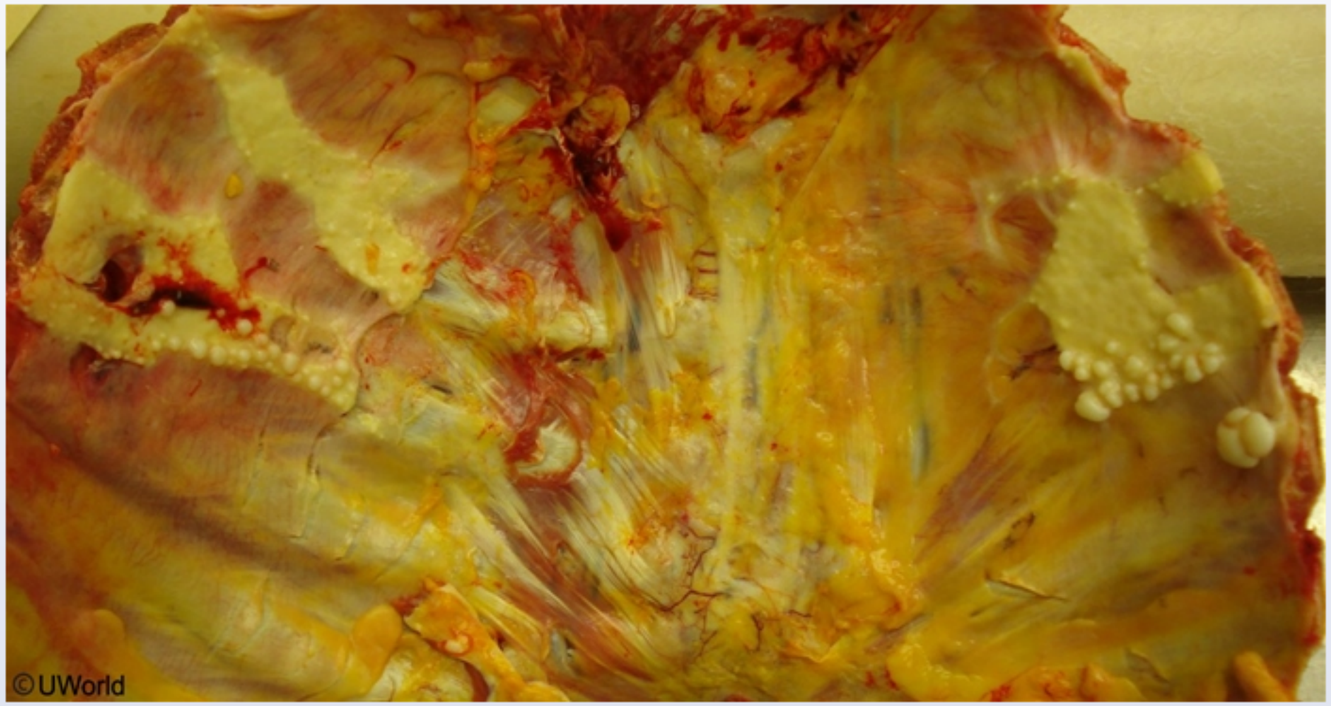

Lung examination shows fibrosis of the lower lobes. Pathologic examination of these fibrotic areas is most likely to reveal which of the following findings?

A. Alveolar hyaline membranes

B. Birefringent silicate particles

1 2 3 4 5 6 7 8 9 10 11 12 13 14 15 16 17 18 19 20 21 22 23 24 25 26 27 28 29 30

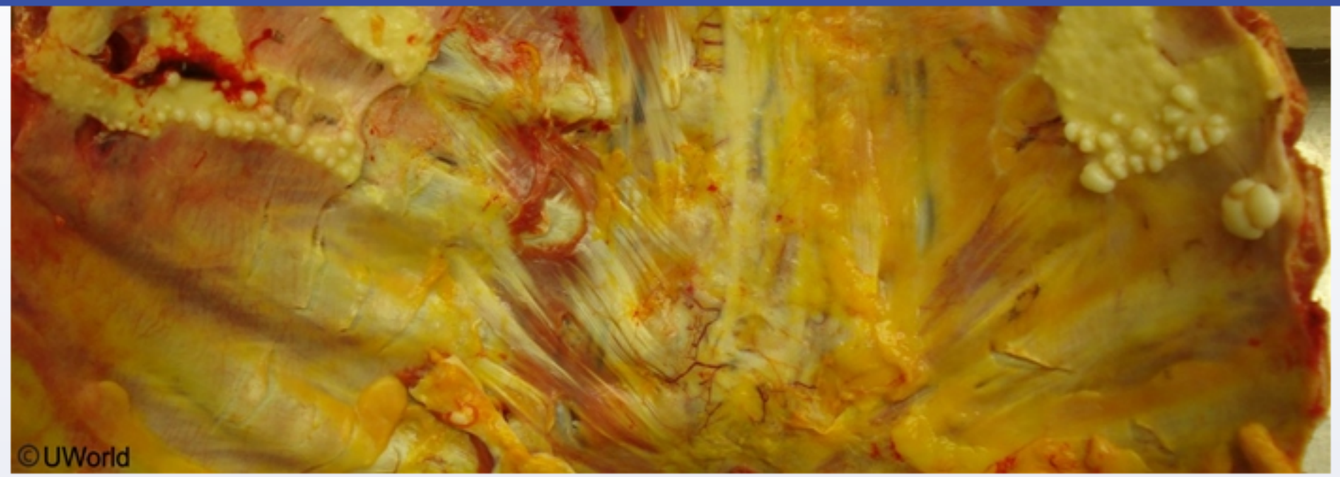

Lung examination shows fibrosis of the lower lobes. Pathologic examination of these fibrotic areas is most likely to reveal which of the following findings?

- A. Alveolar hyaline membranes
- B. Birefringent silicate particles
- C. Carbon-laden macrophages
- D. Cells with dense-core granules
- E. Coalescence of granulomas
- F. Ferruginous bodies

Submit

1 2 3 4 5 6 7 8 9 10 11 12 13 14 15 16 17 18 19 20 21 22 23 24 25 26 27 28 29 30

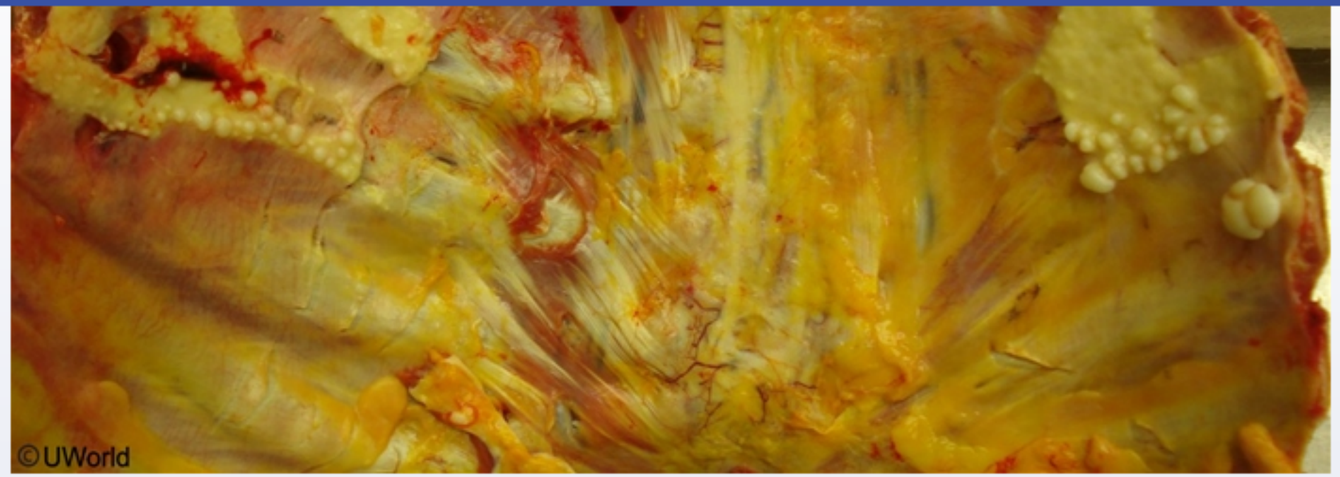

Lung examination shows fibrosis of the lower lobes. Pathologic examination of these fibrotic areas is most likely to reveal which of the following findings?

A. Alveolar hyaline membranes (10%)

B. Birefringent silicate particles (12%)

C. Carbon-laden macrophages (5%)

D. Cells with dense-core granules (8%)

E. Coalescence of granulomas (7%)

✓ F. Ferruginous bodies (56%)

Omitted
Correct answer

56%
Answered correctly

05 secs
Time Spent

01/28/2020
Last Updated

Asbestos exposure

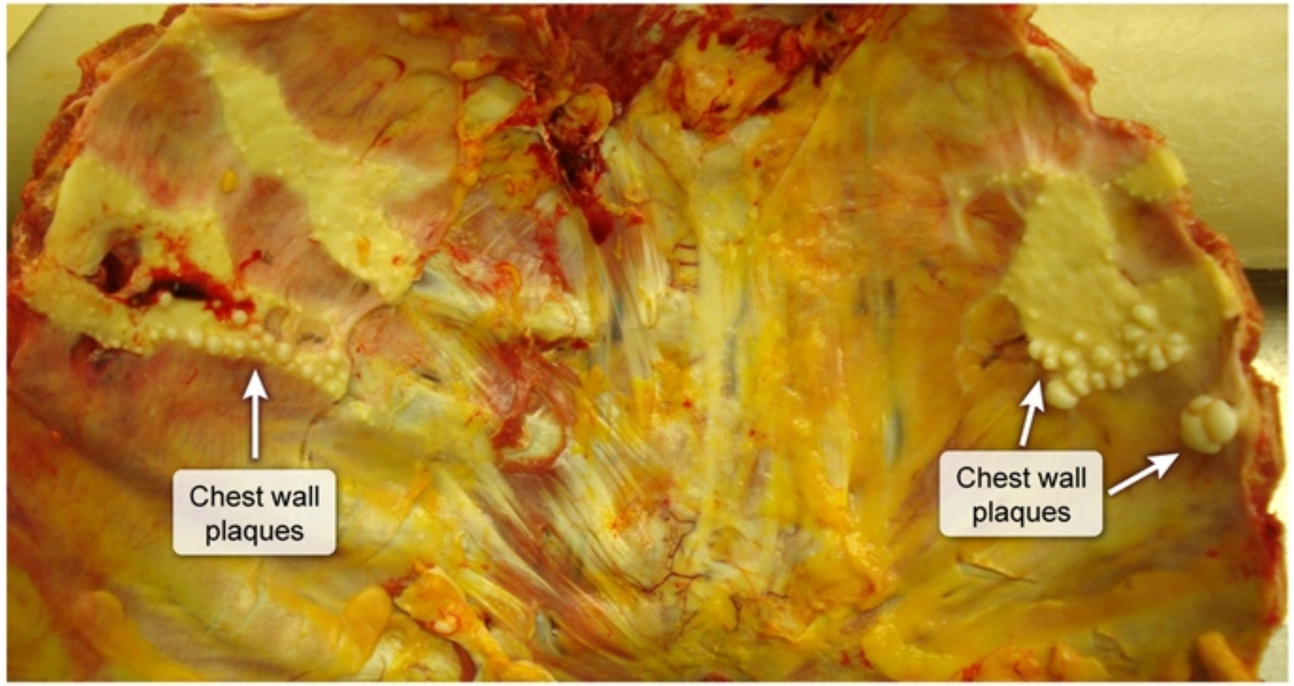

©UWorld

This elderly patient had pleural plaques (focal thickening and calcification of the parietal pleura) and lower lung fibrosis, consistent with **pleuropulmonary asbestosis**. Asbestosis is a pneumoconiosis that occurs with inhalation of asbestos fibers (hydrated magnesium silicates), typically in patients with occupational exposure (eg, insulation installation, shipbuilding, pipe work). Patients are typically asymptomatic for 20-30 years after initial exposure; dyspnea, cough, and fatigue are common presenting symptoms.

CT radiography in asbestosis demonstrates bilateral parenchymal **fibrosis**, most predominant in the **lower lungs**; honeycombing and upper lung involvement occur in advanced disease. Pleural disease is common and includes **pleural plaques**, diffuse pleural thickening, or benign pleural effusions. Histopathology typically demonstrates diffuse **interstitial fibrosis** in association with ferruginous bodies (golden brown, rod- or

This elderly patient had pleural plaques (focal thickening and calcification of the parietal pleura) and lower lung fibrosis, consistent with **pleuropulmonary asbestosis**. Asbestosis is a pneumoconiosis that occurs with inhalation of asbestos fibers (hydrated magnesium silicates), typically in patients with occupational exposure (eg, insulation installation, shipbuilding, pipe work). Patients are typically asymptomatic for 20-30 years after initial exposure; dyspnea, cough, and fatigue are common presenting symptoms.

CT radiography in asbestosis demonstrates bilateral parenchymal **fibrosis**, most predominant in the **lower lungs**; honeycombing and upper lung involvement occur in advanced disease. Pleural disease is common and includes **pleural plaques**, diffuse pleural thickening, or benign pleural effusions. Histopathology typically demonstrates diffuse **interstitial fibrosis** in association with ferruginous bodies (golden brown, rod- or fusiform-shaped fibers coated with iron-protein complexes). Asbestos fibers can be differentiated from other ferruginous bodies (eg, carbon, talc) by their **translucent** fiber core.

(Choice A) Hyaline membranes within the alveoli are seen in acute respiratory distress syndrome (ARDS) and can occur after severe trauma or sepsis. ARDS can lead to fibrosis, but this typically occurs weeks to months after the initial pulmonary insult and is not associated with pleural plaques.

(Choice B) Birefringent silicate particles are seen in silicosis, which typically presents with innumerable nodules that predominate in the upper lungs; egg-shell calcifications of the hilar lymph nodes may also be seen. Pleural plaques are unexpected.

(Choice C) Carbon-laden macrophages are seen in coal workers pneumoconiosis. Gross pathology demonstrates black coal nodules distributed throughout the upper lungs.

(Choice D) Carcinoid tumors are neuroendocrine malignancies that appear histologically as sheets of uniform cells with dense core granules noted on electron microscopy. They sometimes cause carcinoid syndrome (eg, flushing, diarrhea, wheezing), which is seen more commonly with gastrointestinal tumors. However, they tend to involve the large bronchi; fibrosis and pleural plaques are unexpected.

(Choice E) Chronic granulomatous disease is an immunodeficiency due to the inability of phagocytes to produce reactive oxygen species. Patients develop excessive granuloma formation and recurrent bacterial and fungal infections. Patients are typically diagnosed in childhood.

Educational objective:
Asbestosis is a pneumoconiosis that occurs with inhalation of asbestos fibers, most commonly in patients with occupational exposure (eg, insulation installation, shipbuilding, pipe work). Histopathology demonstrates diffuse interstitial fibrosis and ferruginous asbestos bodies.

effusions. Histopathology typically demonstrates diffuse **interstitial fibrosis** in association with ferruginous bodies (golden brown, rod- or fusiform-shaped fibers coated with iron-protein complexes). Asbestos fibers can be differentiated from other ferruginous bodies (eg, carbon, talc) by their **translucent** fiber core.

(Choice A) Hyaline membranes within the alveoli are seen in acute respiratory distress syndrome (ARDS) and can occur after severe trauma or sepsis. ARDS can lead to fibrosis, but this typically occurs weeks to months after the initial pulmonary insult and is not associated with pleural plaques.

(Choice B) Birefringent silicate particles are seen in silicosis, which typically presents with innumerable nodules that predominate in the upper lungs; egg-shell calcifications of the hilar lymph nodes may also be seen. Pleural plaques are unexpected.

(Choice C) Carbon-laden macrophages are seen in coal workers pneumoconiosis. Gross pathology demonstrates black coal nodules distributed throughout the upper lungs.

(Choice D) Carcinoid tumors are neuroendocrine malignancies that appear histologically as sheets of uniform cells with dense core granules noted on electron microscopy. They sometimes cause carcinoid syndrome (eg, flushing, diarrhea, wheezing), which is seen more commonly with gastrointestinal tumors. However, they tend to involve the large bronchi; fibrosis and pleural plaques are unexpected.

(Choice E) Chronic granulomatous disease is an immunodeficiency due to the inability of phagocytes to produce reactive oxygen species. Patients develop excessive granuloma formation and recurrent bacterial and fungal infections. Patients are typically diagnosed in childhood.

Educational objective:
Asbestosis is a pneumoconiosis that occurs with inhalation of asbestos fibers, most commonly in patients with occupational exposure (eg, insulation installation, shipbuilding, pipe work). Histopathology demonstrates diffuse interstitial fibrosis and ferruginous asbestos bodies (translucent fibers coated with a golden iron-containing material). Pleural disease (eg, plaques, benign effusions) is common.

Pathophysiology	Pulmonary & Critical Care	Asbestos
Subject	System	Topic

Copyright © UWorld. All rights reserved.

Settings

1 2 3 4 5 6 7 8 9 10 11 12 13 14 15 16 17 18 19 20 21 22 23 24 25 26 27 28 29 30

Item 15 of 40
Question Id: 15335

Mark | Previous | Next | Full Screen | Tutorial | Lab Values | Notes | Calculator | Reverse Color | Text Zoom | Settings

Exhibit Display

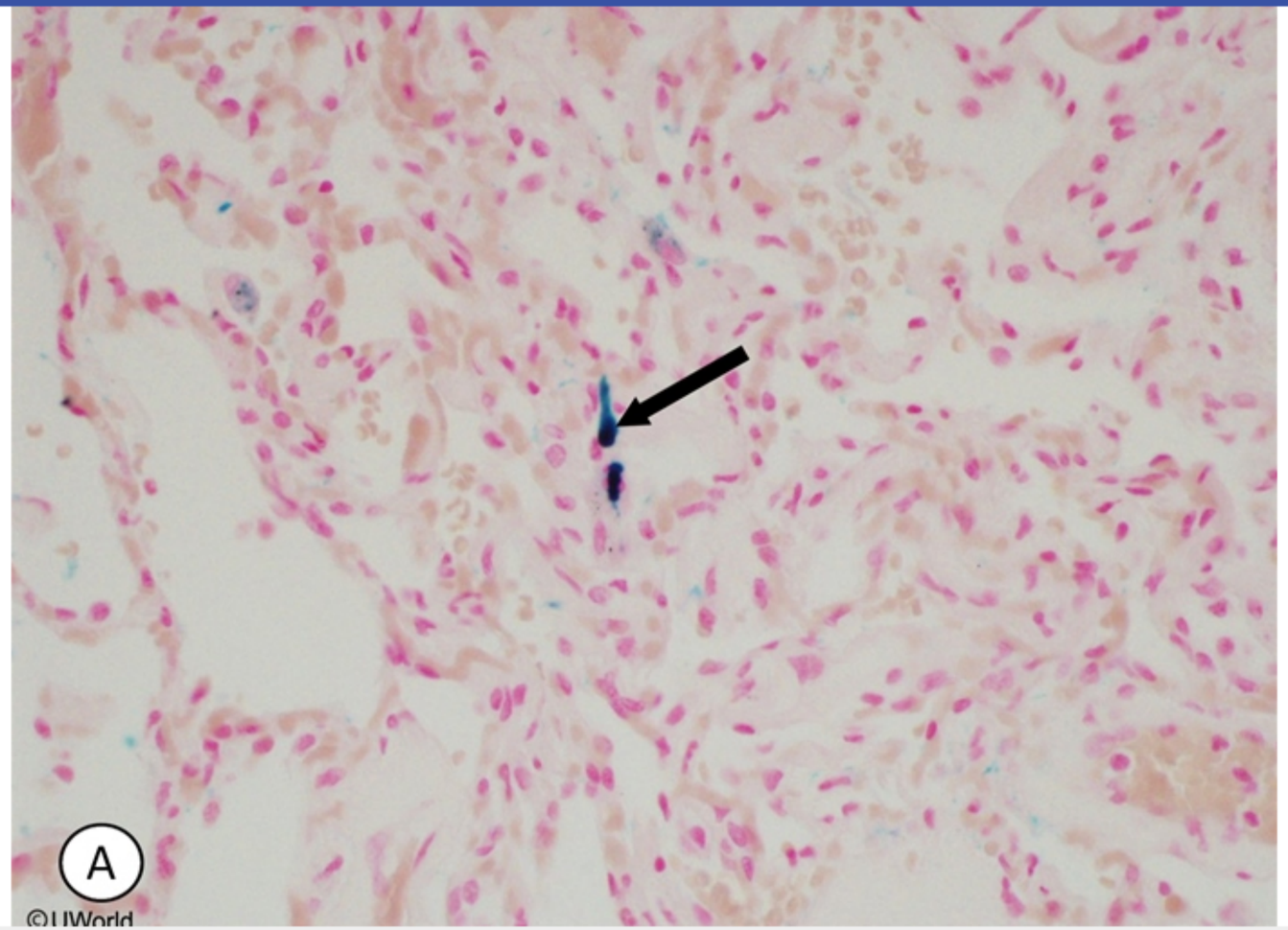

Zoom In | Zoom Out | Reset | Add To New Card | Existing Card

Block Time Remaining: 00:00:58
TUTOR

3 | Feedback | Suspend | End Block

A 56-year-old man comes to the office due to worsening cough for the past several months. He initially had a morning cough productive of minimal sputum, but now the cough occurs throughout the day with large amounts of yellowish sputum. The patient also has breathlessness on moderate exertion. He has had 3 hospitalizations over the past year for respiratory infections. The patient has smoked a pack of cigarettes daily for the past 30 years and has failed multiple attempts to quit. Oxygen saturation is 90% at rest and decreases to 84% with moderate exertion. Which of the following additional findings is most likely to be seen in this patient?

- A. Decreased functional residual capacity
- B. Decreased right ventricular afterload
- C. Increased erythropoietin production
- D. Increased expiratory flow rates
- E. Increased left ventricular compliance

Submit

A 56-year-old man comes to the office due to worsening cough for the past several months. He initially had a morning cough productive of minimal sputum, but now the cough occurs throughout the day with large amounts of yellowish sputum. The patient also has breathlessness on moderate exertion. He has had 3 hospitalizations over the past year for respiratory infections. The patient has smoked a pack of cigarettes daily for the past 30 years and has failed multiple attempts to quit. Oxygen saturation is 90% at rest and decreases to 84% with moderate exertion. Which of the following additional findings is most likely to be seen in this patient?

- A. Decreased functional residual capacity (15%)
- B. Decreased right ventricular afterload (3%)
- ✓ C. Increased erythropoietin production (70%)
- D. Increased expiratory flow rates (7%)
- E. Increased left ventricular compliance (3%)

Omitted
Correct answer
C

70%
Answered correctly

02 secs
Time Spent

04/04/2020
Last Updated

Explanation

This patient with progressive dyspnea and productive cough in the setting of significant smoking history likely has **chronic obstructive pulmonary disease** (COPD). His recent hospitalizations for respiratory infections likely represent COPD exacerbations.

Hypoxemia (O_2 saturation <92%) is common in advanced COPD and occurs via 2 major mechanisms:

- Emphysematous destruction of the alveolar-capillary membrane results in impaired diffusion of O_2

Explanation

This patient with progressive dyspnea and productive cough in the setting of significant smoking history likely has **chronic obstructive pulmonary disease** (COPD). His recent hospitalizations for respiratory infections likely represent COPD exacerbations.

Hypoxemia (O_2 saturation <92%) is common in advanced COPD and occurs via 2 major mechanisms:

- Emphysematous destruction of the alveolar-capillary membrane results in impaired diffusion of O_2.
- Airway obstruction (due to bronchial inflammation and mucus secretion) and air-trapping (due to both bronchial inflammation and emphysematous airway collapse) cause ventilation-perfusion mismatching.

Hypoxemia leads to hypoxia throughout the tissues of the body, which is sensed by specialized interstitial cells in the **renal cortex and medulla**. In response, these cells release **erythropoietin**, which stimulates the bone marrow to increase production of red blood cells and bolster the oxygen-carrying capacity of the blood. The resulting increase in hematocrit, known as **secondary polycythemia**, is an expected finding in diseases or conditions that cause significant chronic hypoxemia (eg, COPD, interstitial lung disease, obesity hypoventilation syndrome, residing at high altitude).

(Choice A) Air-trapping leads to an increase in the functional residual capacity in patients with COPD.

(Choice B) Hypoxic vasoconstriction in advanced COPD increases pulmonary vascular resistance and leads to increased right ventricular afterload.

(Choice D) Airway obstruction in COPD leads to decreased expiratory flow rates. This is apparent as a reduction in forced expiratory volume in 1 second (FEV1).

(Choice E) Left ventricular compliance is increased in conditions that lead to eccentric left ventricular hypertrophy (eg, dilated cardiomyopathy, ischemic heart disease, severe aortic or mitral valve regurgitation). It is not significantly affected in COPD.

Educational objective:
In response to tissue hypoxia, specialized interstitial cells in the renal medulla and cortex release erythropoietin to stimulate the bone marrow to increase red blood cell production and improve the oxygen-carrying capacity of the blood. This response, known as secondary polycythemia, is an expected finding in diseases or conditions that cause significant chronic hypoxemia (eg, chronic obstructive pulmonary disease).

1 2 3 4 5 6 7 8 9 10 11 12 13 14 15 16 17 18 19 20 21 22 23 24 25 26 27 28 29 30

Explanation

Exhibit Display

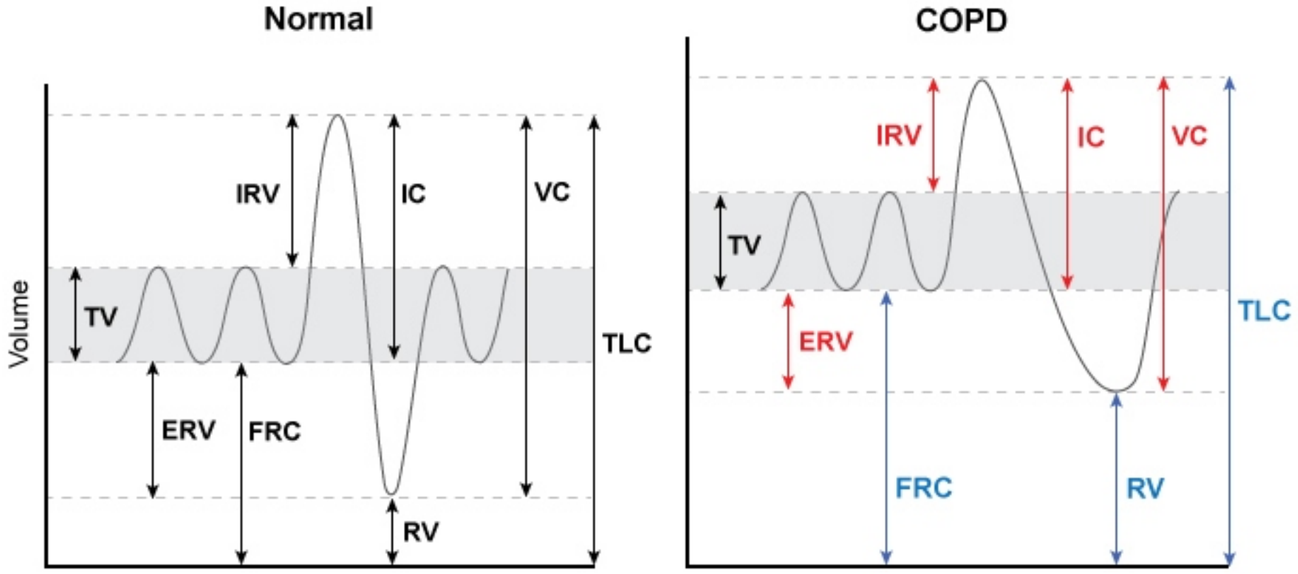

COPD = chronic obstructive pulmonary disease; **ERV** = expiratory reserve volume; **IC** = inspiratory capacity; **IRV** = inspiratory reserve volume; **FRC** = functional residual capacity; **RV** = residual volume; **TLC** = total lung capacity; **TV** = tidal volume; **VC** = vital capacity.

©UWorld

Zoom In | Zoom Out | Reset | Add To New Card | Existing Card

an expected finding in diseases or conditions that cause significant chronic hypoxemia (eg, chronic obstructive pulmonary disease).

- Emphysematous destruction of the alveolar-capillary membrane results in impaired diffusion of O_2.
- Airway obstruction (due to bronchial inflammation and mucus secretion) and air-trapping (due to both bronchial inflammation and emphysematous airway collapse) cause ventilation-perfusion mismatching.

Hypoxemia leads to hypoxia throughout the tissues of the body, which is sensed by specialized interstitial cells in the **renal cortex and medulla**. In response, these cells release **erythropoietin**, which stimulates the bone marrow to increase production of red blood cells and bolster the oxygen-carrying capacity of the blood. The resulting increase in hematocrit, known as **secondary polycythemia**, is an expected finding in diseases or conditions that cause significant chronic hypoxemia (eg, COPD, interstitial lung disease, obesity hypoventilation syndrome, residing at high altitude).

(Choice A) Air-trapping leads to an increase in the functional residual capacity in patients with COPD.

(Choice B) Hypoxic vasoconstriction in advanced COPD increases pulmonary vascular resistance and leads to increased right ventricular afterload.

(Choice D) Airway obstruction in COPD leads to decreased expiratory flow rates. This is apparent as a reduction in forced expiratory volume in 1 second (FEV1).

(Choice E) Left ventricular compliance is increased in conditions that lead to eccentric left ventricular hypertrophy (eg, dilated cardiomyopathy, ischemic heart disease, severe aortic or mitral valve regurgitation). It is not significantly affected in COPD.

Educational objective:
In response to tissue hypoxia, specialized interstitial cells in the renal medulla and cortex release erythropoietin to stimulate the bone marrow to increase red blood cell production and improve the oxygen-carrying capacity of the blood. This response, known as secondary polycythemia, is an expected finding in diseases or conditions that cause significant chronic hypoxemia (eg, chronic obstructive pulmonary disease).

Pathophysiology	Pulmonary & Critical Care	Polycythemia
Subject	System	Topic

Copyright © UWorld. All rights reserved.

A 76-year-old man has had worsening shortness of breath, cough, and weight loss for the past several months. He is a lifelong nonsmoker. Chest imaging reveals irregular pleural thickening. A surgical biopsy is planned, but the patient refuses, choosing to receive hospice care instead. He dies several weeks later. Autopsy examination is performed, and a photograph of the cut lung section is shown below.

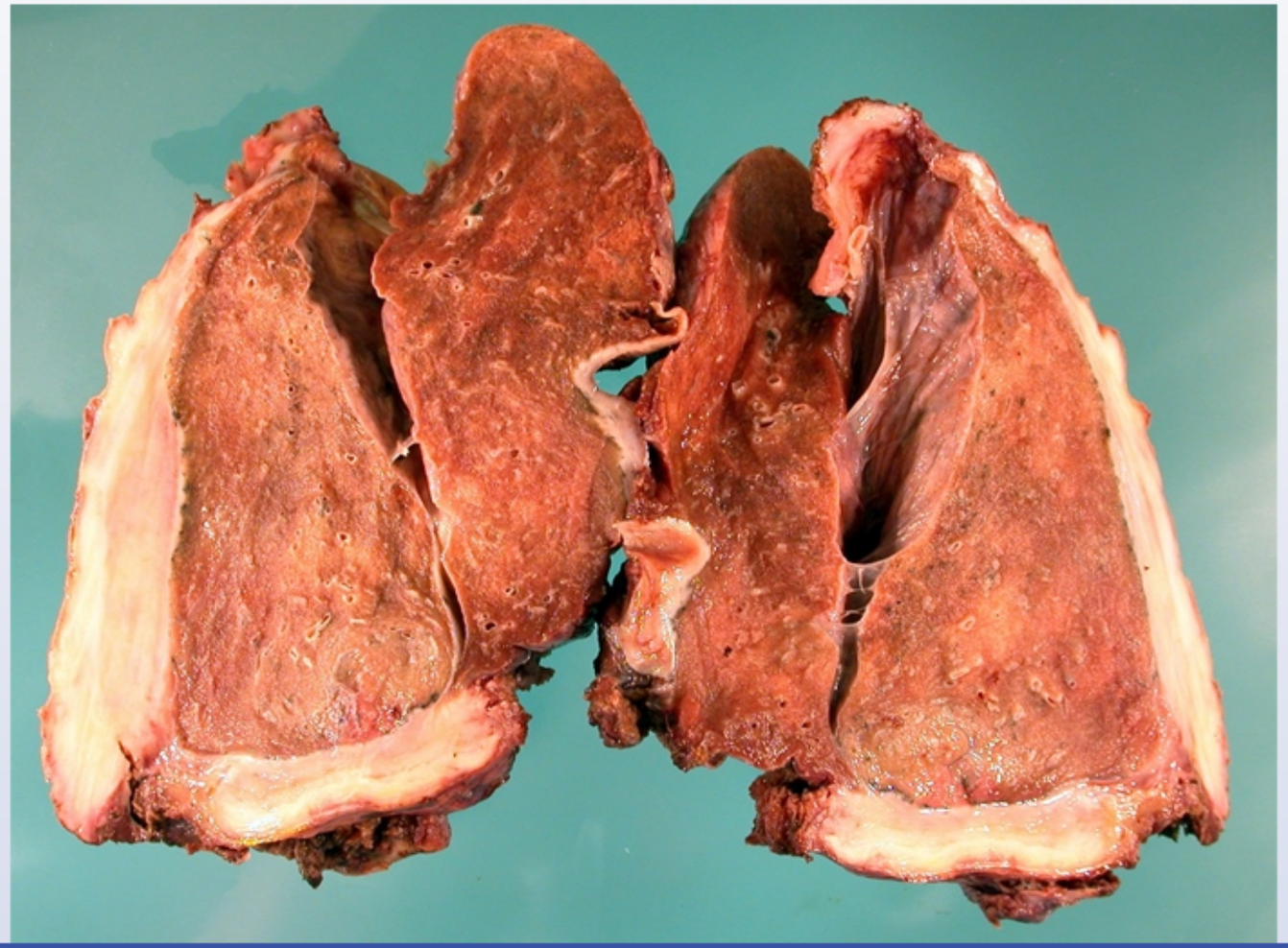

1 2 3 4 5 6 7 8 9 10 11 12 13 14 15 16 17 18 19 20 21 22 23 24 25 26 27 28 29 30

Histopathological examination of the abnormal tissue is most likely to reveal which of the following findings?

- A. Caseating granulomas with giant cells
- B. Central areas of whorled collagen fibers
- C. Small round cells positive for chromogranin
- D. Spindle cells positive for cytokeratin
- E. Thick, fibrinous exudate and pus

Submit

1 2 3 4 5 6 7 8 9 10 11 12 13 14 15 16 17 18 19 20 21 22 23 24 25 26 27 28 29 30

Histopathological examination of the abnormal tissue is most likely to reveal which of the following findings?

- A. Caseating granulomas with giant cells (6%)
- B. Central areas of whorled collagen fibers (30%)
- C. Small round cells positive for chromogranin (9%)
- ✓ D. Spindle cells positive for cytokeratin (37%)
- E. Thick, fibrinous exudate and pus (15%)

Omitted
Correct answer

37%
Answered correctly

04 secs
Time Spent

04/17/2020
Last Updated

Explanation

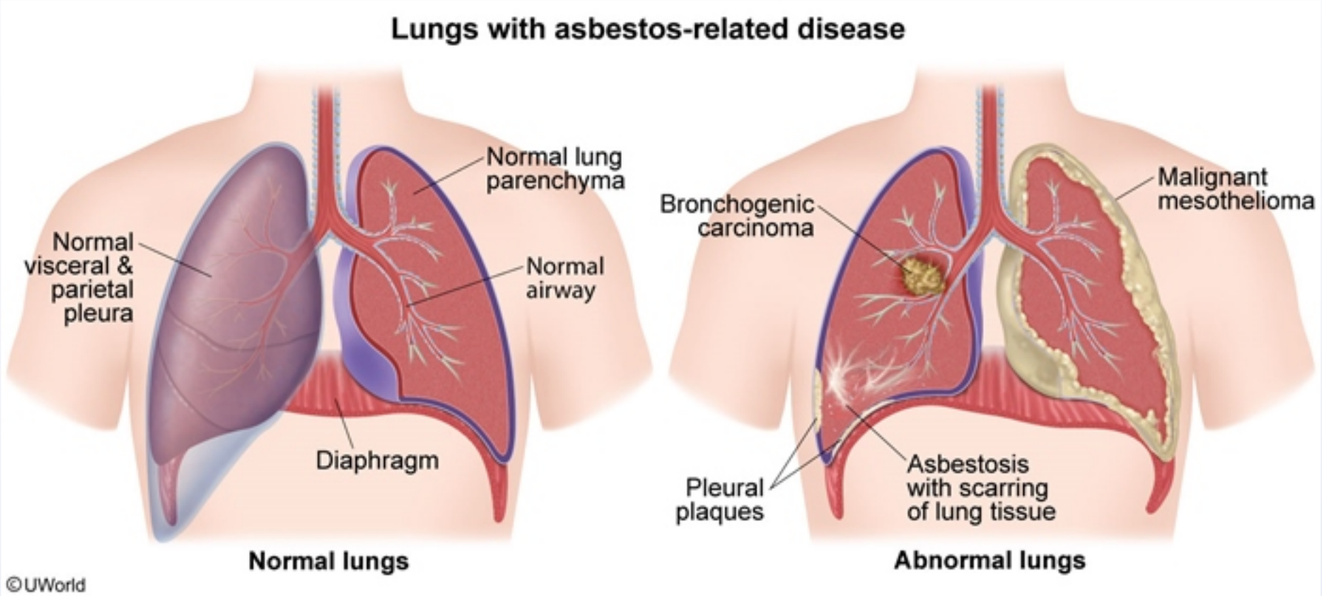

This nonsmoking patient with dyspnea, cough, and weight loss has pleural thickening on imaging; gross pathology of the lungs demonstrates an encasement of the lungs in a rind-like, calcified mass. This presentation is consistent with **mesothelioma**, a rare, malignant neoplasm arising from the mesothelial cells that line body cavities (eg, pleural, peritoneal, pericardial).

In early mesothelioma, multiple nodules form on the parietal pleura and gradually grow to encase the lung parenchyma (which is typically uninvolved). Pleural effusions are common and frequently hemorrhagic. Mesotheliomas typically present with slowly progressive dyspnea, cough, chest pain, and weight loss. **Asbestos** exposure is the primary risk factor; individuals with occupational exposure (eg, mining, shipbuilding, insulation installation) are at increased risk.

Histologically, mesothelioma can appear as cuboidal or flattened cells (epithelium-like) or **spindle cells** (stromal-like). Immunohistochemistry is an important diagnostic marker; nearly all cases of mesothelioma will stain positive for **cytokeratins** and many will also typically stain positive for **calretinin**. Electron microscopy usually shows polygonal tumor cells with numerous long, slender microvilli and **abundant tonofilaments**.

This nonsmoking patient with dyspnea, cough, and weight loss has pleural thickening on imaging; gross pathology of the lungs demonstrates an encasement of the lungs in a rind-like, calcified mass. This presentation is consistent with **mesothelioma**, a rare, malignant neoplasm arising from the mesothelial cells that line body cavities (eg, pleural, peritoneal, pericardial).

In early mesothelioma, multiple nodules form on the parietal pleura and gradually grow to encase the lung parenchyma (which is typically uninvolved). Pleural effusions are common and frequently hemorrhagic. Mesotheliomas typically present with slowly progressive dyspnea, cough, chest pain, and weight loss. **Asbestos** exposure is the primary risk factor; individuals with occupational exposure (eg, mining, shipbuilding, insulation installation) are at increased risk.

Histologically, mesothelioma can appear as cuboidal or flattened cells (epithelium-like) or **spindle cells** (stromal-like). Immunohistochemistry is an important diagnostic marker; nearly all cases of mesothelioma will stain positive for **cytokeratins** and many will also typically stain positive for **calretinin**. Electron microscopy usually shows polygonal tumor cells with numerous long, slender microvilli and **abundant tonofilaments**.

(Choice A) Tuberculosis is characterized by caseating granulomas with giant cell formation; patients typically have hilar adenopathy and upper lobe infiltrates. Tuberculosis occurs most commonly in immunosuppressed patients or those at high exposure risk (eg, health care workers, incarcerated individuals).

(Choice B) Silicosis is associated with inhaled silica (eg, mining, sand blasting); histology demonstrates nodules composed of whorled collagen fibers and dust-laden macrophages. Imaging demonstrates innumerable upper lobe–predominant nodes within the pulmonary parenchyma.

(Choice C) Small cell lung cancer is characterized by small round cells; however, this malignancy typically arises in the central airways (not the pleura). Neuroendocrine markers, including chromogranin and synaptophysin, are typically positive.

(Choice E) Empyema—composed of a thick, fibrinous exudate and pus—typically occurs when bacteria infect the pleural space (typically from an associated pneumonia). Patients often present with fever, chills, and (occasionally) sepsis, not months of weight loss and dyspnea.

Educational objective:
Mesothelioma is a neoplasm arising from mesothelial cells and is strongly associated with asbestos exposure. In early mesothelioma, multiple nodules form on the parietal pleura and gradually encase the lung parenchyma. Immunohistochemistry is important for diagnosis; nearly all mesotheliomas stain positive for cytokeratins and many also stain positive for calretinin.

uninvolved). Pleural effusions are common and frequently hemorrhagic. Mesotheliomas typically present with slowly progressive dyspnea, cough, chest pain, and weight loss. **Asbestos** exposure is the primary risk factor; individuals with occupational exposure (eg, mining, shipbuilding, insulation installation) are at increased risk.

Histologically, mesothelioma can appear as cuboidal or flattened cells (epithelium-like) or **spindle cells** (stromal-like). Immunohistochemistry is an important diagnostic marker; nearly all cases of mesothelioma will stain positive for **cytokeratins** and many will also typically stain positive for **calretinin**. Electron microscopy usually shows polygonal tumor cells with numerous long, slender microvilli and **abundant tonofilaments**.

(Choice A) Tuberculosis is characterized by caseating granulomas with giant cell formation; patients typically have hilar adenopathy and upper lobe infiltrates. Tuberculosis occurs most commonly in immunosuppressed patients or those at high exposure risk (eg, health care workers, incarcerated individuals).

(Choice B) Silicosis is associated with inhaled silica (eg, mining, sand blasting); histology demonstrates nodules composed of whorled collagen fibers and dust-laden macrophages. Imaging demonstrates innumerable upper lobe–predominant nodes within the pulmonary parenchyma.

(Choice C) Small cell lung cancer is characterized by small round cells; however, this malignancy typically arises in the central airways (not the pleura). Neuroendocrine markers, including chromogranin and synaptophysin, are typically positive.

(Choice E) Empyema—composed of a thick, fibrinous exudate and pus—typically occurs when bacteria infect the pleural space (typically from an associated pneumonia). Patients often present with fever, chills, and (occasionally) sepsis, not months of weight loss and dyspnea.

Educational objective:
Mesothelioma is a neoplasm arising from mesothelial cells and is strongly associated with asbestos exposure. In early mesothelioma, multiple nodules form on the parietal pleura and gradually encase the lung parenchyma. Immunohistochemistry is important for diagnosis; nearly all mesotheliomas stain positive for cytokeratins and many also stain positive for calretinin.

Pathophysiology	Pulmonary & Critical Care	Asbestos
Subject	System	Topic

Copyright © UWorld. All rights reserved.

A 33-year-old woman comes to the office due to worsening exertional dyspnea. She previously jogged frequently, but now becomes short of breath while walking her dog in the park. The patient has no other significant medical history and takes no medications. She smokes a pack of cigarettes daily and does not use alcohol or illicit drugs. Blood pressure is 124/76 mm Hg, pulse is 78/min, and respirations are 20/min. BMI is 27 kg/m^2. Cardiac examination is unremarkable. Laboratory studies reveal markedly decreased serum alpha-1 antitrypsin levels. Which of the following pulmonary function test patterns is most likely to be present in this patient?

	Forced expiratory volume in 1 second / Forced vital capacity	Total lung capacity	Diffusing capacity for carbon monoxide
A.	↓	↑	↑
B.	↓	↑	↓
C.	↓	↓	↓
D.	↓	↑	Normal
E.	Normal	↓	Normal
F.	Normal	↓	↓

Submit

A 33-year-old woman comes to the office due to worsening exertional dyspnea. She previously jogged frequently, but now becomes short of breath while walking her dog in the park. The patient has no other significant medical history and takes no medications. She smokes a pack of cigarettes daily and does not use alcohol or illicit drugs. Blood pressure is 124/76 mm Hg, pulse is 78/min, and respirations are 20/min. BMI is 27 kg/m^2. Cardiac examination is unremarkable. Laboratory studies reveal markedly decreased serum alpha-1 antitrypsin levels. Which of the following pulmonary function test patterns is most likely to be present in this patient?

	Forced expiratory volume in 1 second / Forced vital capacity	Total lung capacity	Diffusing capacity for carbon monoxide
A. (9%)	↓	↑	↑
✓ B. (58%)	↓	↑	↓
C. (5%)	↓	↓	↓
D. (21%)	↓	↑	Normal
E. (1%)	Normal	↓	Normal
F. (3%)	Normal	↓	↓

Omitted

Explanation

Pulmonary function test			
	Normal	**Obstructive lung disease**	**Restrictive lung disease (including obesity)**
FEV1	>80% (of predicted)	Decreased	Decreased
FEV1/FVC	>70%	Decreased	Normal to increased
FVC	>80% (of predicted)	Normal to decreased	Decreased

FEV1 = forced expiratory volume in 1 second; **FVC** = forced vital capacity.

This young woman with progressively worsening dyspnea, history of cigarette smoking, and decreased serum levels of alpha-1 antitrypsin (AAT) likely has **AAT deficiency** and associated **early-onset emphysema**. Emphysema from any cause leads to **increased total lung capacity** as the lungs hyperinflate, **decreased FEV1/FVC ratio**, and **decreased DLCO** (diffusing capacity for carbon monoxide) due to destruction of alveoli and adjoining capillary beds.

AAT is a protein that inhibits several proteolytic enzymes released by inflammatory cells (particularly neutrophil elastase), thereby reducing tissue damage from the inflammatory cascade. Even in the absence of smoking, patients with AAT deficiency typically develop early-onset emphysema (prior to age 50) due to the body's inability to inhibit tissue proteolysis. Cigarette smoking and the associated pulmonary inflammation that it induces can greatly accelerate the development of emphysema in these patients. The emphysema in AAT deficiency typically develops in a panacinar pattern.

(Choice A) Obstructive lung disease causes increased lung volumes (residual volume and total lung capacity) and decreased FEV1/FVC ratio,

FEV1 = forced expiratory volume in 1 second; **FVC** = forced vital capacity.

This young woman with progressively worsening dyspnea, history of cigarette smoking, and decreased serum levels of alpha-1 antitrypsin (AAT) likely has **AAT deficiency** and associated **early-onset emphysema**. Emphysema from any cause leads to **increased total lung capacity** as the lungs hyperinflate, **decreased FEV1/FVC ratio**, and **decreased DLCO** (diffusing capacity for carbon monoxide) due to destruction of alveoli and adjoining capillary beds.

AAT is a protein that inhibits several proteolytic enzymes released by inflammatory cells (particularly neutrophil elastase), thereby reducing tissue damage from the inflammatory cascade. Even in the absence of smoking, patients with AAT deficiency typically develop early-onset emphysema (prior to age 50) due to the body's inability to inhibit tissue proteolysis. Cigarette smoking and the associated pulmonary inflammation that it induces can greatly accelerate the development of emphysema in these patients. The emphysema in AAT deficiency typically develops in a panacinar pattern.

(Choice A) Obstructive lung disease causes increased lung volumes (residual volume and total lung capacity) and decreased FEV1/FVC ratio, but the DLCO can vary based on etiology. Asthma is an obstructive disease that can have high DLCO due to increased pulmonary capillary blood volume and intact alveolar-arterial membranes (lack of emphysematous destruction).

(Choice C) The pattern of decreased FEV1/FVC ratio, decreased lung volume, and decreased DLCO reflects combined restrictive and obstructive defects, which can be due to multiple diseases present simultaneously or diseases such as pneumoconiosis (eg, silicosis, asbestosis) and sarcoidosis.

(Choice D) Reduced FEV1/FVC ratio and normal DLCO may occur in asthma or in chronic bronchitis-predominant chronic obstructive pulmonary disease.

(Choices E and F) Restrictive lung disease can be categorized according to intrinsic (eg, interstitial lung disease) and extrinsic (eg, obesity, neuromuscular disease) etiologies, both of which demonstrate a pattern of reduced lung volumes with normal or increased FEV1/FVC ratio (although both the FEV1 and FVC are reduced individually). The DLCO helps distinguish between the 2 forms: Intrinsic restrictive lung disease demonstrates reduced DLCO, whereas extrinsic disease has normal DLCO.

Educational objective:

Emphysema most commonly results from chronic smoking but can also occur in genetically predisposed individuals with alpha-1 antitrypsin

FEV1 = forced expiratory volume in 1 second; FVC = forced vital capacity.

Exhibit Display

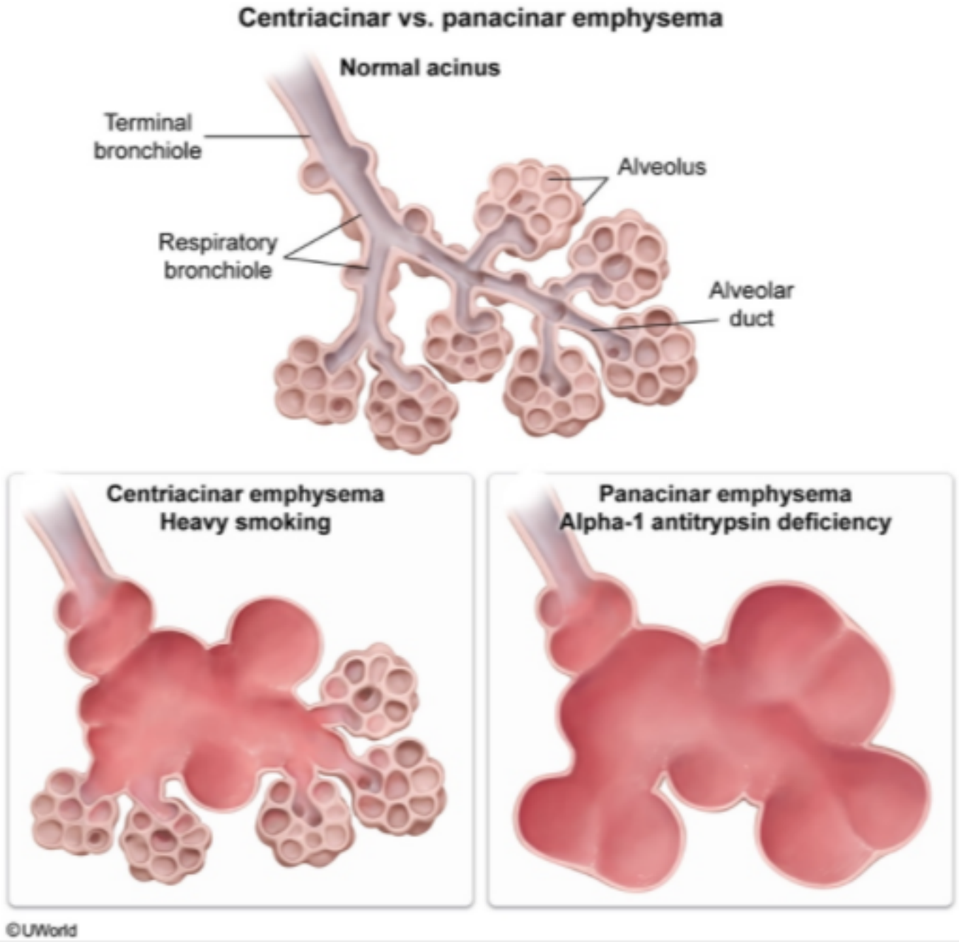

Zoom In | Zoom Out | Reset | Add To New Card | Existing Card

Emphysema most commonly results from chronic smoking but can also occur in genetically predisposed individuals with alpha-1 antitrypsin

panacinar pattern.

(Choice A) Obstructive lung disease causes increased lung volumes (residual volume and total lung capacity) and decreased FEV1/FVC ratio, but the DLCO can vary based on etiology. Asthma is an obstructive disease that can have high DLCO due to increased pulmonary capillary blood volume and intact alveolar-arterial membranes (lack of emphysematous destruction).

(Choice C) The pattern of decreased FEV1/FVC ratio, decreased lung volume, and decreased DLCO reflects combined restrictive and obstructive defects, which can be due to multiple diseases present simultaneously or diseases such as pneumoconiosis (eg, silicosis, asbestosis) and sarcoidosis.

(Choice D) Reduced FEV1/FVC ratio and normal DLCO may occur in asthma or in chronic bronchitis-predominant chronic obstructive pulmonary disease.

(Choices E and F) Restrictive lung disease can be categorized according to intrinsic (eg, interstitial lung disease) and extrinsic (eg, obesity, neuromuscular disease) etiologies, both of which demonstrate a pattern of reduced lung volumes with normal or increased FEV1/FVC ratio (although both the FEV1 and FVC are reduced individually). The DLCO helps distinguish between the 2 forms: Intrinsic restrictive lung disease demonstrates reduced DLCO, whereas extrinsic disease has normal DLCO.

Educational objective:
Emphysema most commonly results from chronic smoking but can also occur in genetically predisposed individuals with alpha-1 antitrypsin deficiency. Patients with emphysema have a decreased forced expiratory volume in 1 second/forced vital capacity ratio, increased total lung capacity, and decreased diffusing capacity.

References

- A stepwise approach to the interpretation of pulmonary function tests.

Pathophysiology	Pulmonary & Critical Care	Alpha1 antitrypsin deficiency
Subject	System	Topic

Copyright © UWorld. All rights reserved.

A 42-year-old man comes to his primary care physician due to daytime sleepiness. He often falls asleep during meetings and while watching television and has even fallen asleep while driving. The patient does not feel refreshed when waking and has occasional morning headaches. He has not had abnormal dreams or visual hallucinations when falling asleep or on waking. The patient has no significant past medical history and is a lifetime non-smoker. He drinks 2 or 3 beers on Friday nights. Blood pressure is 148/100 mm Hg and pulse is 78/min and regular; BMI is 32 kg/m^2. Cardiopulmonary examination shows no abnormalities. Arterial blood gas analysis is normal. What is this patient's most likely diagnosis?

- A. Central sleep apnea
- B. Narcolepsy
- C. Obesity hypoventilation syndrome
- D. Obstructive sleep apnea
- E. Primary insomnia
- F. Restless leg syndrome

Submit

A 42-year-old man comes to his primary care physician due to daytime sleepiness. He often falls asleep during meetings and while watching television and has even fallen asleep while driving. The patient does not feel refreshed when waking and has occasional morning headaches. He has not had abnormal dreams or visual hallucinations when falling asleep or on waking. The patient has no significant past medical history and is a lifetime non-smoker. He drinks 2 or 3 beers on Friday nights. Blood pressure is 148/100 mm Hg and pulse is 78/min and regular; BMI is 32 kg/m^2. Cardiopulmonary examination shows no abnormalities. Arterial blood gas analysis is normal. What is this patient's most likely diagnosis?

- A. Central sleep apnea (3%)
- B. Narcolepsy (14%)
- C. Obesity hypoventilation syndrome (8%)
- ✓ D. Obstructive sleep apnea (71%)
- E. Primary insomnia (2%)
- F. Restless leg syndrome (0%)

Omitted
Correct answer
D

71%
Answered correctly

02 secs
Time Spent

06/06/2020
Last Updated

Explanation

Obstructive sleep apnea	
[illegible]	• Relaxation of pharyngeal muscles, leading to closure of airway

Obstructive sleep apnea	
Pathophysiology	• Relaxation of pharyngeal muscles, leading to closure of airway • Loud snoring with periods of apnea
Symptoms	• Daytime somnolence • Nonrestorative sleep with frequent awakenings • Morning headaches • Affective & cognitive symptoms
Sequelae	• Systemic hypertension • Pulmonary hypertension & right-sided heart failure

This patient has several features that suggest **obstructive sleep apnea** (OSA), including daytime somnolence, nonrestorative sleep, and elevated blood pressure in the setting of underlying obesity. OSA is caused by closure of the upper airway due to **relaxation of pharyngeal muscle tone** during sleep. Additional contributing factors include **obesity**, tonsillar hypertrophy, and hypothyroidism. When the airway is occluded, PO_2 declines and PCO_2 rises until chemoreceptors in the carotid body and brainstem trigger arousal and pharyngeal tone returns. Sleep is repeatedly disrupted throughout the night, even in the absence of cortical awareness.

Typical symptoms include excessive daytime sleepiness, **morning headaches**, cognitive impairment, and depression. Most patients also experience loud **snoring** due to partial closure of the airway. Chronic OSA can lead to systemic and pulmonary hypertension with **right heart failure** and an increased risk for cardiac arrhythmias.

(Choice A) Central sleep apnea is due to diminished respiratory drive from a neurologic disorder. Symptoms may superficially resemble OSA, but it is usually associated with significant underlying chronic illness (eg, congestive heart failure, cerebrovascular disease, renal insufficiency) and is not more common in obesity.

(Choice B) Narcolepsy is characterized by poorly regulated rapid eye movement (REM) sleep. It frequently causes excessive daytime sleepiness, but patients also suffer from cataplexy, sleep attacks, hypnagogic/hypnopompic hallucinations, and sleep paralysis.

This patient has several features that suggest **obstructive sleep apnea** (OSA), including daytime somnolence, nonrestorative sleep, and elevated blood pressure in the setting of underlying obesity. OSA is caused by closure of the upper airway due to **relaxation of pharyngeal muscle tone** during sleep. Additional contributing factors include **obesity**, tonsillar hypertrophy, and hypothyroidism. When the airway is occluded, PO_2 declines and PCO_2 rises until chemoreceptors in the carotid body and brainstem trigger arousal and pharyngeal tone returns. Sleep is repeatedly disrupted throughout the night, even in the absence of cortical awareness.

Typical symptoms include excessive daytime sleepiness, **morning headaches**, cognitive impairment, and depression. Most patients also experience loud **snoring** due to partial closure of the airway. Chronic OSA can lead to systemic and pulmonary hypertension with **right heart failure** and an increased risk for cardiac arrhythmias.

(Choice A) Central sleep apnea is due to diminished respiratory drive from a neurologic disorder. Symptoms may superficially resemble OSA, but it is usually associated with significant underlying chronic illness (eg, congestive heart failure, cerebrovascular disease, renal insufficiency) and is not more common in obesity.

(Choice B) Narcolepsy is characterized by poorly regulated rapid eye movement (REM) sleep. It frequently causes excessive daytime sleepiness, but patients also suffer from cataplexy, sleep attacks, hypnagogic/hypnopompic hallucinations, and sleep paralysis.

(Choice C) Obesity hypoventilation syndrome (Pickwickian syndrome) is caused by restricted expansion of the chest wall due to severe obesity. This leads to hypoventilation with a chronically elevated PCO_2 and reduced PO_2. This patient's normal blood gases and mild obesity are not consistent with obesity hypoventilation.

(Choice E) Patients with simple insomnia may have daytime fatigue, but nonrestorative sleep, morning headaches, and elevated blood pressure suggest OSA.

(Choice F) Restless leg syndrome is characterized by vague discomfort in the limbs that is brought on when trying to sleep and relieved with movement. Symptoms may recur through the night and lead to nonrestorative sleep, but patients are usually aware of the symptoms.

Educational objective:
Obstructive sleep apnea is due to relaxation of oropharyngeal muscle tone with occlusion of the upper airway. Symptoms include daytime sleepiness, headaches, and depression. Complications include systemic and pulmonary hypertension, right heart failure, and an increased risk for

1 2 3 4 5 6 7 8 9 10 11 12 13 14 15 16 17 18 19 20 21 22 23 24 25 26 27 28 29 30

Exhibit Display

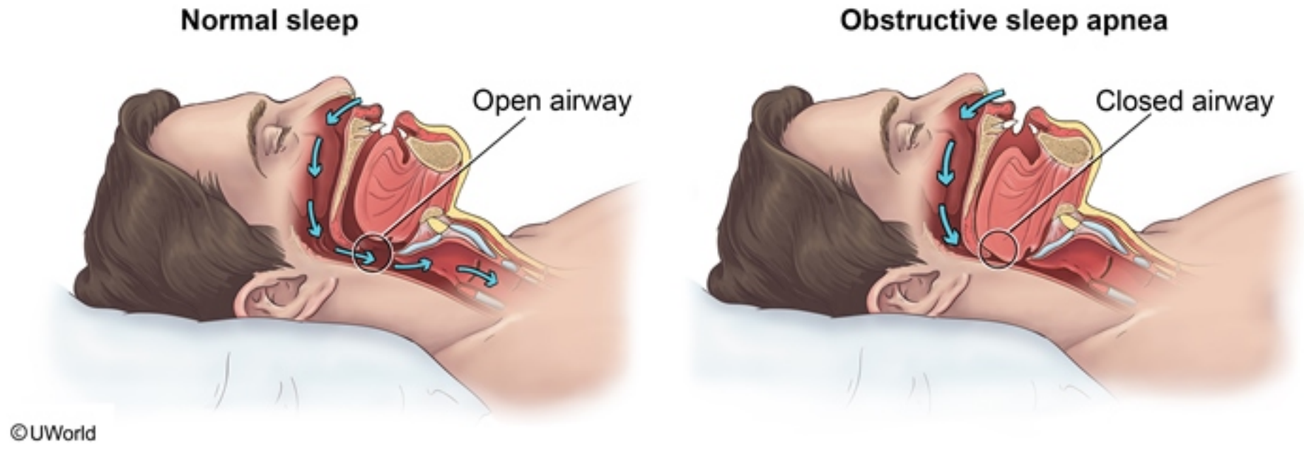

Zoom In | Zoom Out | Reset | Add To New Card | Existing Card

sleepiness, headaches, and depression. Complications include systemic and pulmonary hypertension, right heart failure, and an increased risk for

failure and an increased risk for cardiac arrhythmias.

(Choice A) Central sleep apnea is due to diminished respiratory drive from a neurologic disorder. Symptoms may superficially resemble OSA, but it is usually associated with significant underlying chronic illness (eg, congestive heart failure, cerebrovascular disease, renal insufficiency) and is not more common in obesity.

(Choice B) Narcolepsy is characterized by poorly regulated rapid eye movement (REM) sleep. It frequently causes excessive daytime sleepiness, but patients also suffer from cataplexy, sleep attacks, hypnagogic/hypnopompic hallucinations, and sleep paralysis.

(Choice C) Obesity hypoventilation syndrome (Pickwickian syndrome) is caused by restricted expansion of the chest wall due to severe obesity. This leads to hypoventilation with a chronically elevated PCO_2 and reduced PO_2. This patient's normal blood gases and mild obesity are not consistent with obesity hypoventilation.

(Choice E) Patients with simple insomnia may have daytime fatigue, but nonrestorative sleep, morning headaches, and elevated blood pressure suggest OSA.

(Choice F) Restless leg syndrome is characterized by vague discomfort in the limbs that is brought on when trying to sleep and relieved with movement. Symptoms may recur through the night and lead to nonrestorative sleep, but patients are usually aware of the symptoms.

Educational objective:
Obstructive sleep apnea is due to relaxation of oropharyngeal muscle tone with occlusion of the upper airway. Symptoms include daytime sleepiness, headaches, and depression. Complications include systemic and pulmonary hypertension, right heart failure, and an increased risk for cardiac events.

References

- Pathophysiology of obstructive sleep apnea.

Pathophysiology	Pulmonary & Critical Care	Obstructive sleep apnea
Subject	System	Topic

Copyright © UWorld. All rights reserved.

A 37-year-old woman is evaluated for exertional shortness of breath. The patient has had progressive dyspnea for the last year and for the last 2 months has been unable to walk half a block without stopping to rest. She also describes lightheadedness during exertion. Medical history is insignificant, and vital signs are within normal limits. BMI is 23 kg/m^2. Physical examination reveals a 2/6 holosystolic murmur at the lower sternal border, which increases with inspiration. Further evaluation indicates no evidence of obstructive or interstitial lung disease or venous thromboembolism. Cardiac catheterization results are as follows:

Mean pulmonary artery pressure	43 mm Hg (normal: 8-20)
Pulmonary capillary wedge pressure	9 mm Hg (normal: 6-12)

Pharmacotherapy blocking the effects of which of the following substances is most likely to benefit this patient?

A. Aldosterone
B. Angiotensin II
C. Endothelin
D. Norepinephrine
E. Serotonin

Submit

A 37-year-old woman is evaluated for exertional shortness of breath. The patient has had progressive dyspnea for the last year and for the last 2 months has been unable to walk half a block without stopping to rest. She also describes lightheadedness during exertion. Medical history is insignificant, and vital signs are within normal limits. BMI is 23 kg/m^2. Physical examination reveals a 2/6 holosystolic murmur at the lower sternal border, which increases with inspiration. Further evaluation indicates no evidence of obstructive or interstitial lung disease or venous thromboembolism. Cardiac catheterization results are as follows:

Mean pulmonary artery pressure	43 mm Hg (normal: 8-20)
Pulmonary capillary wedge pressure	9 mm Hg (normal: 6-12)

Pharmacotherapy blocking the effects of which of the following substances is most likely to benefit this patient?

A. Aldosterone (5%)
B. Angiotensin II (18%)
✓ C. Endothelin (69%)
D. Norepinephrine (4%)
E. Serotonin (1%)

Omitted
Correct answer
C

69%
Answered correctly

02 secs
Time Spent

03/23/2020
Last Updated

Explanation

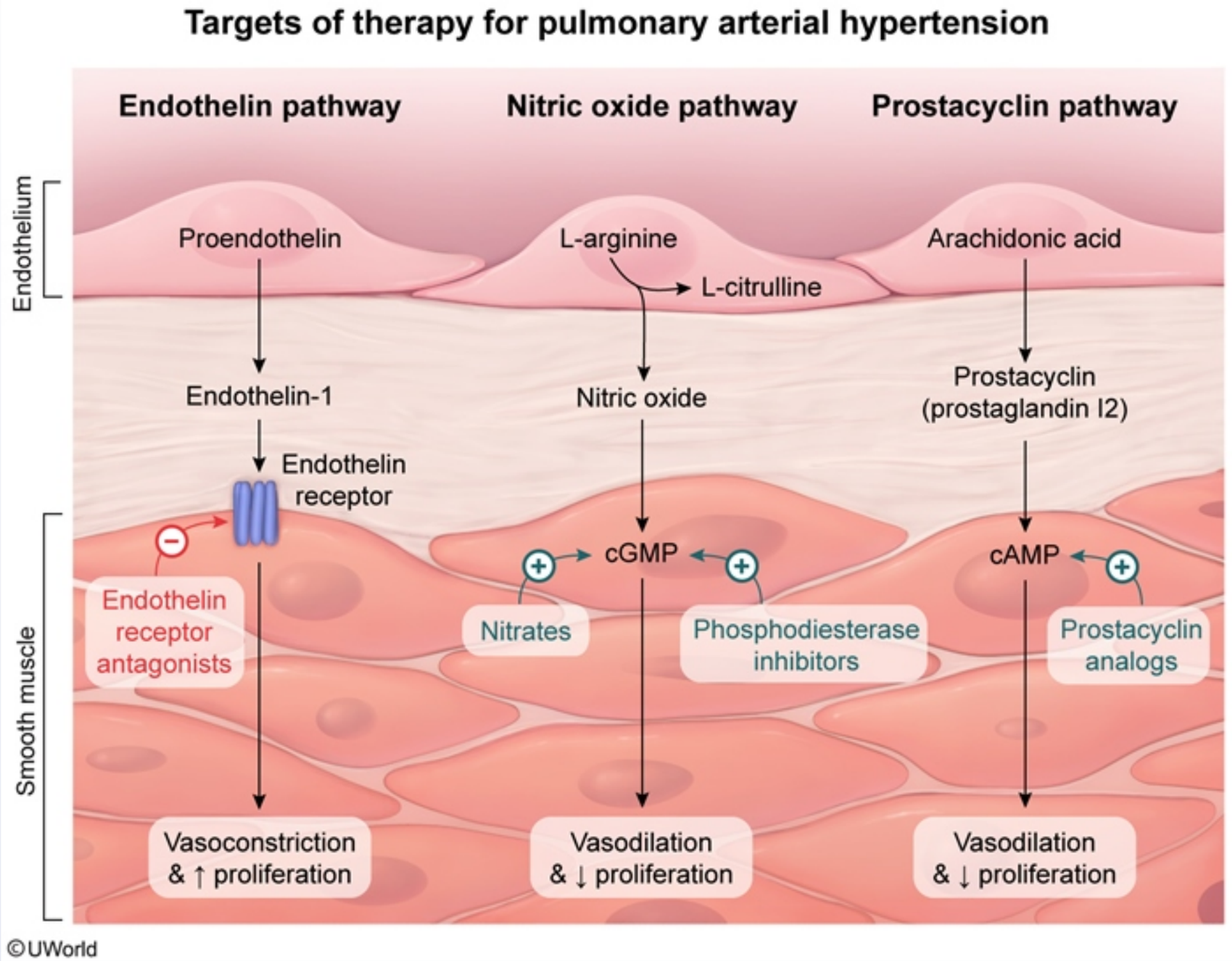

This patient has **pulmonary hypertension**, which typically presents with progressive dyspnea and fatigue, sometimes with associated chest pain and exertional lightheadedness or syncope. Due to right ventricular enlargement, a holosystolic murmur of functional **tricuspid regurgitation** is often present.

This patient has **pulmonary hypertension**, which typically presents with progressive dyspnea and fatigue, sometimes with associated chest pain and exertional lightheadedness or syncope. Due to right ventricular enlargement, a holosystolic murmur of functional **tricuspid regurgitation** is often present.

Pulmonary hypertension can occur due to a primary change in the pulmonary arteries or it can be secondary to a separate disease process; secondary causes include left-sided heart failure (ruled out by pulmonary capillary wedge pressure ≤12 mm Hg), chronic lung hypoxia (eg, interstitial lung disease), and chronic pulmonary thromboembolic disease. Pulmonary hypertension due to a primary change in the pulmonary arteries, termed **pulmonary arterial hypertension** (PAH), results from **proliferative vasculopathy** of the pulmonary arteriolar smooth muscle, which may occur in the setting of hereditary genetic mutation (**BMPR2 mutation** is most common), connective tissue disease, or HIV infection.

Endothelin is a potent **vasoconstrictor** that also promotes **smooth muscle cell proliferation**; it is typically found in high concentrations in patients with PAH and it is an important target of therapy for the disease. **Endothelin receptor antagonists** (eg, bosentan, ambrisentan) inhibit pulmonary arteriolar smooth muscle proliferation and alleviate vasoconstriction to lower pulmonary arterial pressure and improve dyspnea in patients with PAH.

(Choices A, B, and D) Aldosterone (mineralocorticoid) receptor antagonists (eg, spironolactone), angiotensin II receptor blockers (eg, losartan), and beta blockers (antagonists of the beta-1 adrenergic receptors that norepinephrine stimulates, eg, metoprolol) help prevent cardiac remodeling in patients with left ventricular systolic dysfunction. These drugs can be used to treat pulmonary hypertension that develops secondary to left-sided heart failure; however, they are not used for PAH as a direct effect on pulmonary vascular remodeling has not been established.

(Choice E) In carcinoid syndrome, high circulating levels of serotonin may cause deposition of fibrous tissue on the right-sided heart valves, typically leading to tricuspid regurgitation and/or pulmonic stenosis. Agents that block the effects of serotonin (eg, octreotide) can be helpful in treating carcinoid syndrome; however, carcinoid syndrome would not explain the elevated pulmonary arterial pressure in this patient. The role of serotonin in PAH has not been well-defined.

Educational objective:
Pulmonary hypertension can occur due to a primary change in the pulmonary arteries (ie, pulmonary arterial hypertension) or it can be secondary to a separate disease process such as left-sided heart failure (ruled out by normal pulmonary capillary wedge pressure). Endothelin receptor antagonists (eg, bosentan, ambrisentan) lower pulmonary arterial pressure and improve dyspnea in patients with pulmonary arterial hypertension.

This patient has **pulmonary hypertension**, which typically presents with progressive dyspnea and fatigue, sometimes with associated chest pain and exertional lightheaded is often present.

Pulmonary hypertension c secondary causes include interstitial lung disease), a arteries, termed **pulmona** which may occur in the se

Endothelin is a potent **va** patients with PAH and it is pulmonary arteriolar smoc patients with PAH.

(Choices A, B, and D) A and beta blockers (antago in patients with left ventric sided heart failure; howev

(Choice E) In carcinoid s typically leading to tricusp treating carcinoid syndron serotonin in PAH has not

Educational objective: Pulmonary hypertension c to a separate disease pro antagonists (eg, bosentan, ambrisentan) lower pulmonary arterial pressure and improve dyspnea in patients with pulmonary arterial hypertension.

Exhibit Display

Classification of pulmonary hypertension	
Pulmonary arterial hypertension (Group 1)	• Primary change in pulmonary arteries ◦ Hereditary (eg, *BMPR2* mutation) ◦ Connective tissue disease (eg, RA, SS) ◦ HIV infection • Treatment targeted at endothelial dysfunction
Pulmonary hypertension (Groups 2-5)	• Secondary to another disease process ◦ Left-sided heart failure ◦ Chronic lung disease/hypoxia ◦ Chronic pulmonary thromboembolism • Treatment aimed at underlying disease

RA = rheumatoid arthritis; **SS** = systemic sclerosis.

Add To New Card | Existing Card

Endothelin is a potent **vasoconstrictor** that also promotes **smooth muscle cell proliferation**; it is typically found in high concentrations in patients with PAH and it is an important target of therapy for the disease. **Endothelin receptor antagonists** (eg, bosentan, ambrisentan) inhibit pulmonary arteriolar smooth muscle proliferation and alleviate vasoconstriction to lower pulmonary arterial pressure and improve dyspnea in patients with PAH.

(Choices A, B, and D) Aldosterone (mineralocorticoid) receptor antagonists (eg, spironolactone), angiotensin II receptor blockers (eg, losartan), and beta blockers (antagonists of the beta-1 adrenergic receptors that norepinephrine stimulates, eg, metoprolol) help prevent cardiac remodeling in patients with left ventricular systolic dysfunction. These drugs can be used to treat pulmonary hypertension that develops secondary to left-sided heart failure; however, they are not used for PAH as a direct effect on pulmonary vascular remodeling has not been established.

(Choice E) In carcinoid syndrome, high circulating levels of serotonin may cause deposition of fibrous tissue on the right-sided heart valves, typically leading to tricuspid regurgitation and/or pulmonic stenosis. Agents that block the effects of serotonin (eg, octreotide) can be helpful in treating carcinoid syndrome; however, carcinoid syndrome would not explain the elevated pulmonary arterial pressure in this patient. The role of serotonin in PAH has not been well-defined.

Educational objective:
Pulmonary hypertension can occur due to a primary change in the pulmonary arteries (ie, pulmonary arterial hypertension) or it can be secondary to a separate disease process such as left-sided heart failure (ruled out by normal pulmonary capillary wedge pressure). Endothelin receptor antagonists (eg, bosentan, ambrisentan) lower pulmonary arterial pressure and improve dyspnea in patients with pulmonary arterial hypertension.

References

- Endothelin receptor antagonists for pulmonary arterial hypertension.
- The changing landscape of pulmonary arterial hypertension and implications for patient care.

Pathophysiology	Pulmonary & Critical Care	Pulmonary Arterial Hypertension
Subject	System	Topic

Copyright © UWorld. All rights reserved.

A 68-year-old man comes to the emergency department due to cough, breathlessness, and chest pain. The patient has a medical history of hypertension and type 2 diabetes mellitus. He is a former smoker with a 20-pack-year history. Temperature is 38 C (100.4 F), blood pressure is 130/80 mm Hg, respirations are 22/min, and oxygen saturation is 95% while breathing ambient air. The trachea is central in position. There is dullness to percussion over the lower right lung area compared to the resonancy on the left. Auscultation of the right lower lobe reveals breath sounds that are loud, hollow, and high-pitched. When the patient recites the word "ninety-nine" in a normal voice, the sound has higher clarity and intensity over the right base compared to other lung areas. Which of the following is the most likely cause of these findings?

A. Accumulation of interstitial fluid within the pleural space

B. Embolic occlusion of a pulmonary segmental artery

C. Exudation of neutrophil-rich fluid in the lung parenchyma

D. Leakage of air from spontaneous rupture of visceral pleura

E. Lung collapse due to a mass causing bronchial obstruction

F. Transudation of interstitial fluid within the alveolar spaces

Submit

A 68-year-old man comes to the emergency department due to cough, breathlessness, and chest pain. The patient has a medical history of hypertension and type 2 diabetes mellitus. He is a former smoker with a 20-pack-year history. Temperature is 38 C (100.4 F), blood pressure is 130/80 mm Hg, respirations are 22/min, and oxygen saturation is 95% while breathing ambient air. The trachea is central in position. There is dullness to percussion over the lower right lung area compared to the resonancy on the left. Auscultation of the right lower lobe reveals breath sounds that are loud, hollow, and high-pitched. When the patient recites the word "ninety-nine" in a normal voice, the sound has higher clarity and intensity over the right base compared to other lung areas. Which of the following is the most likely cause of these findings?

- A. Accumulation of interstitial fluid within the pleural space (12%)
- B. Embolic occlusion of a pulmonary segmental artery (2%)
- ✓ C. Exudation of neutrophil-rich fluid in the lung parenchyma (58%)
- D. Leakage of air from spontaneous rupture of visceral pleura (7%)
- E. Lung collapse due to a mass causing bronchial obstruction (5%)
- F. Transudation of interstitial fluid within the alveolar spaces (14%)

Omitted
Correct answer
C

58%
Answered correctly

02 secs
Time Spent

02/12/2020
Last Updated

Explanation

Pulmonary auscultation examination findings

Pulmonary auscultation examination findings			
Condition	**Breath sounds**	**Tactile fremitus**	**Percussion**
Normal lung	Normal	Normal	Resonance
Consolidation	Increased	Increased	Dullness
Pleural effusion	Decreased or absent	Decreased	Dullness
Pneumothorax	Decreased or absent	Decreased	Hyperresonance
Atelectasis	Decreased or absent	Decreased	Dullness

This patient's presentation is consistent with **bacterial pneumonia**. The infection causes the alveoli to fill with inflammatory, neutrophil-rich exudate (pus); alveolar filling with any kind of fluid (eg, pus, edema, blood) creates **alveolar consolidation**.

Alveolar consolidation leads to a number of characteristic physical examination findings. Sound travels faster and more efficiently through liquids than gases; therefore, fluid-filled alveoli transmit higher intensity sound than those filled with air. As a result, **breath sounds** and **tactile fremitus** (vibration) are **more prominent** over areas of alveolar consolidation. **Bronchophony**, a phenomenon in which a patient's spoken words (eg, "ninety-nine," "toy boat") are **heard more loudly and clearly** when auscultated over an area of consolidation compared to normal lung, is also present. The higher density of fluid-filled alveoli also creates relative **dullness to percussion** compared to the resonant sound created on percussion of air-filled alveoli.

(Choice A) Accumulation of interstitial fluid within the pleural space (pleural effusion) insulates breath sounds and vibrations that originate in the airways of the lungs. Consequently, tactile fremitus and breath sound intensity are decreased. The fluid in the chest cavity creates dullness to percussion over the affected area.

(Choice B) Pulmonary embolism typically has minimal effect on physical examination findings for the lungs.

(Choice D) As in pleural effusion, accumulation of air in the pleural space (pneumothorax) insulates sounds and vibrations that originate in the

Alveolar consolidation leads to a number of characteristic physical examination findings. Sound travels faster and more efficiently through liquids than gases; therefore, fluid-filled alveoli transmit higher intensity sound than those filled with air. As a result, **breath sounds** and **tactile fremitus** (vibration) are **more prominent** over areas of alveolar consolidation. **Bronchophony**, a phenomenon in which a patient's spoken words (eg, "ninety-nine," "toy boat") are **heard more loudly and clearly** when auscultated over an area of consolidation compared to normal lung, is also present. The higher density of fluid-filled alveoli also creates relative **dullness to percussion** compared to the resonant sound created on percussion of air-filled alveoli.

(Choice A) Accumulation of interstitial fluid within the pleural space (pleural effusion) insulates breath sounds and vibrations that originate in the airways of the lungs. Consequently, tactile fremitus and breath sound intensity are decreased. The fluid in the chest cavity creates dullness to percussion over the affected area.

(Choice B) Pulmonary embolism typically has minimal effect on physical examination findings for the lungs.

(Choice D) As in pleural effusion, accumulation of air in the pleural space (pneumothorax) insulates sounds and vibrations that originate in the lungs, and breath sound intensity and tactile fremitus are decreased. In contrast to pleural effusion, the relatively low density of the air in the pleural space creates hyperresonance to percussion.

(Choice E) A mass in a proximal bronchial airway (eg, malignancy, mucus plug) can cause airway obstruction and consequent collapse (atelectasis) of distal alveoli. Breath sounds and tactile fremitus are decreased, and dullness to percussion is created due to the absence of air.

(Choice F) Transudation of interstitial fluid into the alveoli occurs in heart failure and can create alveolar consolidation with physical examination findings similar to bacterial pneumonia. However, in heart failure the findings are typically similar bilaterally. Pneumonia, with accumulation of inflammatory exudate, is more likely in this patient with low-grade fever and evidence of unilateral alveolar consolidation.

Educational objective:
Alveolar consolidation occurs when the alveoli become filled with fluid (eg, inflammatory exudate in bacterial pneumonia). The increased compactness of the alveolar fluid (compared to air) causes sound to travel faster and more efficiently, resulting in bronchophony, increased tactile fremitus (vibration), and increased intensity of breath sounds over the affected area. Dullness to percussion is also present.

Pathophysiology Pulmonary & Critical Care Community acquired pneumonia

"ninety-nine," "toy boat") are **heard more loudly and clearly** when auscultated over an area of consolidation compared to normal lung, is also present. The higher density of fluid-filled alveoli also creates relative **dullness to percussion** compared to the resonant sound created on percussion of air-filled alveoli.

(Choice A) Accumulation of interstitial fluid within the pleural space (pleural effusion) insulates breath sounds and vibrations that originate in the airways of the lungs. Consequently, tactile fremitus and breath sound intensity are decreased. The fluid in the chest cavity creates dullness to percussion over the affected area.

(Choice B) Pulmonary embolism typically has minimal effect on physical examination findings for the lungs.

(Choice D) As in pleural effusion, accumulation of air in the pleural space (pneumothorax) insulates sounds and vibrations that originate in the lungs, and breath sound intensity and tactile fremitus are decreased. In contrast to pleural effusion, the relatively low density of the air in the pleural space creates hyperresonance to percussion.

(Choice E) A mass in a proximal bronchial airway (eg, malignancy, mucus plug) can cause airway obstruction and consequent collapse (atelectasis) of distal alveoli. Breath sounds and tactile fremitus are decreased, and dullness to percussion is created due to the absence of air.

(Choice F) Transudation of interstitial fluid into the alveoli occurs in heart failure and can create alveolar consolidation with physical examination findings similar to bacterial pneumonia. However, in heart failure the findings are typically similar bilaterally. Pneumonia, with accumulation of inflammatory exudate, is more likely in this patient with low-grade fever and evidence of unilateral alveolar consolidation.

Educational objective:
Alveolar consolidation occurs when the alveoli become filled with fluid (eg, inflammatory exudate in bacterial pneumonia). The increased compactness of the alveolar fluid (compared to air) causes sound to travel faster and more efficiently, resulting in bronchophony, increased tactile fremitus (vibration), and increased intensity of breath sounds over the affected area. Dullness to percussion is also present.

Pathophysiology	Pulmonary & Critical Care	Community acquired pneumonia
Subject	System	Topic

Copyright © UWorld. All rights reserved.

A 63-year-old man comes to the office due to 3 months of increasing cough with occasional hemoptysis, night sweats, and unintentional weight loss. The patient recently emigrated from South Africa, where he had worked for many years in the gold mines. He has a history of silicosis that was diagnosed 10 years ago. Vital signs show a low-grade fever. Physical examination reveals diffuse, fine crackles with right upper lobe predominance. Chest x-ray shows diffuse, small nodules; hilar adenopathy with prominent calcifications; and a cavitary lung lesion in the right upper lobe. A sputum sample is sent for appropriate staining and culture. This patient's increased susceptibility to the current infection is best explained by which of the following factors?

A. Extensive pulmonary fibrosis

B. Impaired immunoglobulin G response

C. Impaired macrophage function

D. Impaired type 2 helper T cell function

E. Ineffective mucociliary clearance

Submit

1 2 3 4 5 6 7 8 9 10 11 12 13 14 15 16 17 18 19 20 21 22 23 24 25 26 27 28 29 30

A 63-year-old man comes to the office due to 3 months of increasing cough with occasional hemoptysis, night sweats, and unintentional weight loss. The patient recently emigrated from South Africa, where he had worked for many years in the gold mines. He has a history of silicosis that was diagnosed 10 years ago. Vital signs show a low-grade fever. Physical examination reveals diffuse, fine crackles with right upper lobe predominance. Chest x-ray shows diffuse, small nodules; hilar adenopathy with prominent calcifications; and a cavitary lung lesion in the right upper lobe. A sputum sample is sent for appropriate staining and culture. This patient's increased susceptibility to the current infection is best explained by which of the following factors?

A. Extensive pulmonary fibrosis (15%)

B. Impaired immunoglobulin G response (0%)

✓ C. Impaired macrophage function (68%)

D. Impaired type 2 helper T cell function (7%)

E. Ineffective mucociliary clearance (7%)

Omitted
Correct answer
C

68%
Answered correctly

02 secs
Time Spent

05/03/2020
Last Updated

Explanation

This patient with a history of silicosis has developed hemoptysis, night sweats, weight loss, and a cavitary lung lesion in the upper lobe; this is highly suggestive of tuberculosis infection. **Silicosis** is an occupational lung disease that occurs after inhalation of crystalline silica and is characterized by multiple rounded nodules located in the upper lobes. Patients may also develop calcification of the rim of hilar lymph nodes (eggshell calcification).

This patient with a history of silicosis has developed hemoptysis, night sweats, weight loss, and a cavitary lung lesion in the upper lobe; this is highly suggestive of tuberculosis infection. **Silicosis** is an occupational lung disease that occurs after inhalation of crystalline silica and is characterized by multiple rounded nodules located in the upper lobes. Patients may also develop calcification of the rim of hilar lymph nodes (eggshell calcification).

Silicosis is associated with increased risk of mycobacterial infections, particularly ***Mycobacterium tuberculosis***, due to **impaired macrophage function**. It is thought that macrophage phagolysosomes are disrupted by internalized silica particles, leading to impaired phagocytosis and increased apoptosis.

(Choice A) Although interstitial fibrosis can be caused by silicosis, fibrosis alone would not greatly predispose to mycobacterial infection. In fact, scarred areas of lung would be less accessible and may limit spread of microbial pathogens.

(Choices B and D) Th2 cells are important for mediating humoral immunity and combating parasitic infections. However, humoral immunity does not play a major role in eliminating mycobacterial infections due to the intracellular survivability of these pathogens.

(Choice E) Impaired mucociliary clearance, which occurs in patients with cystic fibrosis, can result in recurrent pulmonary infections due to impaired pathogen clearance. However, mucociliary clearance is not directly impaired by silicosis.

Educational objective:
In silicosis, internalized silica particles impair macrophage function by disrupting phagocytosis and promoting apoptosis. This increases the risk of mycobacteria infection (particularly *M tuberculosis*).

References

- Silicosis.

Pathophysiology	Pulmonary & Critical Care	Silicosis
Subject	System	Topic

Copyright © UWorld. All rights reserved.

A 54-year-old man comes to the office due to daytime sleepiness and lack of energy. The symptoms began 6 months ago and have progressively worsened so that he feels "completely drained" by the end of the day. The patient's wife mentions that he snores loudly. His past medical history is unremarkable, although he has not seen a physician in over 10 years. The patient does not use tobacco or alcohol, and he works in the warehouse of an agricultural supply company. BMI is 34 kg/m^2. Physical examination shows a narrow oropharynx and a large neck circumference. The patient is at increased risk of developing which of the following?

A. Bronchiectasis

B. Hypertrophic cardiomyopathy

C. Laryngeal carcinoma

D. Narcolepsy

E. Pulmonary hypertension

Submit

A 54-year-old man comes to the office due to daytime sleepiness and lack of energy. The symptoms began 6 months ago and have progressively worsened so that he feels "completely drained" by the end of the day. The patient's wife mentions that he snores loudly. His past medical history is unremarkable, although he has not seen a physician in over 10 years. The patient does not use tobacco or alcohol, and he works in the warehouse of an agricultural supply company. BMI is 34 kg/m^2. Physical examination shows a narrow oropharynx and a large neck circumference. The patient is at increased risk of developing which of the following?

- A. Bronchiectasis (6%)
- B. Hypertrophic cardiomyopathy (9%)
- C. Laryngeal carcinoma (3%)
- D. Narcolepsy (7%)
- ✓ E. Pulmonary hypertension (73%)

Omitted
Correct answer
E

73%
Answered correctly

01 sec
Time Spent

01/28/2020
Last Updated

Explanation

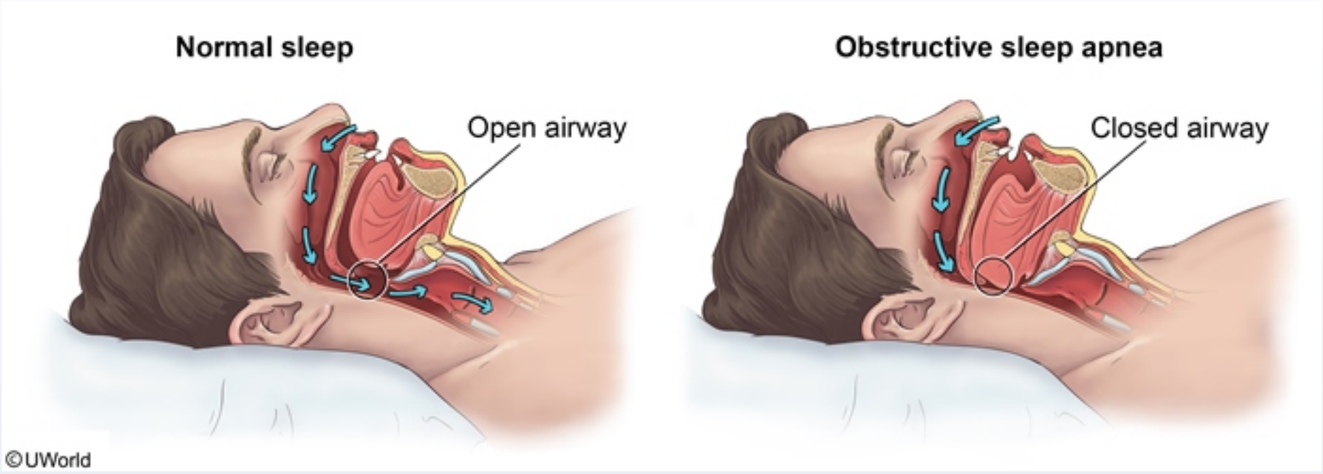

This patient, an obese man with loud snoring, daytime sleepiness, and suggestive examination findings (eg, thick neck, narrow airway) most likely has **obstructive sleep apnea** (OSA). OSA is characterized by recurrent obstruction of the upper airway during sleep; each nocturnal episode of reduced ventilation causes transient **hypercapnia** and **hypoxemia**. These blood gas derangements result in reflexive systemic and pulmonary **vasoconstriction**, endothelial dysfunction, abnormal venous return and cardiac output, and **sympathetic** cardiac stimulation.

Prolonged, untreated OSA can cause **pulmonary hypertension** and right heart failure. Most patients with OSA will develop **systemic hypertension** due to chronic sympathetic stimulation and elevated plasma norepinephrine levels. Patients also lose the normal diurnal variation in blood pressure. Other cardiovascular complications of OSA include atrial fibrillation and other arrhythmias, coronary artery disease, and increased risk of sudden cardiac death.

(Choice A) Acquired bronchiectasis may be seen in patients with recurrent infection, impaired drainage (eg, cystic fibrosis), airway obstruction (eg, foreign body aspiration), or inadequate host defense (eg, hypogammaglobulinemia).

(Choice B) Systemic hypertension, as seen in OSA, can lead to mild-to-moderate left ventricular hypertrophy and impaired systolic and diastolic function. In contrast, hypertrophic cardiomyopathy is an autosomal dominant disease of the cardiac sarcomere characterized by severe myocardial hypertrophy. It is not associated with hypertension or OSA.

(Choice C) Laryngeal carcinoma is associated with cigarette smoking and heavy alcohol use.

vasoconstriction, endothelial dysfunction, abnormal venous return and cardiac output, and sympathetic cardiac stimulation.

Prolonged, untreated OSA can cause **pulmonary hypertension** and right heart failure. Most patients with OSA will develop **systemic hypertension** due to chronic sympathetic stimulation and elevated plasma norepinephrine levels. Patients also lose the normal diurnal variation in blood pressure. Other cardiovascular complications of OSA include atrial fibrillation and other arrhythmias, coronary artery disease, and increased risk of sudden cardiac death.

(Choice A) Acquired bronchiectasis may be seen in patients with recurrent infection, impaired drainage (eg, cystic fibrosis), airway obstruction (eg, foreign body aspiration), or inadequate host defense (eg, hypogammaglobulinemia).

(Choice B) Systemic hypertension, as seen in OSA, can lead to mild-to-moderate left ventricular hypertrophy and impaired systolic and diastolic function. In contrast, hypertrophic cardiomyopathy is an autosomal dominant disease of the cardiac sarcomere characterized by severe myocardial hypertrophy. It is not associated with hypertension or OSA.

(Choice C) Laryngeal carcinoma is associated with cigarette smoking and heavy alcohol use.

(Choice D) Like OSA, narcolepsy can also cause daytime drowsiness. However, narcolepsy is also associated with cataplexy (sudden loss of muscle tone), sleep attacks, sleep paralysis, and hypnagogic hallucinations. OSA is not a risk factor for narcolepsy.

Educational objective:
Obstructive sleep apnea presents in obese individuals with excessive daytime sleepiness and signs of nocturnal upper airway obstruction (eg, snoring, gasping). The condition is associated with systemic hypertension. Prolonged, untreated obstructive sleep apnea can also cause pulmonary hypertension and right heart failure.

References

- Clinical perspective of obstructive sleep apnea-induced cardiovascular complications.

Pathophysiology	Pulmonary & Critical Care	Obstructive sleep apnea
Subject	System	Topic

Copyright © UWorld. All rights reserved.

A 54-year-old man comes to the emergency department due to fevers, shaking chills, and cough productive of copious sputum. He began having fever, cough, and sharp chest pains 10 days ago and was prescribed oral antibiotics by his primary care physician after a chest x-ray revealed a right lower lobe infiltrate. The patient has not been taking the medication as advised, and his symptoms have progressively worsened. Temperature is 39 C (102.2 F), blood pressure is 114/62 mm Hg, and pulse is 116/min. Physical examination reveals crackles in the right lower lung. Repeat chest x-ray reveals a round density with an air-fluid level in the lower lobe of the right lung. Which of the following is the most important contributor to the observed lung lesion in this patient?

A. Interferon-gamma production by CD4 lymphocytes

B. Interleukin-12 secretion by dendritic cells

C. Lysosomal content release by neutrophils

D. Major basic protein release by eosinophils

E. Transforming growth factor-beta secretion by macrophages

Submit

A 54-year-old man comes to the emergency department due to fevers, shaking chills, and cough productive of copious sputum. He began having fever, cough, and sharp chest pains 10 days ago and was prescribed oral antibiotics by his primary care physician after a chest x-ray revealed a right lower lobe infiltrate. The patient has not been taking the medication as advised, and his symptoms have progressively worsened. Temperature is 39 C (102.2 F), blood pressure is 114/62 mm Hg, and pulse is 116/min. Physical examination reveals crackles in the right lower lung. Repeat chest x-ray reveals a round density with an air-fluid level in the lower lobe of the right lung. Which of the following is the most important contributor to the observed lung lesion in this patient?

- A. Interferon-gamma production by CD4 lymphocytes (30%)
- B. Interleukin-12 secretion by dendritic cells (3%)
- ✓ C. Lysosomal content release by neutrophils (47%)
- D. Major basic protein release by eosinophils (2%)
- E. Transforming growth factor-beta secretion by macrophages (16%)

Omitted
Correct answer
C

47%
Answered correctly

01 sec
Time Spent

03/22/2020
Last Updated

Explanation

Lung abscess is a necrotic infection of the pulmonary parenchyma that usually presents with several days of fever, cough productive of **copious sputum** (often foul-smelling), and chest x-ray evidence of cavitation with air-fluid level. Most cases are due to aspiration of anaerobic bacteria from the oropharynx, but lung abscess can also develop in the setting of untreated pneumonia.

A 54-year-old man comes to the emergency department due to fevers, shaking chills, and cough productive of copious sputum. He began having fever, cough, and sharp chest pains 10 days ago and was prescribed oral antibiotics by his primary care physician after a chest x-ray revealed a right lower lobe infiltrate. The patient has not been taking the medication as advised, and his symptoms have progressively worsened. Temperature is 39 C (102.2 F), blood pressure is 114/62 mm Hg, and pulse is 116/min. Physical examination reveals crackles in the right lower lung. Repeat chest x-ray reveals a round density with an air-fluid level in the lower lobe of the right lung. Which of the following is the most important contributor to the observed lung lesion in this patient?

- A. Interferon-gamma production by CD4 lymphocytes (30%)
- B. Interleukin-12 secretion by dendritic cells (3%)
- ✓ C. Lysosomal content release by neutrophils (47%)
- D. Major basic protein release by eosinophils (2%)
- E. Transforming growth factor-beta secretion by macrophages (16%)

Omitted
Correct answer
C

47%
Answered correctly

01 sec
Time Spent

03/22/2020
Last Updated

Explanation

Lung abscess is a necrotic infection of the pulmonary parenchyma that usually presents with several days of fever, cough productive of **copious sputum** (often foul-smelling), and chest x-ray evidence of cavitation with air-fluid level. Most cases are due to aspiration of anaerobic bacteria from the oropharynx, but lung abscess can also develop in the setting of untreated pneumonia.

Lung abscess is a necrotic infection of the pulmonary parenchyma that usually presents with several days of fever, cough productive of **copious sputum** (often foul-smelling), and chest x-ray evidence of cavitation with air-fluid level. Most cases are due to aspiration of anaerobic bacteria from the oropharynx, but lung abscess can also develop in the setting of untreated pneumonia.

Neutrophils are the key player in the formation of lung abscess. They are recruited from the systemic circulation by chemokines and are subsequently activated by microbial molecules (eg, lipopolysaccharide, peptidoglycan, bacterial DNA) and opsonizing factors (eg, IgG, complement) to phagocytize and destroy the pathogenic bacteria. Activated neutrophils also **release cytotoxic granules** (lysosomes) containing myeloperoxidase and other digestive enzymes that destroy extracellular bacteria and recruit additional immune components to the area. However, these enzymes also cause significant damage to the pulmonary parenchyma and can result in **liquefying necrosis** of lung tissue and (potentially) lung abscess.

(Choices A and B) Dendritic and other antigen-presenting cells release interleukin-12, which stimulates differentiation of Th1 helper cells and production of interferon-gamma by T-cells. Interferon-gamma activates macrophages, leading to the development of mature phagolysosomes capable of destroying phagocytosed bacteria. Macrophages are particularly important for the elimination of certain intracellular infections such as *Mycobacterium tuberculosis*. Although tuberculosis can be associated with pulmonary cavitation, the cavitations usually form in the upper lobes and generally take months to develop.

(Choice D) Major basic protein is the predominant component of eosinophilic granules and plays a crucial role in the elimination of parasites. Lung abscess formation is primarily mediated by neutrophils, not eosinophils.

(Choice E) Transforming growth factor-beta is secreted by inflammatory cells and results in the recruitment of fibroblasts and the deposition of connective tissue. This cytokine contributes to scar formation after injury and plays a role in the fibrosis seen with chronic inflammation.

Educational objective:
Abscess formation is largely driven by neutrophil recruitment and activation leading to the release of cytotoxic granules that kill bacteria but also cause liquefying necrosis of surrounding tissue.

References

- The multifaceted function of neutrophils.

Settings

1 2 3 4 5 6 7 8 9 10 11 12 13 14 15 16 17 18 19 20 21 22 23 24 25 26 27 28 29 30

Item 24 of 40
Question Id: 302

Mark | Previous | Next | Full Screen | Tutorial | Lab Values | Notes | Calculator | Reverse Color | Text Zoom | Settings

Exhibit Display

Lung abscess

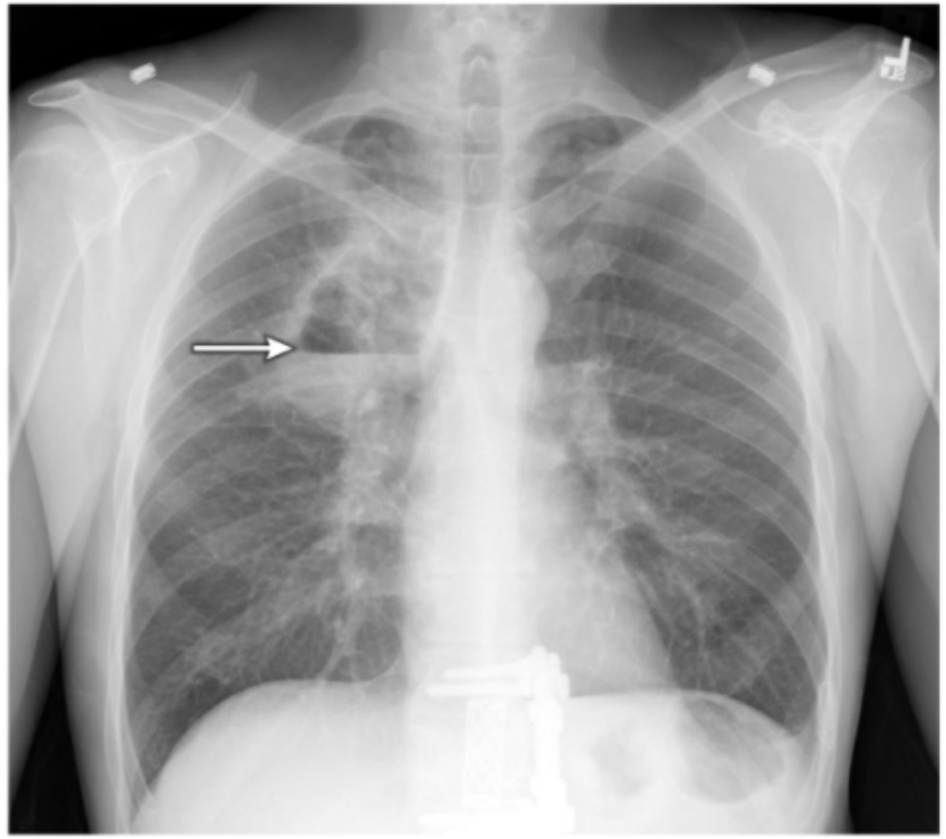

©UWorld

Zoom In | Zoom Out | Reset | Add To New Card | Existing Card

Block Time Remaining: 00:01:16
TUTOR

4 | Feedback | Suspend | End Block

Settings

1 2 3 4 5 6 7 8 9 10 11 12 13 14 15 16 17 18 19 20 21 22 23 24 25 26 27 28 29 30

Item 24 of 40
Question Id: 302

Mark | Previous | Next | Full Screen | Tutorial | Lab Values | Notes | Calculator | Reverse Color | Text Zoom | Settings

Exhibit Display

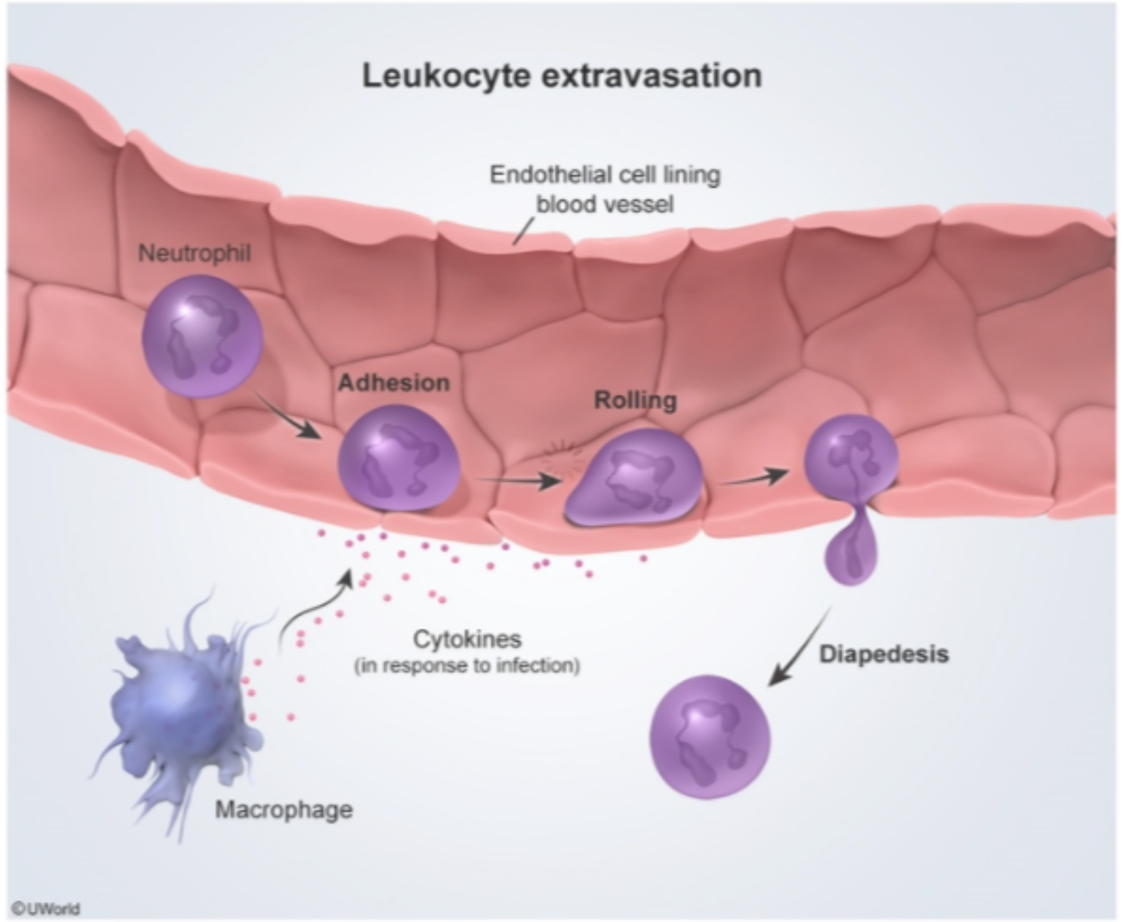

Zoom In | Zoom Out | Reset | Add To New Card | Existing Card

Block Time Remaining: 00:01:16
TUTOR

4 | Feedback | Suspend | End Block

Lung abscess is a necrotic infection of the pulmonary parenchyma that usually pres
sputum (often foul-smelling), and chest x-ray evidence of cavitation with air-fluid lev
from the oropharynx, but lung abscess can also develop in the setting of untreated p

Neutrophils are the key player in the formation of lung abscess. They are recruited
subsequently activated by microbial molecules (eg, lipopolysaccharide, peptidoglyca
complement) to phagocytize and destroy the pathogenic bacteria. Activated neutrop
myeloperoxidase and other digestive enzymes that destroy extracellular bacteria an
these enzymes also cause significant damage to the pulmonary parenchyma and ca
lung abscess.

(Choices A and B) Dendritic and other antigen-presenting cells release interleukin-
production of interferon-gamma by T-cells. Interferon-gamma activates macrophage
capable of destroying phagocytosed bacteria. Macrophages are particularly importa
Mycobacterium tuberculosis. Although tuberculosis can be associated with pulmona
and generally take months to develop.

(Choice D) Major basic protein is the predominant component of eosinophilic granu
Lung abscess formation is primarily mediated by neutrophils, not eosinophils.

(Choice E) Transforming growth factor-beta is secreted by inflammatory cells and r
connective tissue. This cytokine contributes to scar formation after injury and plays

Educational objective:
Abscess formation is largely driven by neutrophil recruitment and activation leading
cause liquefying necrosis of surrounding tissue.

References

- The multifaceted function of neutrophils.

Exhibit Display

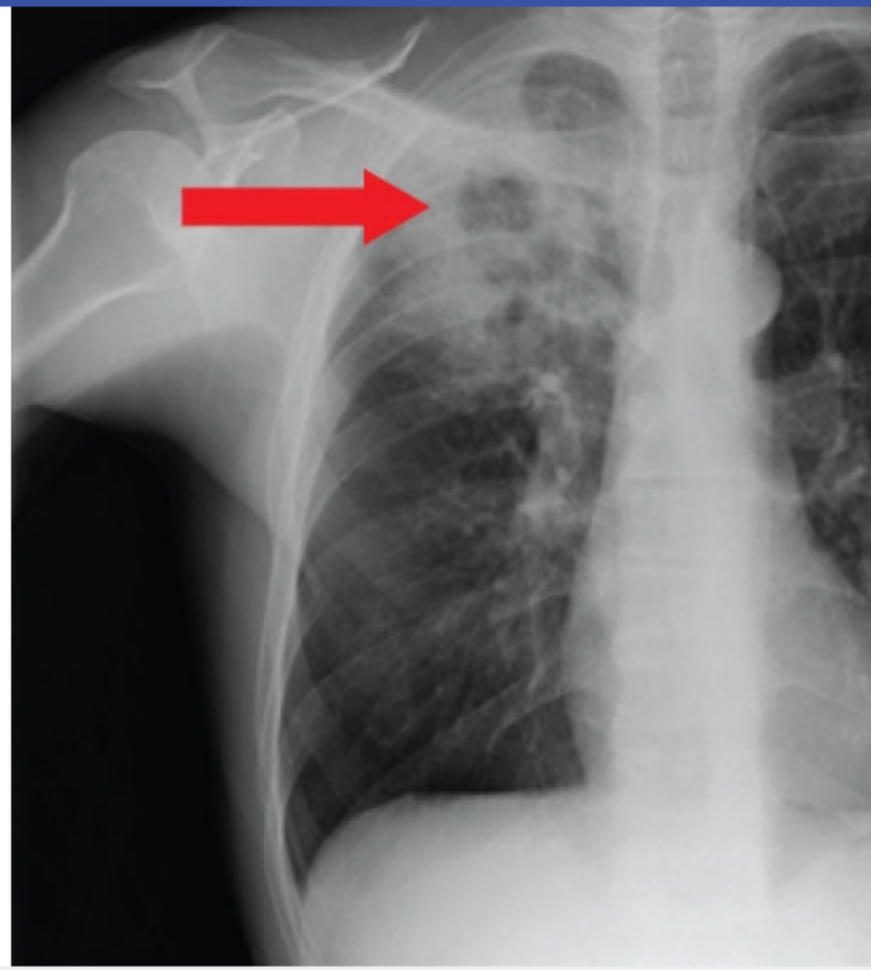

Zoom In | Zoom Out | Reset | Add To New

Settings

1
2
3
4
5
6
7
8
9
10
11
12
13
14
15
16
17
18
19
20
21
22
23
24
25
26
27
28
29
30

Item 24 of 40
Question Id: 302

Mark | Previous | Next | Full Screen | Tutorial | Lab Values | Notes | Calculator | Reverse Color | Text Zoom | Settings

Lung abscess is a
sputum (often foul-
from the oropharyn

Neutrophils are th
subsequently activa
complement) to pha
myeloperoxidase a
these enzymes als
lung abscess.

(Choices A and B)
production of interf
capable of destroyi
Mycobacterium tub
and generally take

(Choice D) Major
Lung abscess form

(Choice E) Transf
connective tissue.

Educational objec
Abscess formation
cause liquefying ne

References

- The multifacete

Exhibit Display

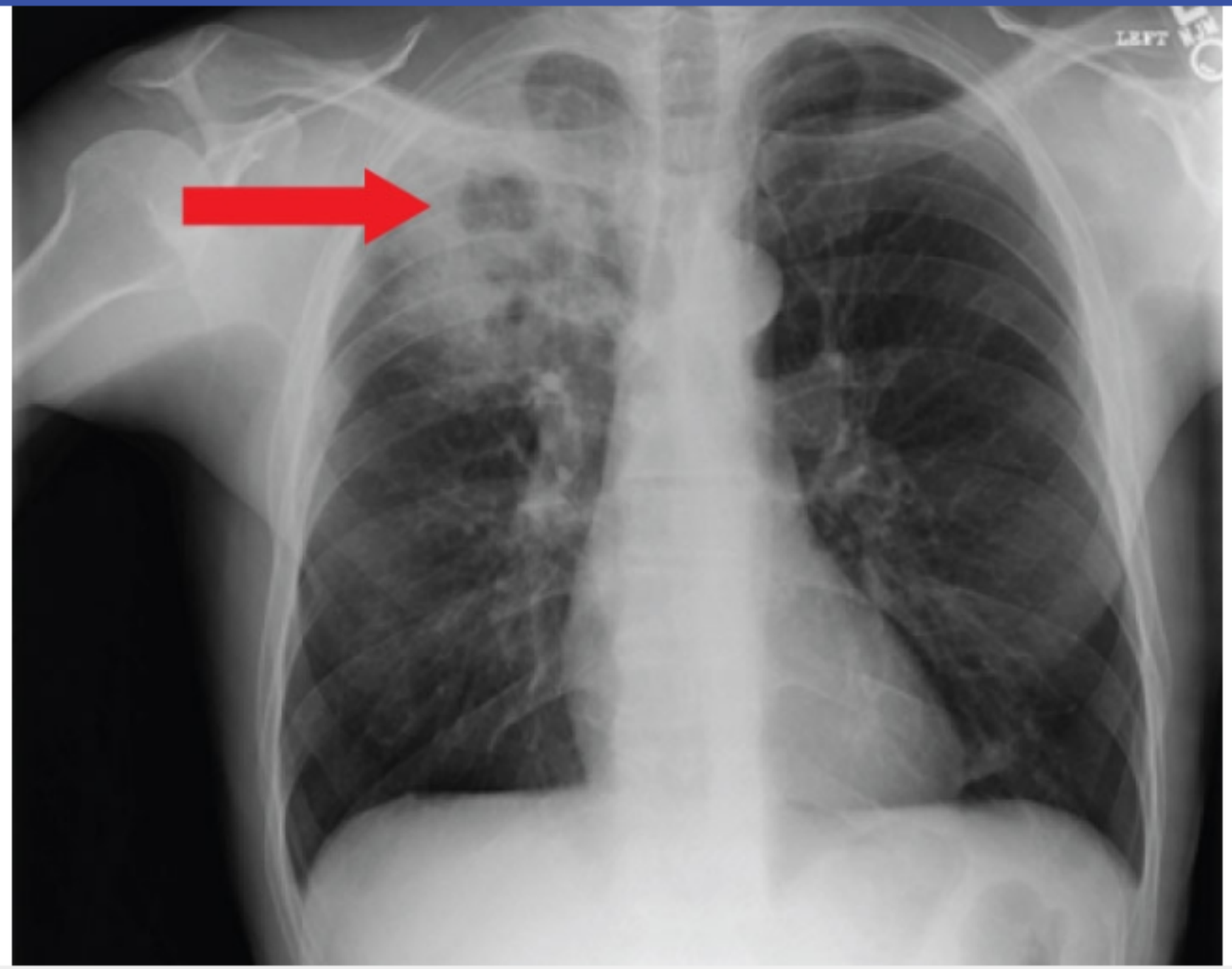

Zoom In | Zoom Out | Reset | Add To New Card | Existing Card

Block Time Remaining: 00:01:16
TUTOR

4 | Feedback | Suspend | End Block

A 58-year-old woman comes to the office due to gradually worsening shortness of breath. She has a history of emphysema secondary to alpha-1 antitrypsin deficiency and uses inhaled bronchodilators and glucocorticoids. Lately the patient has been feeling short of breath even with minimal exertion. She has no other medical conditions. The patient is a former smoker with a 5-pack-year history. Blood pressure is 130/80 mm Hg, pulse is 82/min, and respirations are 18/min. Physical examination shows increased anteroposterior chest diameter, prolonged expiratory phase, and decreased breath sounds bilaterally. The heart sounds are distant. Chest x-ray reveals hyperinflated lungs with no consolidation, pleural effusion, or pneumothorax. Which of the following sets of arterial blood gas findings on room air is most likely to be seen in this patient?

	pH	$PaCO_2$ (mm Hg)	Plasma HCO_3^- (mEq/L)	PaO_2 (mm Hg)
A.	7.22	60	24	70
B.	7.36	63	34	60
C.	7.40	40	24	80
D.	7.44	47	31	75
E.	7.59	25	23	65

Submit

A 58-year-old woman comes to the office due to gradually worsening shortness of breath. She has a history of emphysema secondary to alpha-1 antitrypsin deficiency and uses inhaled bronchodilators and glucocorticoids. Lately the patient has been feeling short of breath even with minimal exertion. She has no other medical conditions. The patient is a former smoker with a 5-pack-year history. Blood pressure is 130/80 mm Hg, pulse is 82/min, and respirations are 18/min. Physical examination shows increased anteroposterior chest diameter, prolonged expiratory phase, and decreased breath sounds bilaterally. The heart sounds are distant. Chest x-ray reveals hyperinflated lungs with no consolidation, pleural effusion, or pneumothorax. Which of the following sets of arterial blood gas findings on room air is most likely to be seen in this patient?

	pH	$PaCO_2$ (mm Hg)	Plasma HCO_3^- (mEq/L)	PaO_2 (mm Hg)
A. (14%)	7.22	60	24	70
✓ B. (67%)	7.36	63	34	60
C. (4%)	7.40	40	24	80
D. (7%)	7.44	47	31	75
E. (5%)	7.59	25	23	65

Omitted
Correct answer
B

67%
Answered correctly

02 secs
Time Spent

04/01/2020
Last Updated

1 2 3 4 5 6 7 8 9 10 11 12 13 14 15 16 17 18 19 20 21 22 23 24 25 26 27 28 29 30

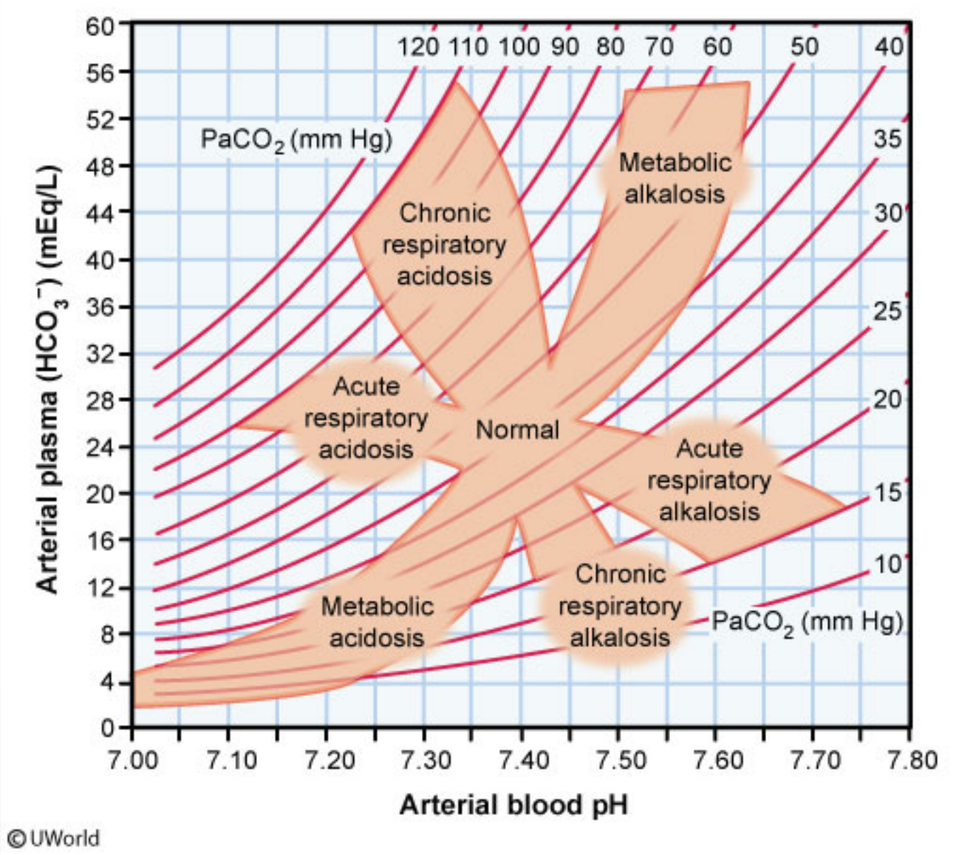

This patient's increased anteroposterior chest diameter, prolonged expiratory phase, distant heart sounds, and hyperinflation of the lungs on chest x-ray are consistent with **severe emphysema**. Severe disease results in impaired gas exchange due to destruction of the alveolar-arterial membrane, which can lead to **hypoxemia**. In addition, increased alveolar compliance (reduced lung elastic recoil) and collapse of floppy airways (airway obstruction) leads to **CO_2 retention**. The kidneys make up for the chronic retention of acidic CO_2 by increasing **reabsorption of bicarbonate** (secondary metabolic alkalosis) to help normalize pH.

Therefore, patients with severe emphysema are expected to have **chronic respiratory acidosis** with metabolic compensation (**high $PaCO_2$**,

© UWorld

This patient's increased anteroposterior chest diameter, prolonged expiratory phase, distant heart sounds, and hyperinflation of the lungs on chest x-ray are consistent with **severe emphysema**. Severe disease results in impaired gas exchange due to destruction of the alveolar-arterial membrane, which can lead to **hypoxemia**. In addition, increased alveolar compliance (reduced lung elastic recoil) and collapse of floppy airways (airway obstruction) leads to **CO_2 retention**. The kidneys make up for the chronic retention of acidic CO_2 by increasing **reabsorption of bicarbonate** (secondary metabolic alkalosis) to help normalize pH.

Therefore, patients with severe emphysema are expected to have **chronic respiratory acidosis** with metabolic compensation (**high $PaCO_2$**, compensatory **high bicarbonate**, slightly **acidic pH**), often accompanied by hypoxemia (PaO_2 <75 mm Hg on room air).

(Choice A) These values (low pH, high $PaCO_2$, normal bicarbonate) show acute respiratory acidosis with hypoxemia, such as occurs with hypoventilation due to acute opioid overdose. The kidneys require several days to compensate for respiratory acid-base disturbances; in acute settings, they do not have time to cause significant bicarbonate retention.

(Choice C) Blood pH 7.4, $PaCO_2$ 40 mm Hg, and plasma bicarbonate 24 mEq/L are normal values. Deviations from these values represent an acid-base disturbance.

(Choice D) These values (slightly high pH, elevated bicarbonate, elevated $PaCO_2$) show compensated metabolic alkalosis such as occurs with vomiting. The loss of hydrogen ions from the gastrointestinal tract is rapidly compensated for by CO_2 retention in the lungs (secondary respiratory acidosis). The blood pH corrects close to normal but remains slightly alkaline.

(Choice E) These values (high pH, low $PaCO_2$, near normal bicarbonate) show acute respiratory alkalosis with hypoxemia, such as occurs with hyperventilation due to acute pulmonary embolism. The kidneys have not had time to excrete bicarbonate to compensate for the increase in CO_2 exhalation.

Educational objective:
Patients with severe emphysema typically have chronic CO_2 retention leading to chronic respiratory acidosis with metabolic compensation (high $PaCO_2$, compensatory high bicarbonate, slightly acidic pH), often accompanied by hypoxemia (PaO_2 <75 mm Hg on room air).

Pathophysiology | Pulmonary & Critical Care | Alpha1 antitrypsin deficiency

©UWorld

Exhibit Display

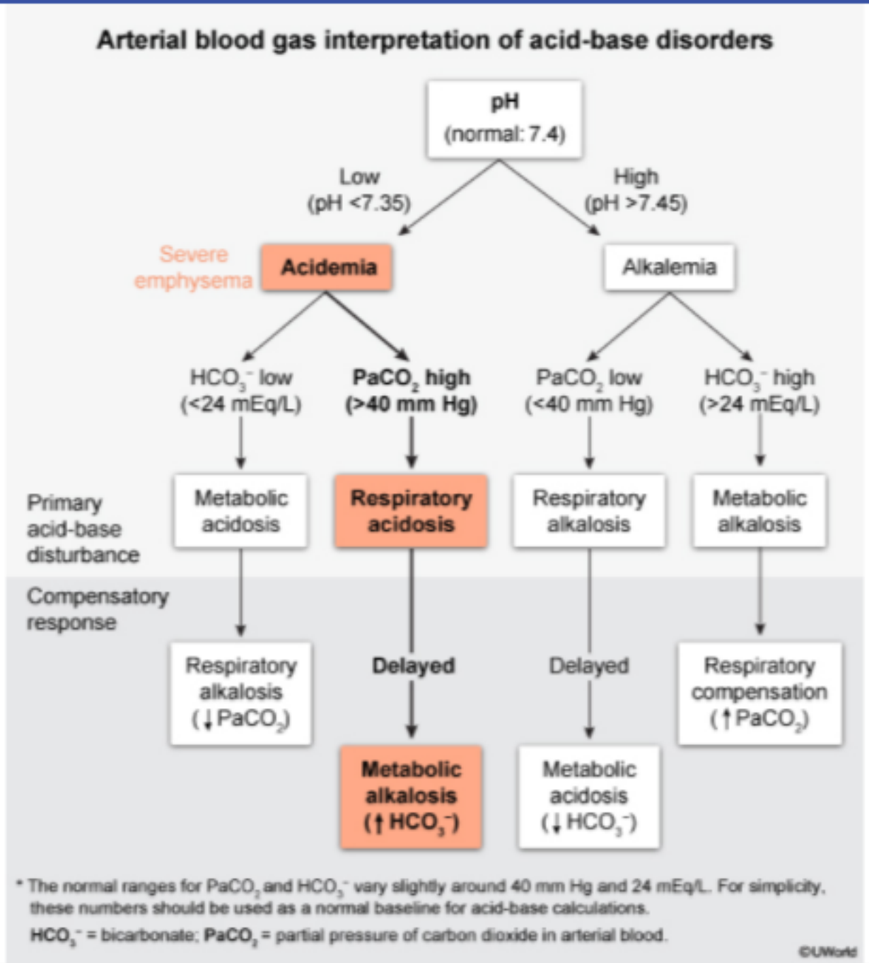

Zoom In | Zoom Out | Reset | Add To New Card | Existing Card

Pathophysiology | Pulmonary & Critical Care | Alpha1 antitrypsin deficiency

membrane, which can lead to **hypoxemia**. In addition, increased alveolar compliance (reduced lung elastic recoil) and collapse of floppy airways (airway obstruction) leads to **CO_2 retention**. The kidneys make up for the chronic retention of acidic CO_2 by increasing **reabsorption of bicarbonate** (secondary metabolic alkalosis) to help normalize pH.

Therefore, patients with severe emphysema are expected to have **chronic respiratory acidosis** with metabolic compensation (**high $PaCO_2$**, compensatory **high bicarbonate**, slightly **acidic pH**), often accompanied by hypoxemia (PaO_2 <75 mm Hg on room air).

(Choice A) These values (low pH, high $PaCO_2$, normal bicarbonate) show acute respiratory acidosis with hypoxemia, such as occurs with hypoventilation due to acute opioid overdose. The kidneys require several days to compensate for respiratory acid-base disturbances; in acute settings, they do not have time to cause significant bicarbonate retention.

(Choice C) Blood pH 7.4, $PaCO_2$ 40 mm Hg, and plasma bicarbonate 24 mEq/L are normal values. Deviations from these values represent an acid-base disturbance.

(Choice D) These values (slightly high pH, elevated bicarbonate, elevated $PaCO_2$) show compensated metabolic alkalosis such as occurs with vomiting. The loss of hydrogen ions from the gastrointestinal tract is rapidly compensated for by CO_2 retention in the lungs (secondary respiratory acidosis). The blood pH corrects close to normal but remains slightly alkaline.

(Choice E) These values (high pH, low $PaCO_2$, near normal bicarbonate) show acute respiratory alkalosis with hypoxemia, such as occurs with hyperventilation due to acute pulmonary embolism. The kidneys have not had time to excrete bicarbonate to compensate for the increase in CO_2 exhalation.

Educational objective:
Patients with severe emphysema typically have chronic CO_2 retention leading to chronic respiratory acidosis with metabolic compensation (high $PaCO_2$, compensatory high bicarbonate, slightly acidic pH), often accompanied by hypoxemia (PaO_2 <75 mm Hg on room air).

Pathophysiology	Pulmonary & Critical Care	Alpha1 antitrypsin deficiency
Subject	System	Topic

Copyright © UWorld. All rights reserved.

A 60-year-old woman comes to the emergency department due to shortness of breath and productive cough. The patient has a 30-pack-year smoking history. Oxygen saturation is 88% on room air. On physical examination, she appears uncomfortable and uses her accessory respiratory muscles to breathe. Expiratory wheezes are heard throughout the lungs. The patient is started on high-flow oxygen supplementation. Shortly afterward, she becomes increasingly lethargic and confused. This patient's clinical decline is most likely attributable to an increase in which of the following parameters?

- A. Pulmonary vascular resistance
- B. Reactive oxygen species production
- C. Renal bicarbonate reabsorption
- D. Respiratory minute ventilation
- E. Ventilation-perfusion mismatch

Submit

A 60-year-old woman comes to the emergency department due to shortness of breath and productive cough. The patient has a 30-pack-year smoking history. Oxygen saturation is 88% on room air. On physical examination, she appears uncomfortable and uses her accessory respiratory muscles to breathe. Expiratory wheezes are heard throughout the lungs. The patient is started on high-flow oxygen supplementation. Shortly afterward, she becomes increasingly lethargic and confused. This patient's clinical decline is most likely attributable to an increase in which of the following parameters?

- A. Pulmonary vascular resistance (11%)
- B. Reactive oxygen species production (22%)
- C. Renal bicarbonate reabsorption (5%)
- D. Respiratory minute ventilation (23%)
- ✓ E. Ventilation-perfusion mismatch (36%)

Omitted
Correct answer
E

36%
Answered correctly

01 sec
Time Spent

02/14/2020
Last Updated

Explanation

This patient's clinical presentation (ie, dyspnea, productive cough, hypoxemia, expiratory wheezing, accessory muscle use, smoking history) is consistent with a **chronic obstructive pulmonary disease (COPD) exacerbation**. Supplemental oxygen may be warranted in patients with COPD who have significant hypoxemia; however, administration of excessively high oxygen concentrations can lead to increased CO_2 retention (**oxygen-induced hypercapnia**), resulting in confusion and a depressed level of consciousness (eg, lethargy).

This patient's clinical presentation (ie, dyspnea, productive cough, hypoxemia, expiratory wheezing, accessory muscle use, smoking history) is consistent with a **chronic obstructive pulmonary disease (COPD) exacerbation**. Supplemental oxygen may be warranted in patients with COPD who have significant hypoxemia; however, administration of excessively high oxygen concentrations can lead to increased CO_2 retention (**oxygen-induced hypercapnia**), resulting in confusion and a depressed level of consciousness (eg, lethargy).

Several mechanisms contribute to oxygen-induced hypercapnia, but the major cause is increased **ventilation-perfusion mismatch**. Hypoxia causes vasoconstriction of the pulmonary arterioles, which acts to shunt blood toward alveoli with the highest ventilation, thereby minimizing physiologic dead space. Providing high-concentration supplemental oxygen allows lung regions with relatively poor ventilation to have higher oxygen levels, **reversing pulmonary vasoconstriction**. The redistribution of blood flow away from well-ventilated alveoli leads to an **increase in physiologic dead space** (well-ventilated alveoli are less perfused) with a corresponding reduction in CO_2 excretion.

(Choice A) Oxygen administration alleviates hypoxic pulmonary vasoconstriction, causing an overall decrease in pulmonary vascular resistance.

(Choice B) Hyperoxia can increase production of reactive oxygen species (eg, superoxide, hydroxyl radical, hydrogen peroxide), leading to injury of the airways and lung parenchyma. Oxygen toxicity typically manifests with substernal heaviness, pleuritic chest pain, and cough/dyspnea within 24 hours after breathing pure oxygen.

(Choice C) In patients with hypercapnia and respiratory acidosis, the kidneys compensate by increasing bicarbonate reabsorption and normalizing the serum pH level. This response occurs slowly over several days and would tend to ameliorate the effects of hypercapnia.

(Choice D) Peripheral chemoreceptors in the carotid and aortic bodies sense arterial PaO_2 and are normally stimulated by hypoxemia. High-flow oxygen reduces chemoreceptor stimulation, resulting in a decreased (not increased) respiratory rate and minute ventilation.

Educational objective:
Supplemental oxygen administration in patients with chronic obstructive pulmonary disease can lead to increased CO_2 retention (oxygen-induced hypercapnia), resulting in confusion and depressed consciousness. The major cause is reversal of hypoxic pulmonary vasoconstriction, which increases physiologic dead space as blood is shunted away from well-ventilated alveoli.

References

- Oxygen-induced hypercapnia in COPD: myths and facts.

Several mechanisms contribute to oxygen-induced hypercapnia, but the major cause is increased **ventilation-perfusion mismatch**. Hypoxia causes vasoconstriction of the pulmonary arterioles, which acts to shunt blood toward alveoli with the highest ventilation, thereby minimizing physiologic dead space. Providing high-concentration supplemental oxygen allows lung regions with relatively poor ventilation to have higher oxygen levels, **reversing pulmonary vasoconstriction**. The redistribution of blood flow away from well-ventilated alveoli leads to an **increase in physiologic dead space** (well-ventilated alveoli are less perfused) with a corresponding reduction in CO_2 excretion.

(Choice A) Oxygen administration alleviates hypoxic pulmonary vasoconstriction, causing an overall decrease in pulmonary vascular resistance.

(Choice B) Hyperoxia can increase production of reactive oxygen species (eg, superoxide, hydroxyl radical, hydrogen peroxide), leading to injury of the airways and lung parenchyma. Oxygen toxicity typically manifests with substernal heaviness, pleuritic chest pain, and cough/dyspnea within 24 hours after breathing pure oxygen.

(Choice C) In patients with hypercapnia and respiratory acidosis, the kidneys compensate by increasing bicarbonate reabsorption and normalizing the serum pH level. This response occurs slowly over several days and would tend to ameliorate the effects of hypercapnia.

(Choice D) Peripheral chemoreceptors in the carotid and aortic bodies sense arterial PaO_2 and are normally stimulated by hypoxemia. High-flow oxygen reduces chemoreceptor stimulation, resulting in a decreased (not increased) respiratory rate and minute ventilation.

Educational objective:
Supplemental oxygen administration in patients with chronic obstructive pulmonary disease can lead to increased CO_2 retention (oxygen-induced hypercapnia), resulting in confusion and depressed consciousness. The major cause is reversal of hypoxic pulmonary vasoconstriction, which increases physiologic dead space as blood is shunted away from well-ventilated alveoli.

References

- Oxygen-induced hypercapnia in COPD: myths and facts.

Pathophysiology	Pulmonary & Critical Care	COPD
Subject	System	Topic

Copyright © UWorld. All rights reserved.

A 44-year-old man comes to the emergency department with a 3-day history of fever, chills, malaise, dyspnea, and a cough productive of "greenish" sputum. The patient has no prior medical problems and has never been hospitalized. He has a 25-pack-year smoking history and drinks 4-5 beers a week. His temperature is 39.4 C (103 F), blood pressure is 130/80 mm Hg, pulse is 98/min, and respirations are 20/min. On examination, dullness to percussion, crackles, and egophony are present at the right lung base. The remainder of the examination is normal. Chest x-ray shows a dense infiltrate occupying the entire right lower lobe. Which of the following most likely accounts for the color of this patient's sputum?

A. Epithelial necrosis

B. Hemolysis

C. High bacterial load

D. Mucopolysaccharides

E. Myeloperoxidase

Submit

A 44-year-old man comes to the emergency department with a 3-day history of fever, chills, malaise, dyspnea, and a cough productive of "greenish" sputum. The patient has no prior medical problems and has never been hospitalized. He has a 25-pack-year smoking history and drinks 4-5 beers a week. His temperature is 39.4 C (103 F), blood pressure is 130/80 mm Hg, pulse is 98/min, and respirations are 20/min. On examination, dullness to percussion, crackles, and egophony are present at the right lung base. The remainder of the examination is normal. Chest x-ray shows a dense infiltrate occupying the entire right lower lobe. Which of the following most likely accounts for the color of this patient's sputum?

A. Epithelial necrosis (5%)

B. Hemolysis (6%)

C. High bacterial load (17%)

D. Mucopolysaccharides (20%)

✓ E. Myeloperoxidase (50%)

Omitted
Correct answer
E

50%
Answered correctly

01 sec
Time Spent

01/19/2020
Last Updated

Explanation

This middle-aged man presenting with new-onset fevers, productive cough, and a dense lobar infiltrate likely has community-acquired **pneumonia** (CAP). CAP in otherwise healthy individuals is most commonly caused by *Streptococcus pneumoniae*, the most common bacterial etiology worldwide. Tobacco use further increases its risk. In nonelderly patients, pneumococcal pneumonia presents with abrupt-onset fevers, rigors, tachypnea, and productive cough with consolidation in one lobe of the lungs.

Explanation

This middle-aged man presenting with new-onset fevers, productive cough, and a dense lobar infiltrate likely has community-acquired **pneumonia** (CAP). CAP in otherwise healthy individuals is most commonly caused by *Streptococcus pneumoniae*, the most common bacterial etiology worldwide. Tobacco use further increases its risk. In nonelderly patients, pneumococcal pneumonia presents with abrupt-onset fevers, rigors, tachypnea, and productive cough with consolidation in one lobe of the lungs.

Neutrophil **myeloperoxidase** is responsible for the **green** color of pus and sputum in bacterial infections. It is a blue-green heme-based pigmented molecule contained within the azurophilic granules of neutrophils and catalyzes the production of hypochlorous acid from chloride and hydrogen peroxide during the phagocytic respiratory burst.

(Choices A and B) Both the "currant jelly" sputum seen in pneumonia caused by *Klebsiella pneumoniae* and the "rusty" color occasionally seen in pneumococcal pneumonia are due to extravasation of red blood cells and hemoglobin into the sputum caused by extensive inflammation and necrosis.

(Choice C) *Pseudomonas* pneumonia can cause a blue-green pigment due to the production of pyocyanin, but *Pseudomonas* is not a common cause of CAP in otherwise healthy adults.

(Choice D) Respiratory epithelium sloughing and mucopolysaccharide production can contribute to the formation of sputum in patients with respiratory infection but does not contribute to sputum's green color.

Educational objective:
The green discoloration of pus or sputum seen during common bacterial infections is due to the presence of myeloperoxidase, a blue-green heme-based enzyme that is released from neutrophil azurophilic granules and forms hypochlorous acid (bleach).

References

- Myeloperoxidase in human neutrophil host defence.

Pathophysiology	Pulmonary & Critical Care	Community acquired pneumonia
Subject	System	Topic

Settings

1 2 3 4 5 6 7 8 9 10 11 12 13 14 15 16 17 18 19 20 21 22 23 24 25 26 27 28 29 30

Item 27 of 40
Question Id: 1910

Mark | Previous | Next | Full Screen | Tutorial | Lab Values | Notes | Calculator | Reverse Color | Text Zoom | Settings

Exhibit Display

Right lower lobe (RLL) pneumonia

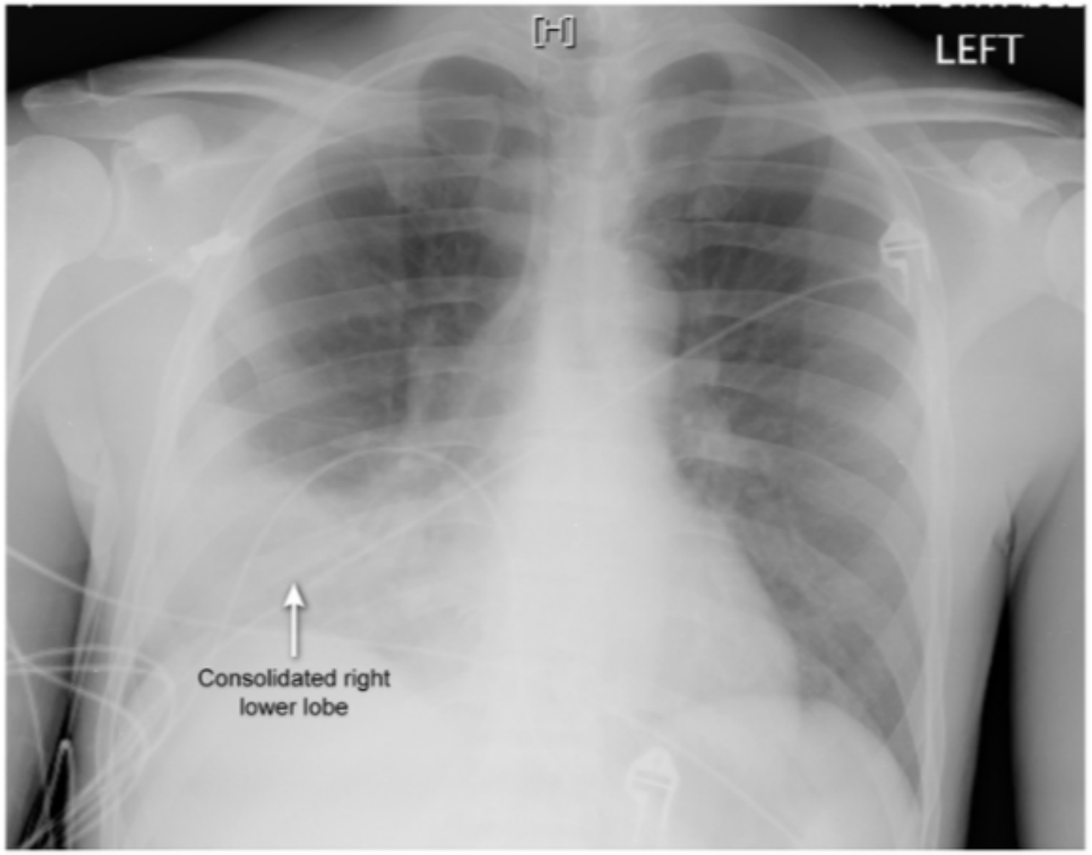

©UWorld

Zoom In | Zoom Out | Reset | Add To New Card | Existing Card

Block Time Remaining: 00:01:20
TUTOR

3 | Feedback | Suspend | End Block

1 2 3 4 5 6 7 8 9 10 11 12 13 14 15 16 17 18 19 20 21 22 23 24 25 26 27 28 29 30

A 57-year-old man is being evaluated for progressive shortness of breath. His respiratory flow-volume curve is shown in red below.

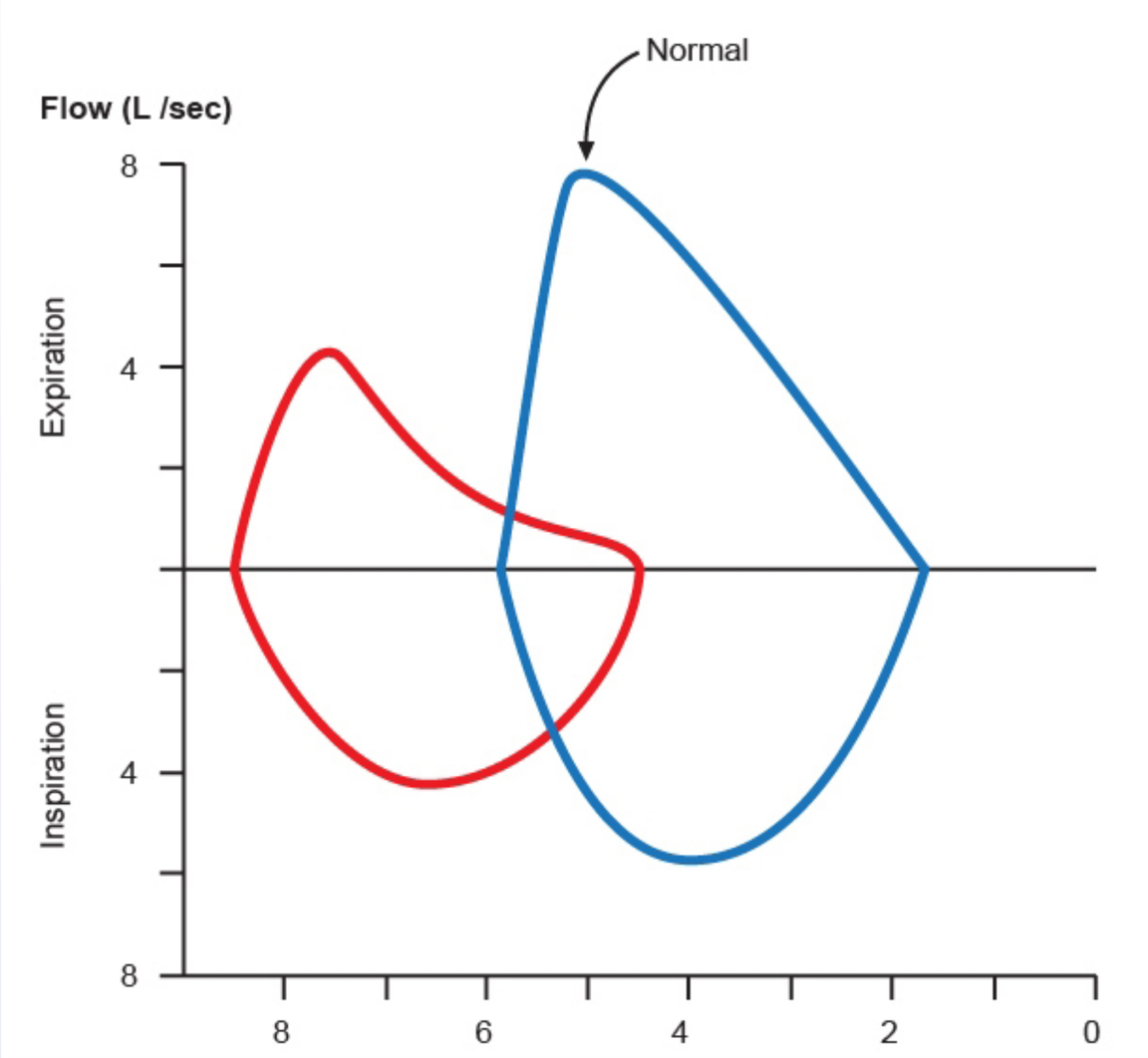

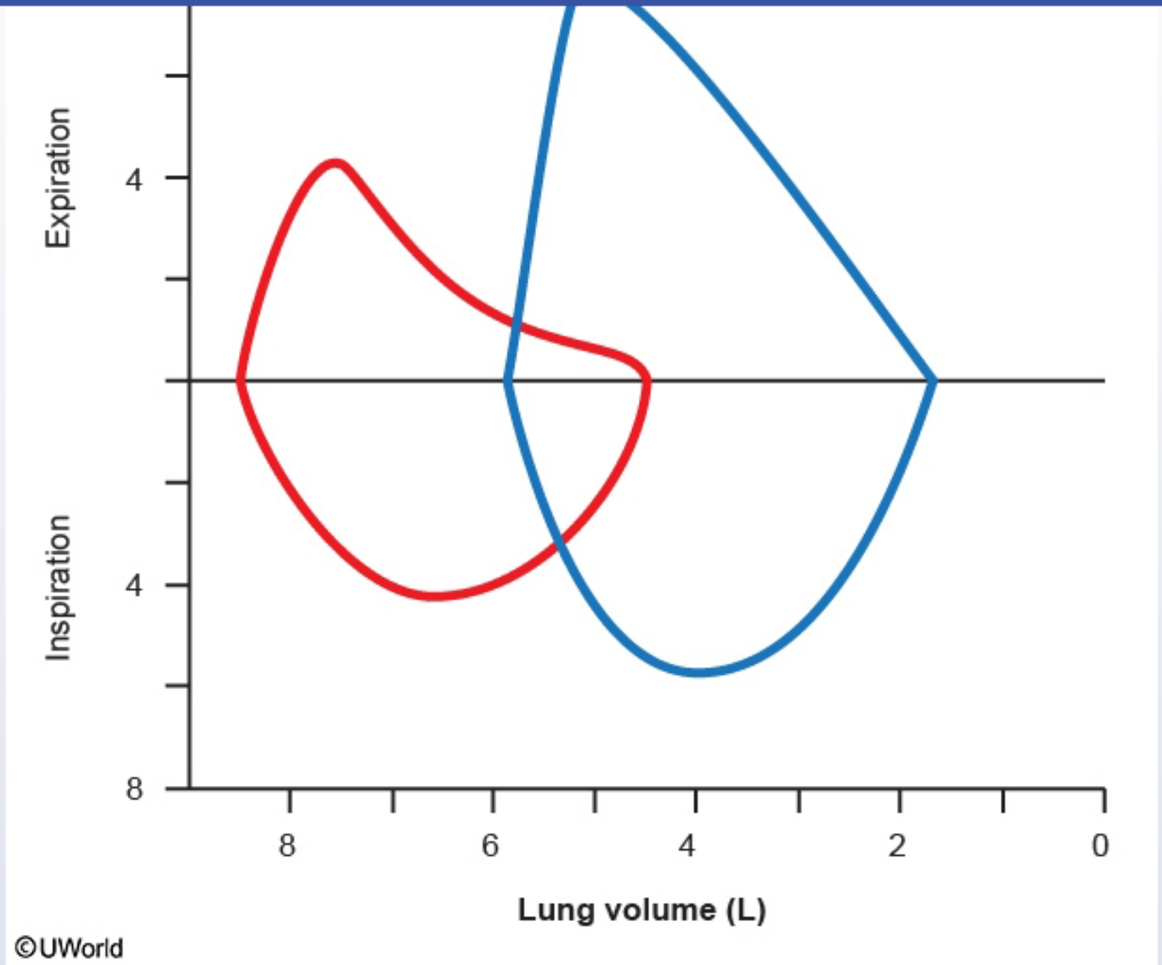

Which of the following pathologic findings is most likely to be present in this patient?

A. Alveolar hyaline membranes

B. Compression atelectasis

1 2 3 4 5 6 7 8 9 10 11 12 13 14 15 16 17 18 19 20 21 22 23 24 25 26 27 28 29 30

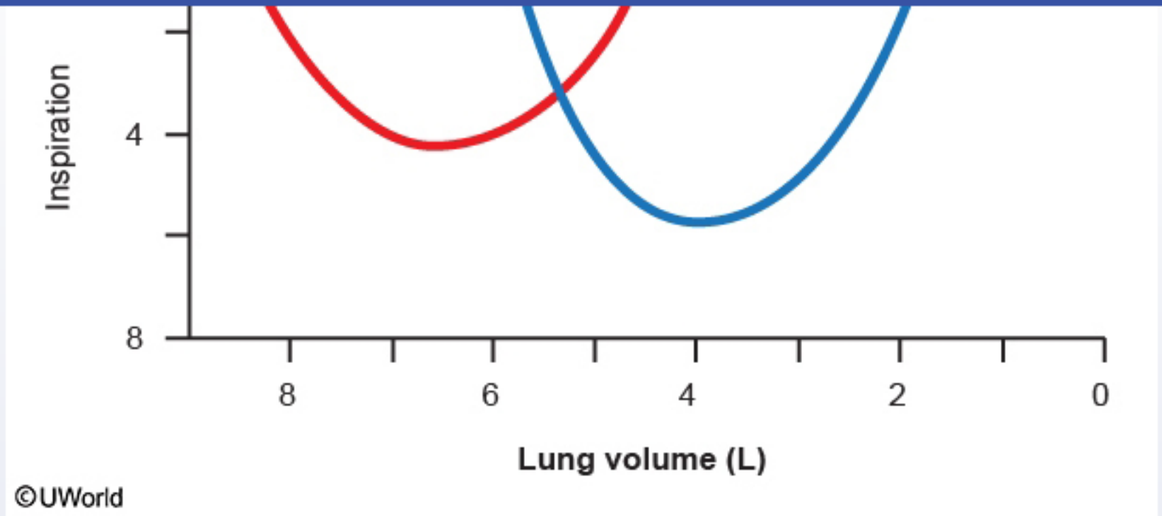

Which of the following pathologic findings is most likely to be present in this patient?

- A. Alveolar hyaline membranes
- B. Compression atelectasis
- C. Interalveolar wall destruction
- D. Intraalveolar hemorrhage
- E. Pulmonary fibrosis
- F. Thromboembolic disease

Submit

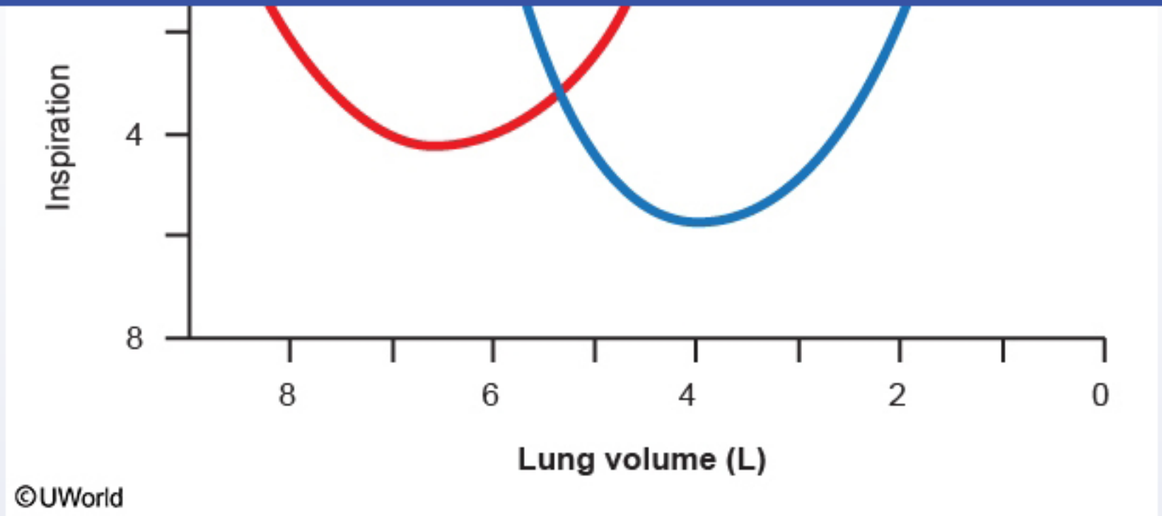

Which of the following pathologic findings is most likely to be present in this patient?

- A. Alveolar hyaline membranes (3%)
- B. Compression atelectasis (4%)
- ✓ C. Interalveolar wall destruction (63%)
- D. Intraalveolar hemorrhage (0%)
- E. Pulmonary fibrosis (26%)
- F. Thromboembolic disease (1%)

Omitted
Correct answer

63%
Answered correctly

06 secs
Time Spent

01/21/2020
Last Updated

1
2
3
4
5
6
7
8
9
10
11
12
13
14
15
16
17
18
19
20
21
22
23
24
25
26
27
28
29
30

Flow-volume curves for various lung conditions

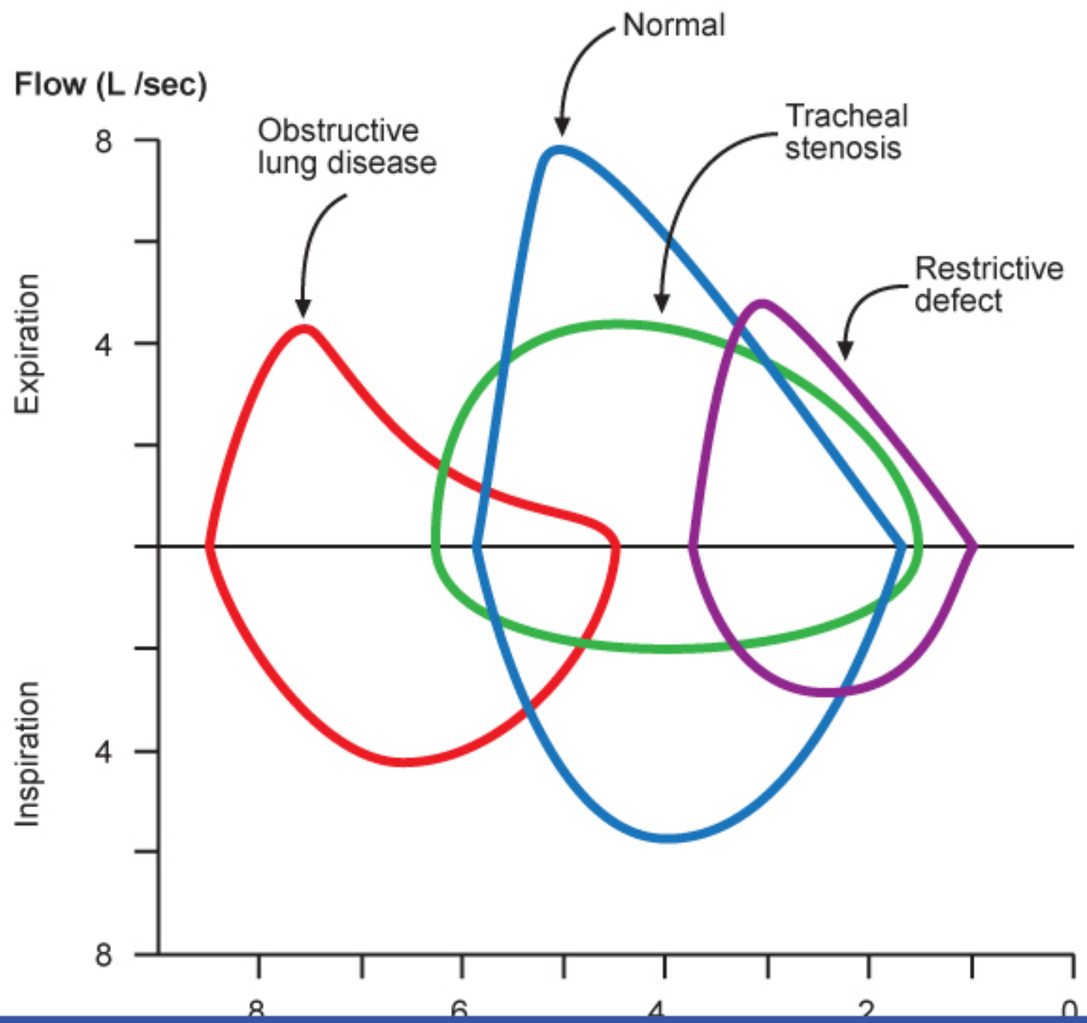

1
2
3
4
5
6
7
8
9
10
11
12
13
14
15
16
17
18
19
20
21
22
23
24
25
26
27
28
29
30

Flow-volume curves for various lung conditions

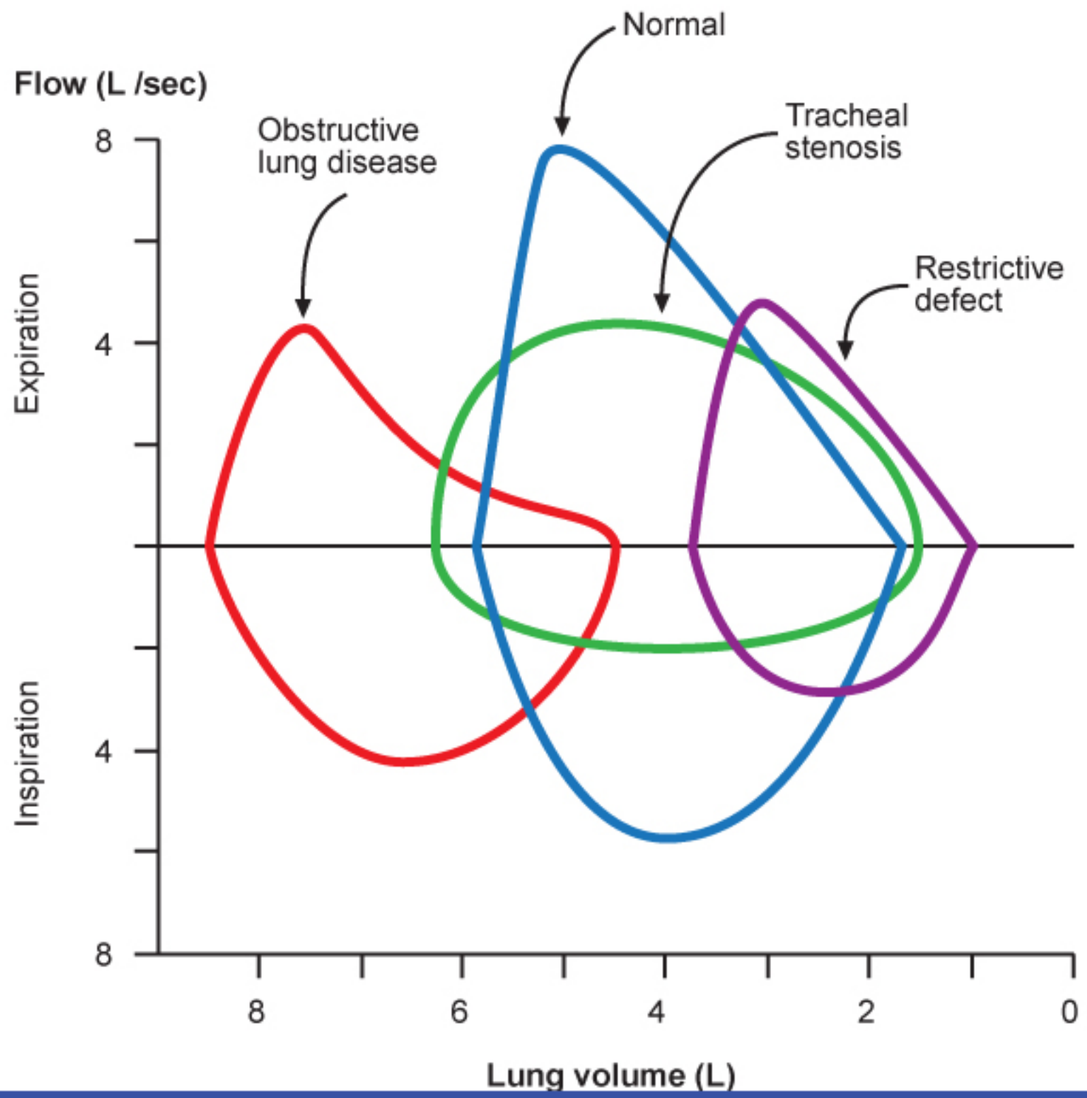

Flow-volume loops plot air velocity in relation to lung volume during a cycle of maximal inspiration and expiration. This patient's flow-volume loop exhibits a leftward shift indicating **increased total lung capacity** and **residual volume**. In addition, there is a characteristic **"scooped-out" expiratory pattern** consistent with the reduced expiratory flow rates seen in obstructive lung disease. This hyperinflation and expiratory airflow obstruction occur in **chronic obstructive pulmonary disease** (COPD). Airflow obstruction in COPD is partially due to anatomic narrowing of the bronchi (chronic bronchitis). In addition, decreased lung elasticity resulting from **destruction of interalveolar walls** (emphysema) promotes dynamic compression of the airways during expiration (intrapleural pressure becomes greater than airway pressure), further contributing to expiratory airflow obstruction.

Hyperinflation in COPD also reduces the inspiratory reserve volume, limiting the maximal tidal volume. This is especially true during exercise, when expiration time is limited. Because patients with COPD require extra time for exhalation, increasing amounts of air can become trapped in the lungs during rapid breathing, leading to further reduction in tidal volume. This is known as **dynamic hyperinflation** and is believed to be a major cause of dyspnea and exercise limitation in COPD.

(Choice A) Alveolar hyaline membranes are seen in acute respiratory distress syndrome. The pulmonary edema tends to reduce lung compliance, causing a restrictive flow-volume pattern (purple curve).

(Choice B) Atelectasis due to extrinsic pulmonary compression may occur when the pleural cavity fills with air (ie, pneumothorax) or fluid (eg, exudate, blood). Lung volumes and total lung compliance are likely reduced under such conditions, producing a restrictive flow-volume pattern.

(Choice D) Diffuse intraalveolar hemorrhage tends to dilute alveolar surfactant, increasing alveolar surface tension and promoting alveolar atelectasis. These changes would reduce lung volumes and lung compliance, resulting in a restrictive flow-volume pattern.

(Choice E) Pulmonary fibrosis tends to decrease lung volume and compliance, producing a restrictive pattern. In restrictive diseases, total lung capacity and residual volume are reduced. The expiratory flow rate is increased relative to the low lung volumes but is reduced compared to normal peak expiratory flow rates.

(Choice F) In pulmonary thromboembolism there is decreased perfusion but minimal effect on ventilation. Therefore, the flow-volume curve will remain mostly normal.

Educational objective:

The flow-volume loop for chronic obstructive pulmonary disease is characterized by increased residual volume and total lung capacity, as well as a

1 2 3 4 5 6 7 8 9 10 11 12 13 14 15 16 17 18 19 20 21 22 23 24 25 26 27 28 29 30

Exhibit Display

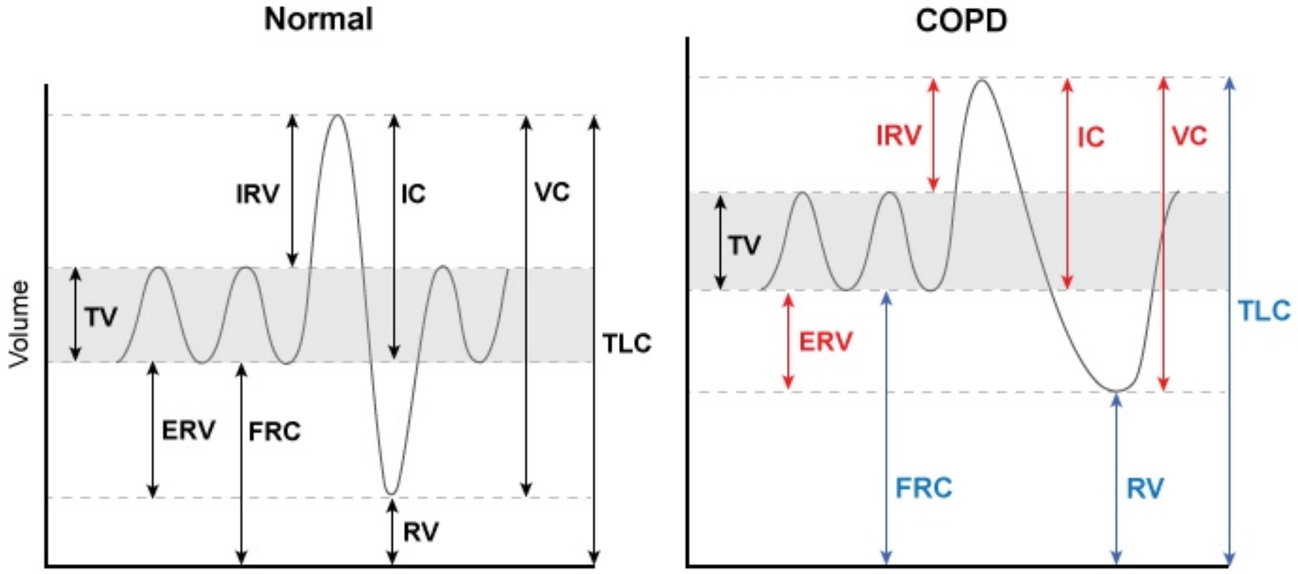

COPD = chronic obstructive pulmonary disease; **ERV** = expiratory reserve volume; **IC** = inspiratory capacity; **IRV** = inspiratory reserve volume; **FRC** = functional residual capacity; **RV** = residual volume; **TLC** = total lung capacity; **TV** = tidal volume; **VC** = vital capacity.

©UWorld

Zoom In | Zoom Out | Reset | Add To New Card | Existing Card

Hyperinflation in COPD also reduces the inspiratory reserve volume, limiting the maximal tidal volume. This is especially true during exercise, when expiration time is limited. Because patients with COPD require extra time for exhalation, increasing amounts of air can become trapped in the lungs during rapid breathing, leading to further reduction in tidal volume. This is known as **dynamic hyperinflation** and is believed to be a major cause of dyspnea and exercise limitation in COPD.

(Choice A) Alveolar hyaline membranes are seen in acute respiratory distress syndrome. The pulmonary edema tends to reduce lung compliance, causing a restrictive flow-volume pattern (purple curve).

(Choice B) Atelectasis due to extrinsic pulmonary compression may occur when the pleural cavity fills with air (ie, pneumothorax) or fluid (eg, exudate, blood). Lung volumes and total lung compliance are likely reduced under such conditions, producing a restrictive flow-volume pattern.

(Choice D) Diffuse intraalveolar hemorrhage tends to dilute alveolar surfactant, increasing alveolar surface tension and promoting alveolar atelectasis. These changes would reduce lung volumes and lung compliance, resulting in a restrictive flow-volume pattern.

(Choice E) Pulmonary fibrosis tends to decrease lung volume and compliance, producing a restrictive pattern. In restrictive diseases, total lung capacity and residual volume are reduced. The expiratory flow rate is increased relative to the low lung volumes but is reduced compared to normal peak expiratory flow rates.

(Choice F) In pulmonary thromboembolism there is decreased perfusion but minimal effect on ventilation. Therefore, the flow-volume curve will remain mostly normal.

Educational objective:
The flow-volume loop for chronic obstructive pulmonary disease is characterized by increased residual volume and total lung capacity, as well as a "scooped-out" expiratory pattern due to reduced expiratory flow rates. Both airway narrowing due to chronic bronchitis and decreased elasticity due to emphysematous destruction of interalveolar walls are responsible for the hyperinflation and airflow limitation.

Pathophysiology	Pulmonary & Critical Care	COPD
Subject	System	Topic

Copyright © UWorld. All rights reserved.

A 62-year-old woman is brought to the emergency department due to progressive weakness and dyspnea. The patient is visiting her niece, who says the patient forgot to bring her regular medications and has not been taking them for the past week. The patient began feeling weak and fatigued 3 days ago and has had shortness of breath since yesterday. Temperature is 37 C (98.6 F), blood pressure is 122/88 mm Hg, pulse is 90/min, and respirations are 24/min and shallow. On physical examination, the patient appears dyspneic with drooping at the eyelids and corners of the mouth. Her speech has a nasal quality. Arterial blood gas obtained on room air shows pH 7.32; $PaCO_2$ is 52 mm Hg, PaO_2 is 72 mm Hg, and HCO_3 is 26 mEq/L. Bedside spirometry demonstrates decreased forced vital capacity. A pathologic process involving which of the following structures is the most likely cause of this patient's shortness of breath?

A. Brain stem respiratory center

B. Muscles of respiration

C. Pulmonary arteries

D. Terminal airways and alveoli

E. Upper larger airways

Submit

A 62-year-old woman is brought to the emergency department due to progressive weakness and dyspnea. The patient is visiting her niece, who says the patient forgot to bring her regular medications and has not been taking them for the past week. The patient began feeling weak and fatigued 3 days ago and has had shortness of breath since yesterday. Temperature is 37 C (98.6 F), blood pressure is 122/88 mm Hg, pulse is 90/min, and respirations are 24/min and shallow. On physical examination, the patient appears dyspneic with drooping at the eyelids and corners of the mouth. Her speech has a nasal quality. Arterial blood gas obtained on room air shows pH 7.32; $PaCO_2$ is 52 mm Hg, PaO_2 is 72 mm Hg, and HCO_3 is 26 mEq/L. Bedside spirometry demonstrates decreased forced vital capacity. A pathologic process involving which of the following structures is the most likely cause of this patient's shortness of breath?

- A. Brain stem respiratory center (15%)
- ✓ B. Muscles of respiration (58%)
- C. Pulmonary arteries (2%)
- D. Terminal airways and alveoli (16%)
- E. Upper larger airways (7%)

Omitted
Correct answer
B

58%
Answered correctly

01 sec
Time Spent

03/22/2020
Last Updated

Explanation

Normal neuromuscular junction **Myasthenia gravis**

1 2 3 4 5 6 7 8 9 10 11 12 13 14 15 16 17 18 19 20 21 22 23 24 25 26 27 28 29 30

Explanation

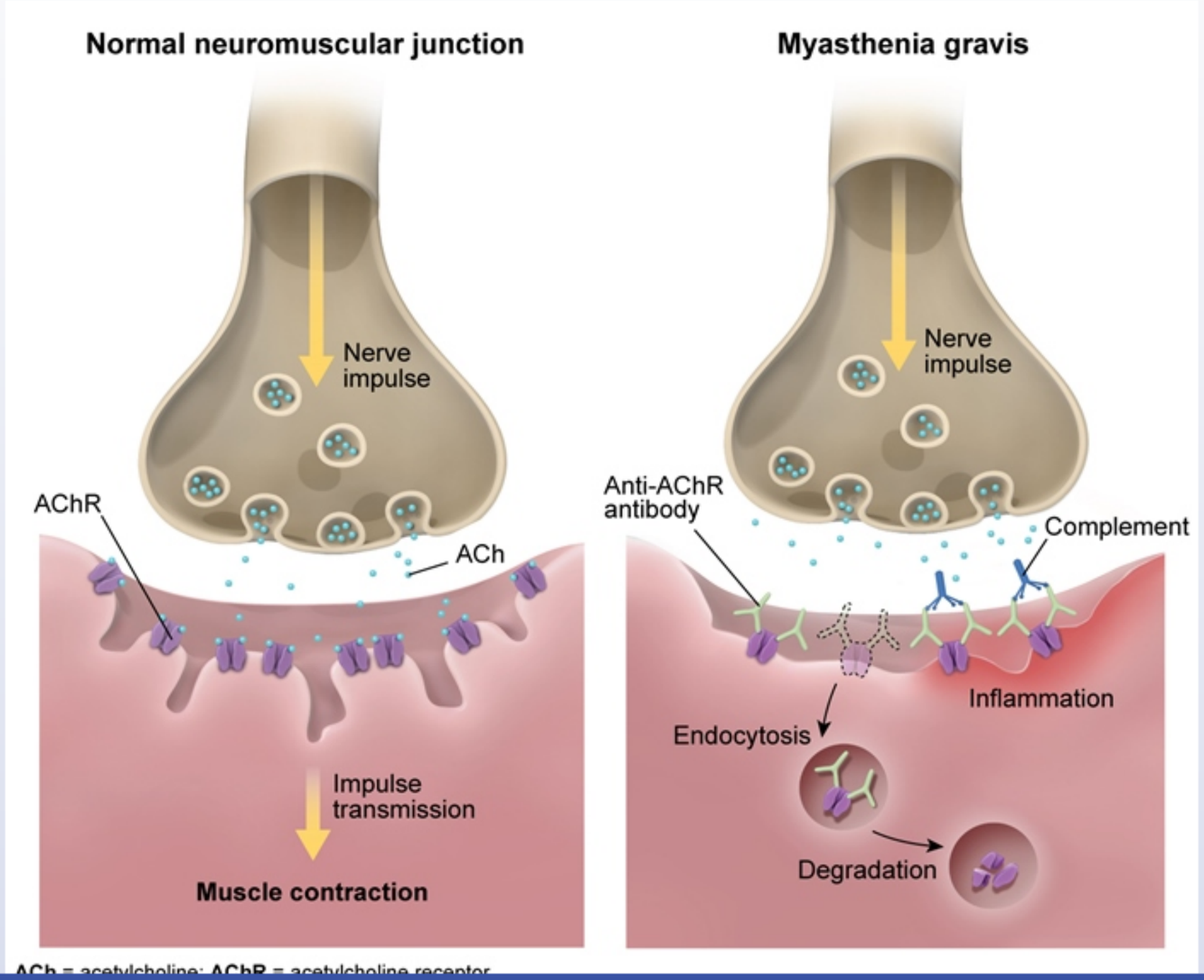

ACh = acetylcholine; AChR = acetylcholine receptor

This patient has hypercapnic and hypoxic respiratory failure (low pH, high CO_2, low O_2) indicating **global hypoventilation**. In association with the ptosis, bulbar weakness, and low forced vital capacity, this presentation suggests **myasthenic crisis** (severe weakness and respiratory depression due to an exacerbation of myasthenia gravis [MG]).

MG is characterized by **autoantibodies against nicotinic acetylcholine receptors** on the postsynaptic membrane of the neuromuscular junction, resulting in receptor degradation. This reduces the sensitivity of the postsynaptic membrane to acetylcholine stimulation, leading to reduced muscular response despite normal acetylcholine release. Muscle **weakness worsens with repetition** as acetylcholine stores within the presynaptic nerve terminal become progressively depleted.

Patients with MG typically have extraocular (eg, ptosis, diplopia), bulbar (eg, dysphonia, difficulty chewing), and facial (eg, myasthenic snarl) weakness. In addition, neck and proximal muscle weakness may occur, and in severe cases the **respiratory muscles** may be affected, leading to **respiratory failure** (as in this patient). Acetylcholinesterase inhibitors (eg, pyridostigmine, neostigmine) are used for symptomatic treatment, and withdrawal can trigger a myasthenic crisis.

(Choice A) Impairment of the respiratory control centers in the brain stem causes hypoventilation during sleep (Ondine curse); however, voluntary breathing is unaffected.

(Choice C) Pulmonary embolism can result in dyspnea and gas exchange abnormalities (eg, hypoxia). However, significant muscular weakness (eg, ptosis, nasal speech, decreased vital capacity) would be unexpected.

(Choices D and E) Patients with diseases involving the terminal airways and alveoli (eg, pulmonary fibrosis, emphysema) and large airways (eg, asthma, chronic bronchitis) can present with respiratory failure subsequent to muscle fatigue. However, these diseases are not associated with non-respiratory muscle weakness (eg, dysphonia, bulbar weakness).

Educational objective:
Myasthenia gravis is characterized by autoantibodies against postsynaptic nicotinic acetylcholine receptors at the neuromuscular junction, which result in receptor degradation. Patients typically have extraocular, bulbar, and facial weakness that worsens with activity. In severe cases, the respiratory muscles may be affected, leading to hypoventilation and respiratory failure.

MG is characterized by **autoantibodies against nicotinic acetylcholine receptors** on the postsynaptic membrane of the neuromuscular junction, resulting in receptor degradation. This reduces the sensitivity of the postsynaptic membrane to acetylcholine stimulation, leading to reduced muscular response despite normal acetylcholine release. Muscle **weakness worsens with repetition** as acetylcholine stores within the presynaptic nerve terminal become progressively depleted.

Patients with MG typically have extraocular (eg, ptosis, diplopia), bulbar (eg, dysphonia, difficulty chewing), and facial (eg, myasthenic snarl) weakness. In addition, neck and proximal muscle weakness may occur, and in severe cases the **respiratory muscles** may be affected, leading to **respiratory failure** (as in this patient). Acetylcholinesterase inhibitors (eg, pyridostigmine, neostigmine) are used for symptomatic treatment, and withdrawal can trigger a myasthenic crisis.

(Choice A) Impairment of the respiratory control centers in the brain stem causes hypoventilation during sleep (Ondine curse); however, voluntary breathing is unaffected.

(Choice C) Pulmonary embolism can result in dyspnea and gas exchange abnormalities (eg, hypoxia). However, significant muscular weakness (eg, ptosis, nasal speech, decreased vital capacity) would be unexpected.

(Choices D and E) Patients with diseases involving the terminal airways and alveoli (eg, pulmonary fibrosis, emphysema) and large airways (eg, asthma, chronic bronchitis) can present with respiratory failure subsequent to muscle fatigue. However, these diseases are not associated with non-respiratory muscle weakness (eg, dysphonia, bulbar weakness).

Educational objective:
Myasthenia gravis is characterized by autoantibodies against postsynaptic nicotinic acetylcholine receptors at the neuromuscular junction, which result in receptor degradation. Patients typically have extraocular, bulbar, and facial weakness that worsens with activity. In severe cases, the respiratory muscles may be affected, leading to hypoventilation and respiratory failure.

Pathophysiology	Pulmonary & Critical Care	Myasthenia gravis
Subject	System	Topic

Copyright © UWorld. All rights reserved.

A 45-year-old man comes to the emergency department due to severe dyspnea and chest discomfort that began earlier in the day. The dyspnea has been worsening throughout the day and has been present at rest. He reports no inciting trauma. The patient has no other medical conditions and takes no medications. He has a 20-pack-year smoking history and does not use alcohol or illicit drugs. Temperature is 36.7 C (98 F), blood pressure is 110/60 mm Hg, and pulse is 96/min. Arterial blood gas drawn on room air shows an arterial partial pressure of oxygen (PaO_2) of 54 mm Hg and an arterial partial pressure of carbon dioxide ($PaCO_2$) of 26 mm Hg. Which of the following processes is most likely occurring in this patient?

- A. Alveolar hyperventilation
- B. Decreased chest wall compliance
- C. Expiratory air trapping
- D. Poor respiratory drive
- E. Respiratory muscle fatigue

Submit

1 2 3 4 5 6 7 8 9 10 11 12 13 14 15 16 17 18 19 20 21 22 23 24 25 26 27 28 29 30

A 45-year-old man comes to the emergency department due to severe dyspnea and chest discomfort that began earlier in the day. The dyspnea has been worsening throughout the day and has been present at rest. He reports no inciting trauma. The patient has no other medical conditions and takes no medications. He has a 20-pack-year smoking history and does not use alcohol or illicit drugs. Temperature is 36.7 C (98 F), blood pressure is 110/60 mm Hg, and pulse is 96/min. Arterial blood gas drawn on room air shows an arterial partial pressure of oxygen (PaO_2) of 54 mm Hg and an arterial partial pressure of carbon dioxide ($PaCO_2$) of 26 mm Hg. Which of the following processes is most likely occurring in this patient?

- ✓ A. Alveolar hyperventilation (52%)
- B. Decreased chest wall compliance (10%)
- C. Expiratory air trapping (19%)
- D. Poor respiratory drive (10%)
- E. Respiratory muscle fatigue (7%)

Omitted
Correct answer
A

52%
Answered correctly

01 sec
Time Spent

07/06/2020
Last Updated

Explanation

Effect of hyperventilation on O_2 & CO_2 exchange

Effect of hyperventilation on O_2 & CO_2 exchange

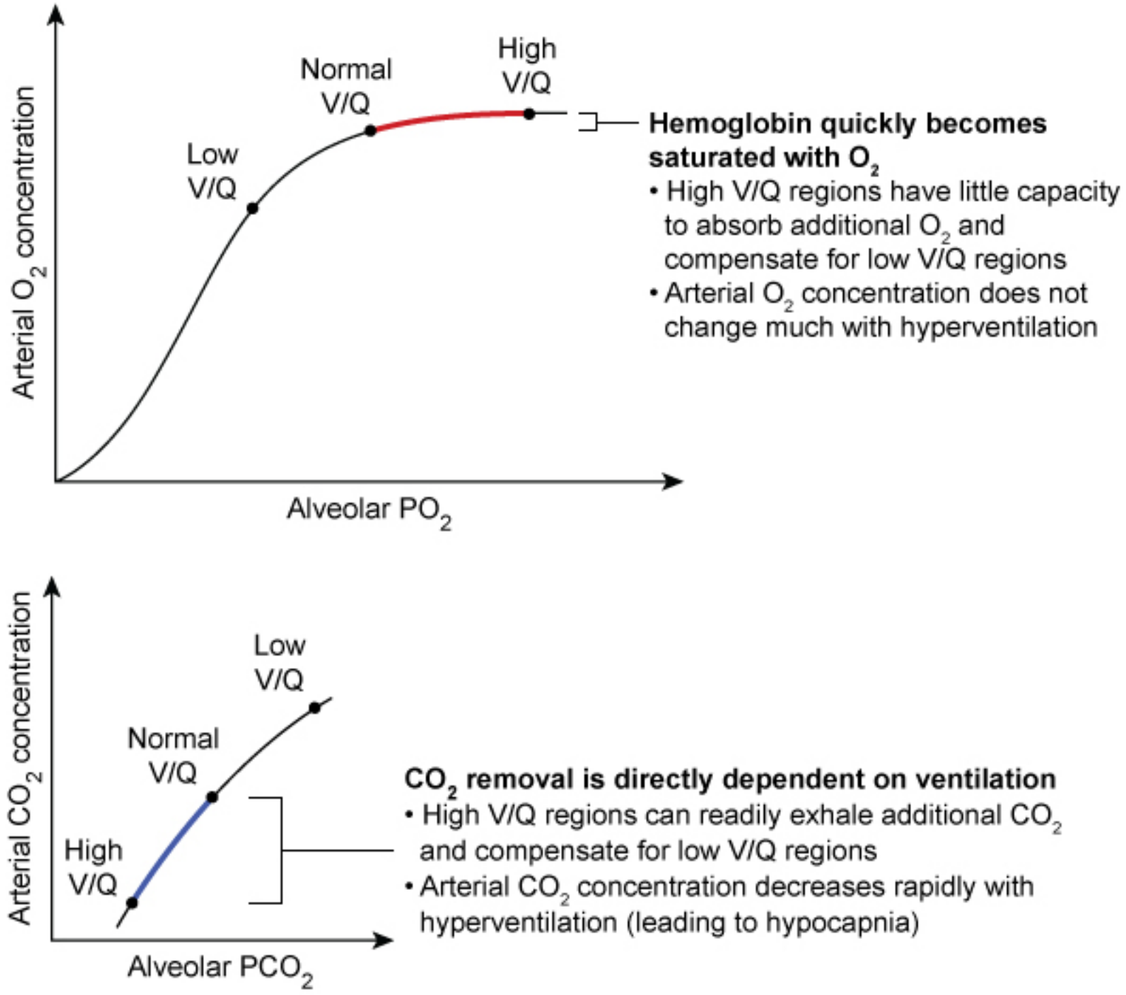

©UWorld

This patient with acute-onset dyspnea and chest discomfort likely has an **acute pulmonary embolism** (PE). PE leads to increased dead-space

©UWorld

This patient with acute-onset dyspnea and chest discomfort likely has an **acute pulmonary embolism** (PE). PE leads to increased dead-space ventilation with a consequent ventilation/perfusion (V/Q) mismatch that causes **hypoxemia**. The acute hypoxemia along with pulmonary parenchymal inflammation triggers an increase in respiratory drive and **hyperventilation**.

Because the rate of CO_2 removal is closely tied to ventilation rate, alveolar hyperventilation leads to **increased expiration of CO_2** with resulting **hypocapnia** (low arterial partial pressure of carbon dioxide [$PaCO_2$]) and **respiratory alkalosis**. In contrast, the rate of O_2 absorption becomes capped once hemoglobin is saturated, which occurs at relatively low arterial partial pressure of oxygen (PaO_2) levels (eg, hemoglobin is 85% saturated at PaO_2 50 mm Hg). Therefore, the blood in highly ventilated lung regions cannot absorb extra O_2 to compensate for poorly ventilated regions, and hyperventilation does not significantly increase PaO_2.

It follows that patients with an acute V/Q mismatch (eg, due to PE or pneumonia) typically have hypocapnia with respiratory alkalosis and persistent hypoxemia. Without treatment, prolonged hyperventilation can lead to respiratory muscle fatigue **(Choice E)** with consequent respiratory failure; these patients will have hypoventilation with hypercapnia and respiratory acidosis.

(Choices B and D) Both decreased chest wall compliance, as occurs in obesity hypoventilation syndrome, and poor respiratory drive, as occurs in opioid overdose and some types of stroke, lead to hypoventilation with hypoxemia and increased $PaCO_2$ levels.

(Choice C) Expiratory air trapping occurs in chronic obstructive lung disease. These patients often have chronic respiratory acidosis (high $PaCO_2$) that may worsen (acute on chronic respiratory acidosis) during exacerbation.

Educational objective:
An acute ventilation/perfusion mismatch (eg, due to pulmonary embolism or pneumonia) causes hypoxemia and triggers hyperventilation. Because the removal of CO_2 is directly dependent on ventilation but the absorption of O_2 is capped by the high baseline saturation of hemoglobin, the hyperventilation response typically leads to respiratory alkalosis (low arterial partial pressure of carbon dioxide) with persistent hypoxemia.

References

- Mechanisms of hypoxemia and hypocapnia in pulmonary embolism.

1
2
3
4
5
6
7
8
9
10
11
12
13
14
15
16
17
18
19
20
21
22
23
24
25
26
27
28
29
30

Exhibit Display

Pulmonary embolism

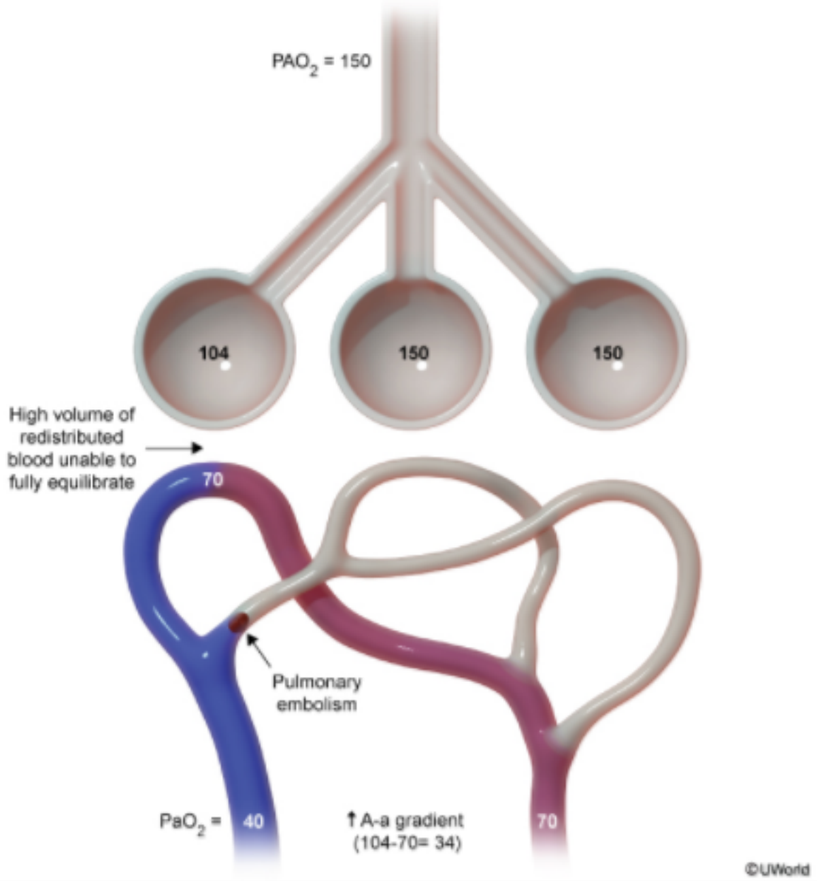

Zoom In | Zoom Out | Reset | Add To New Card | Existing Card

A 65-year-old man comes to the office due to worsening exertional dyspnea over the past 3 months. This past year, he has had 4 respiratory infections that improved with medical therapy. The patient does not use alcohol or illicit drugs and has smoked 1½ packs of cigarettes daily for 30 years. Temperature is 36.7 C (98.1 F), pulse is 76/min, and respirations are 18/min. On physical examination, breath sounds are diffusely decreased. Chest radiography reveals flattened hemidiaphragms, increased radiolucency of the lungs, and a long, narrow heart shadow. This patient's pulmonary function testing will most likely show which of the following patterns of findings?

	Total lung capacity	Forced expiratory volume in 1 second/ forced vital capacity	Forced vital capacity	Residual volume
A.	↓	↓	Normal	↑
B.	↑	↓	↓	↓
C.	↑	↓	↓	↑
D.	↑	Normal	↑	Normal
E.	↓	↑	↓	↓

Submit

A 65-year-old man comes to the office due to worsening exertional dyspnea over the past 3 months. This past year, he has had 4 respiratory infections that improved with medical therapy. The patient does not use alcohol or illicit drugs and has smoked 1½ packs of cigarettes daily for 30 years. Temperature is 36.7 C (98.1 F), pulse is 76/min, and respirations are 18/min. On physical examination, breath sounds are diffusely decreased. Chest radiography reveals flattened hemidiaphragms, increased radiolucency of the lungs, and a long, narrow heart shadow. This patient's pulmonary function testing will most likely show which of the following patterns of findings?

	Total lung capacity	Forced expiratory volume in 1 second/ forced vital capacity	Forced vital capacity	Residual volume
A. (4%)	↓	↓	Normal	↑
B. (2%)	↑	↓	↓	↓
✓ C. (88%)	↑	↓	↓	↑
D. (1%)	↑	Normal	↑	Normal
E. (2%)	↓	↑	↓	↓

Omitted
Correct answer
C

88%
Answered correctly

02 secs
Time Spent

01/25/2020
Last Updated

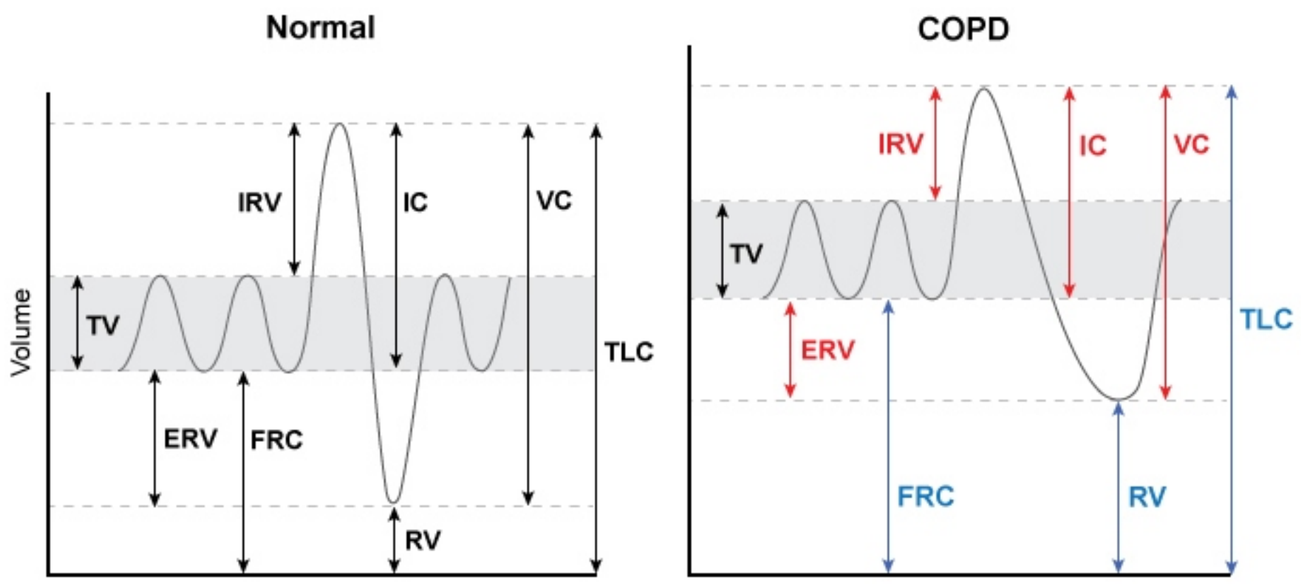

COPD = chronic obstructive pulmonary disease; **ERV** = expiratory reserve volume; **IC** = inspiratory capacity; **IRV** = inspiratory reserve volume; **FRC** = functional residual capacity; **RV** = residual volume; **TLC** = total lung capacity; **TV** = tidal volume; **VC** = vital capacity.

©UWorld

This patient's clinical picture is consistent with **chronic obstructive pulmonary disease** (COPD), which is a combination of **chronic bronchitis** and **emphysema** and is most commonly due to heavy smoking. Patients typically have progressive dyspnea and recurrent upper respiratory infections (characteristic of chronic bronchitis).

Air trapping and airway obstruction in COPD reduce both forced expiratory volume in 1 second (FEV1) and forced vital capacity (**FVC**) on pulmonary function testing (PFT). Because the decrease in FEV1 is more profound, the **FEV1/FVC ratio** is also **reduced**, which is the hallmark of obstructive lung disease on PFT. Air trapping raises functional residual capacity, causing respiration to occur at a higher baseline lung volume. The **residual volume** (RV) is increased. **Total lung capacity** (TLC) is also **increased**.

(Choices A and B) RV and TLC values are rarely discordant; therefore, these PFT findings are unlikely to represent true clinical findings.

COPD = chronic obstructive pulmonary disease; **ERV** = expiratory reserve volume; **IC** = inspiratory capacity; **IRV** = inspiratory reserve volume; **FRC** = functional residual capacity; **RV** = residual volume; **TLC** = total lung capacity; **TV** = tidal volume; **VC** = vital capacity.
©UWorld

This patient's clinical picture is consistent with **chronic obstructive pulmonary disease** (COPD), which is a combination of **chronic bronchitis** and **emphysema** and is most commonly due to heavy smoking. Patients typically have progressive dyspnea and recurrent upper respiratory infections (characteristic of chronic bronchitis).

Air trapping and airway obstruction in COPD reduce both forced expiratory volume in 1 second (FEV1) and forced vital capacity (**FVC**) on pulmonary function testing (PFT). Because the decrease in FEV1 is more profound, the **FEV1/FVC ratio** is also **reduced**, which is the hallmark of obstructive lung disease on PFT. Air trapping raises functional residual capacity, causing respiration to occur at a higher baseline lung volume. The **residual volume** (RV) is increased. **Total lung capacity** (TLC) is also **increased**.

(Choices A and B) RV and TLC values are rarely discordant; therefore, these PFT findings are unlikely to represent true clinical findings.

(Choice D) Normal RV with increased TLC can be seen in highly trained athletes due to increased vital capacity.

(Choice E) Decreased RV and TLC, along with decreased FVC and increased or normal FEV1/FVC ratio, are seen with restrictive lung disease (eg, pulmonary fibrosis). FEV1 decreases in this setting but to a lesser extent than FVC.

Educational objective:
Chronic obstructive pulmonary disease is a combination of emphysema and chronic bronchitis and commonly presents with progressive dyspnea and recurrent upper respiratory infections. Bronchial obstruction and alveolar destruction cause air trapping that manifests on pulmonary function testing as decreased forced expiratory volume in 1 second (FEV1), forced vital capacity (FVC), and FEV1/FVC ratio. Residual volume and total lung capacity are increased.

Pathophysiology	Pulmonary & Critical Care	COPD
Subject	System	Topic

Copyright © UWorld. All rights reserved.

A 28-year-old previously healthy man comes to the urgent care clinic due to shortness of breath. The patient is on a ski vacation in Breckenridge, Colorado, which is situated at an altitude of 2926 m (9600 ft). On arrival 4 days ago, he experienced mild headache and nausea that resolved spontaneously, but since yesterday, he has had worsening dyspnea and cough. The patient now feels short of breath even with minimal exertion. Temperature is 37.3 C (99.1) F, blood pressure is 134/82 mm Hg, pulse is 98/min, and respirations are 22/min. Oxygen saturation is 86% on ambient air, which rapidly improves to 95% with supplemental oxygen. Physical examination shows pink mucous membranes, flat neck veins, bilateral inspiratory crackles, and no heart murmurs or pedal edema. Chest x-ray reveals patchy alveolar infiltrates. Which of the following is the most likely cause of this patient's current condition?

A. Alveolar-capillary membrane disruption

B. Embolic pulmonary arterial occlusion

C. Excessive decrease in $PaCO_2$ level

D. Impaired left ventricular function

E. Increased total red blood cell mass

Submit

A 28-year-old previously healthy man comes to the urgent care clinic due to shortness of breath. The patient is on a ski vacation in Breckenridge, Colorado, which is situated at an altitude of 2926 m (9600 ft). On arrival 4 days ago, he experienced mild headache and nausea that resolved spontaneously, but since yesterday, he has had worsening dyspnea and cough. The patient now feels short of breath even with minimal exertion. Temperature is 37.3 C (99.1) F, blood pressure is 134/82 mm Hg, pulse is 98/min, and respirations are 22/min. Oxygen saturation is 86% on ambient air, which rapidly improves to 95% with supplemental oxygen. Physical examination shows pink mucous membranes, flat neck veins, bilateral inspiratory crackles, and no heart murmurs or pedal edema. Chest x-ray reveals patchy alveolar infiltrates. Which of the following is the most likely cause of this patient's current condition?

- ✓ A. Alveolar-capillary membrane disruption (45%)
- B. Embolic pulmonary arterial occlusion (5%)
- C. Excessive decrease in $PaCO_2$ level (26%)
- D. Impaired left ventricular function (5%)
- E. Increased total red blood cell mass (17%)

Omitted
Correct answer
A

45%
Answered correctly

02 secs
Time Spent

05/09/2020
Last Updated

Explanation

High-altitude illness	

Explanation

High-altitude illness	
Pathogenesis	• Reduced PiO_2 at high altitude (>2,500 m [~8000 ft])
Physiologic responses	• Hyperventilation: helps ↑ PaO_2 but causes ↓ $PaCO_2$ • Erythrocytes: ↑ 2,3-BPG production (↑ O_2 unloading in tissues) • Kidneys: ↑ Erythropoietin production & ↑ HCO_3^- excretion

Complications	• Acute mountain sickness
	  ◦ Headache, fatigue, nausea
	• Cerebral edema (↓ PaO_2 → ↑ cerebral blood flow)
	  ◦ Lethargy, confusion, gait disturbance
	• Pulmonary edema (unbalanced hypoxic vasoconstriction)
	  ◦ Dyspnea, cough ± hemoptysis, respiratory distress

2,3-BPG = 2,3-bisphosphoglycerate; **PiO_2** = partial pressure of inspired oxygen.

This patient with dyspnea, hypoxemia, and patchy alveolar infiltrates shortly after arriving at high altitude likely has **high-altitude pulmonary edema** (HAPE). HAPE can occur within several days of arrival at an altitude >2,500 m (~8,000 ft), with the risk increasing as altitude increases. The pathophysiology is driven by the **reduced partial pressure of oxygen** (PiO_2) at high altitude, which leads to **hypoxic pulmonary vasoconstriction** and consequent **increased pulmonary arterial pressure**. In some individuals with genetic predisposition, the hypoxic vasoconstriction is unevenly distributed, exposing the capillary beds in relatively less vasoconstricted areas to high perfusion pressure. This causes **alveolar-capillary membrane disruption** and leads to patchy, bilateral pulmonary edema.

HAPE typically presents with dyspnea (progressive over 1-2 days) and cough (sometimes with hemoptysis). Accompanying symptoms of **acute mountain sickness** (eg, headache, nausea) are often present, and physical examination reveals bilateral lung crackles. The **hypoxemia**

This patient with dyspnea, hypoxemia, and patchy alveolar infiltrates shortly after arriving at high altitude likely has **high-altitude pulmonary edema** (HAPE). HAPE can occur within several days of arrival at an altitude >2,500 m (~8,000 ft), with the risk increasing as altitude increases. The pathophysiology is driven by the **reduced partial pressure of oxygen** (PiO_2) at high altitude, which leads to **hypoxic pulmonary vasoconstriction** and consequent **increased pulmonary arterial pressure**. In some individuals with genetic predisposition, the hypoxic vasoconstriction is unevenly distributed, exposing the capillary beds in relatively less vasoconstricted areas to high perfusion pressure. This causes **alveolar-capillary membrane disruption** and leads to patchy, bilateral pulmonary edema.

HAPE typically presents with dyspnea (progressive over 1-2 days) and cough (sometimes with hemoptysis). Accompanying symptoms of **acute mountain sickness** (eg, headache, nausea) are often present, and physical examination reveals bilateral lung crackles. The **hypoxemia** characteristically **improves with supplemental oxygen** (likely due to alleviation of pulmonary vasoconstriction), which differentiates HAPE from other causes of diffuse pulmonary edema. Although potentially fatal, HAPE usually resolves rapidly upon descent to lower altitudes.

(Choice B) Acute pulmonary embolism causes dyspnea and hypoxemia; however, jugular venous distension and an absence of pulmonary edema (eg, no ausculatory crackles, clear lungs on chest x-ray) are also expected.

(Choice C) Hyperventilation leading to reduced $PaCO_2$ and respiratory alkalosis is expected at high altitude. An extreme drop in $PaCO_2$ can cause severe alkalosis with associated tingling, numbness, tetany, and possibly seizures, but it does not cause pulmonary edema.

(Choice D) Left ventricular function is unaffected in HAPE (the pulmonary edema is noncardiogenic). Myocardial infarction can lead to acute left ventricular dysfunction with pulmonary edema, but it would be expected to present with severe chest pain and to cause jugular venous distension.

(Choice E) In response to the reduced PiO_2 at high altitude, the body increases erythrocyte production to increase O_2-carrying capacity. However, this secondary polycythemia does not contribute to pulmonary edema.

Educational objective:
High-altitude pulmonary edema presents with dyspnea and cough within several days of arrival at high altitude. It is driven by reduced ambient oxygen, which leads to hypoxic pulmonary vasoconstriction and pulmonary arterial hypertension. Individuals with unevenly distributed pulmonary vasoconstriction can develop areas of high capillary perfusion pressure that disrupts the alveolar-capillary membrane, leading to patchy, bilateral pulmonary edema.

Settings

1 2 3 4 5 6 7 8 9 10 11 12 13 14 15 16 17 18 19 20 21 22 23 24 25 26 27 28 29 30

Item 32 of 40
Question Id: 18938

Mark | Previous | Next | Full Screen | Tutorial | Lab Values | Notes | Calculator | Reverse Color | Text Zoom | Settings

Exhibit Display

Bilateral pulmonary edema

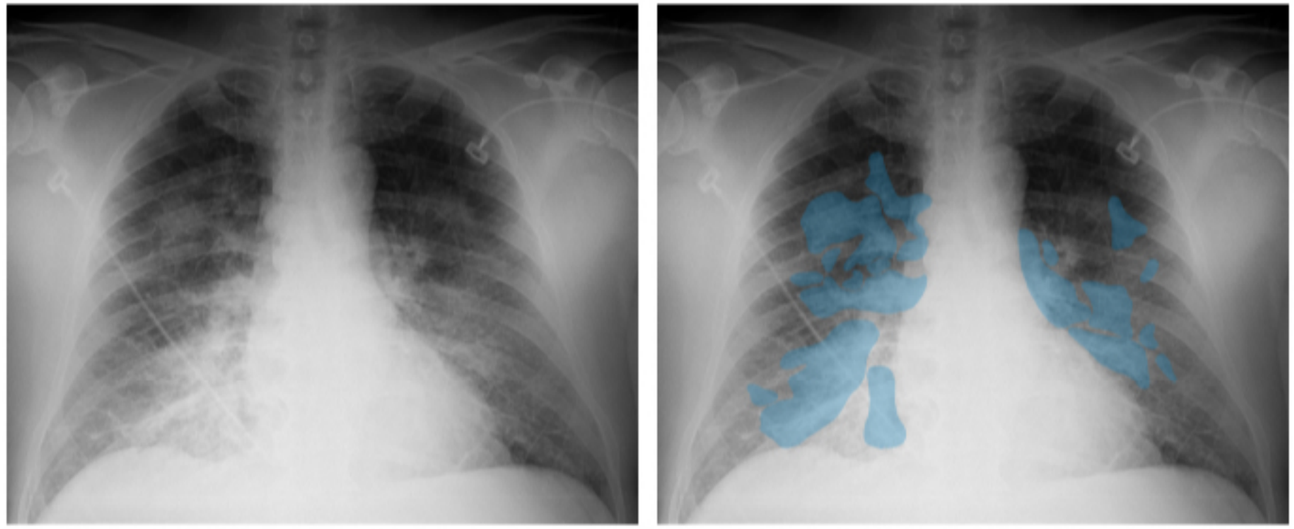

©UWorld

Zoom In | Zoom Out | Reset | Add To Flash Card

Block Time Remaining: 00:01:32
TUTOR

0 | Feedback | Suspend | End Block

HAPE typically presents with dyspnea (progressive over 1-2 days) and cough (sometimes with hemoptysis). Accompanying symptoms of **acute mountain sickness** (eg, headache, nausea) are often present, and physical examination reveals bilateral lung crackles. The **hypoxemia** characteristically **improves with supplemental oxygen** (likely due to alleviation of pulmonary vasoconstriction), which differentiates HAPE from other causes of diffuse pulmonary edema. Although potentially fatal, HAPE usually resolves rapidly upon descent to lower altitudes.

(Choice B) Acute pulmonary embolism causes dyspnea and hypoxemia; however, jugular venous distension and an absence of pulmonary edema (eg, no ausculatory crackles, clear lungs on chest x-ray) are also expected.

(Choice C) Hyperventilation leading to reduced $PaCO_2$ and respiratory alkalosis is expected at high altitude. An extreme drop in $PaCO_2$ can cause severe alkalosis with associated tingling, numbness, tetany, and possibly seizures, but it does not cause pulmonary edema.

(Choice D) Left ventricular function is unaffected in HAPE (the pulmonary edema is noncardiogenic). Myocardial infarction can lead to acute left ventricular dysfunction with pulmonary edema, but it would be expected to present with severe chest pain and to cause jugular venous distension.

(Choice E) In response to the reduced PiO_2 at high altitude, the body increases erythrocyte production to increase O_2-carrying capacity. However, this secondary polycythemia does not contribute to pulmonary edema.

Educational objective:
High-altitude pulmonary edema presents with dyspnea and cough within several days of arrival at high altitude. It is driven by reduced ambient oxygen, which leads to hypoxic pulmonary vasoconstriction and pulmonary arterial hypertension. Individuals with unevenly distributed pulmonary vasoconstriction can develop areas of high capillary perfusion pressure that disrupts the alveolar-capillary membrane, leading to patchy, bilateral pulmonary edema.

References

- Update on high-altitude pulmonary edema: pathogenesis, prevention, and treatment.

Pathophysiology	Pulmonary & Critical Care	High altitude illness
Subject	System	Topic

Copyright © UWorld. All rights reserved.

A 68-year-old man comes to the office for gradually increasing shortness of breath. He initially experienced symptoms with exertion but now feels short of breath at rest. The patient has smoked 2 packs of cigarettes per day for 40 years. Blood pressure is 138/78 mm Hg, pulse is 80/min, and respirations are 22/min. The chest x-ray is shown in the image below:

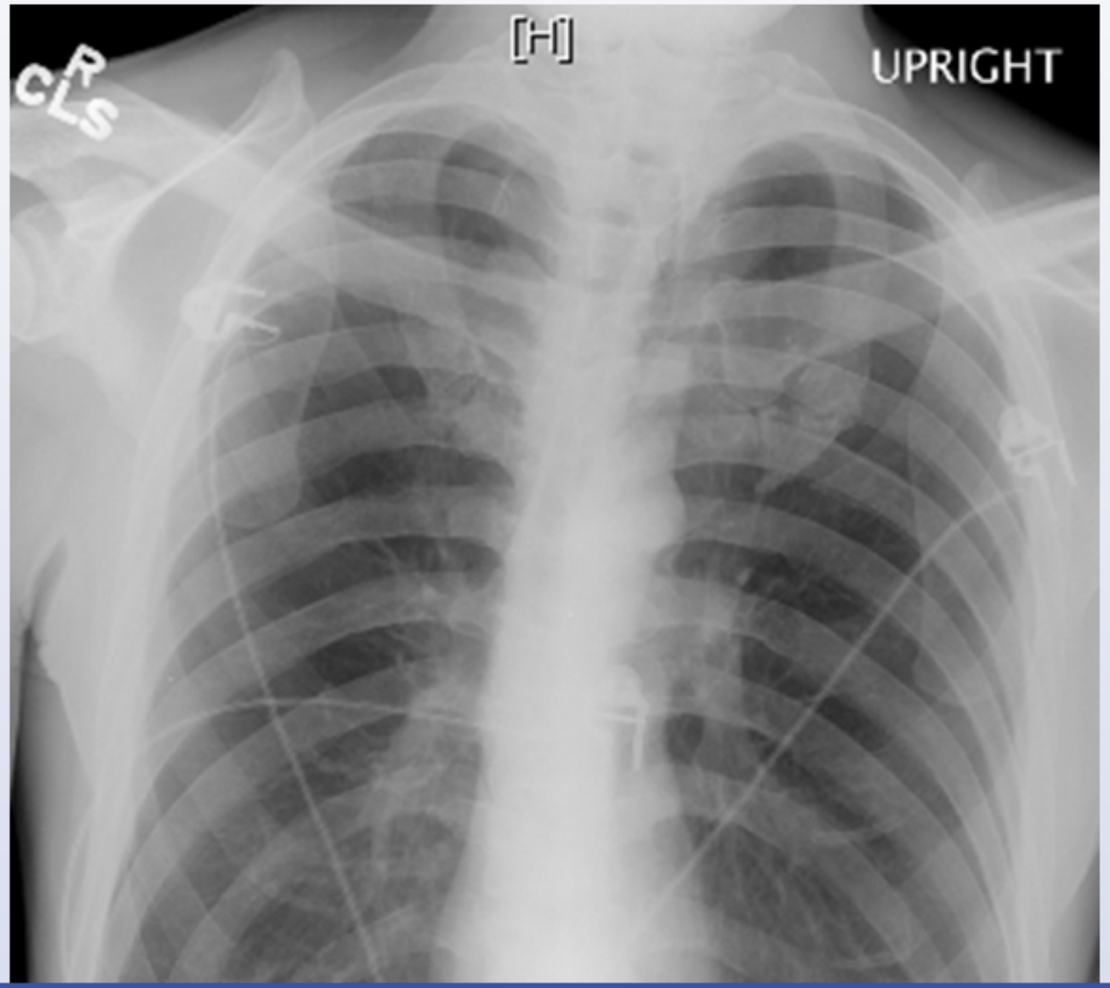

Settings

1
2
3
4
5
6
7
8
9
10
11
12
13
14
15
16
17
18
19
20
21
22
23
24
25
26
27
28
29
30

Item 33 of 40
Question Id: 15233

Mark

Previous

Next

Full Screen

Tutorial

Lab Values

Notes

Calculator

Reverse Color

Text Zoom

Settings

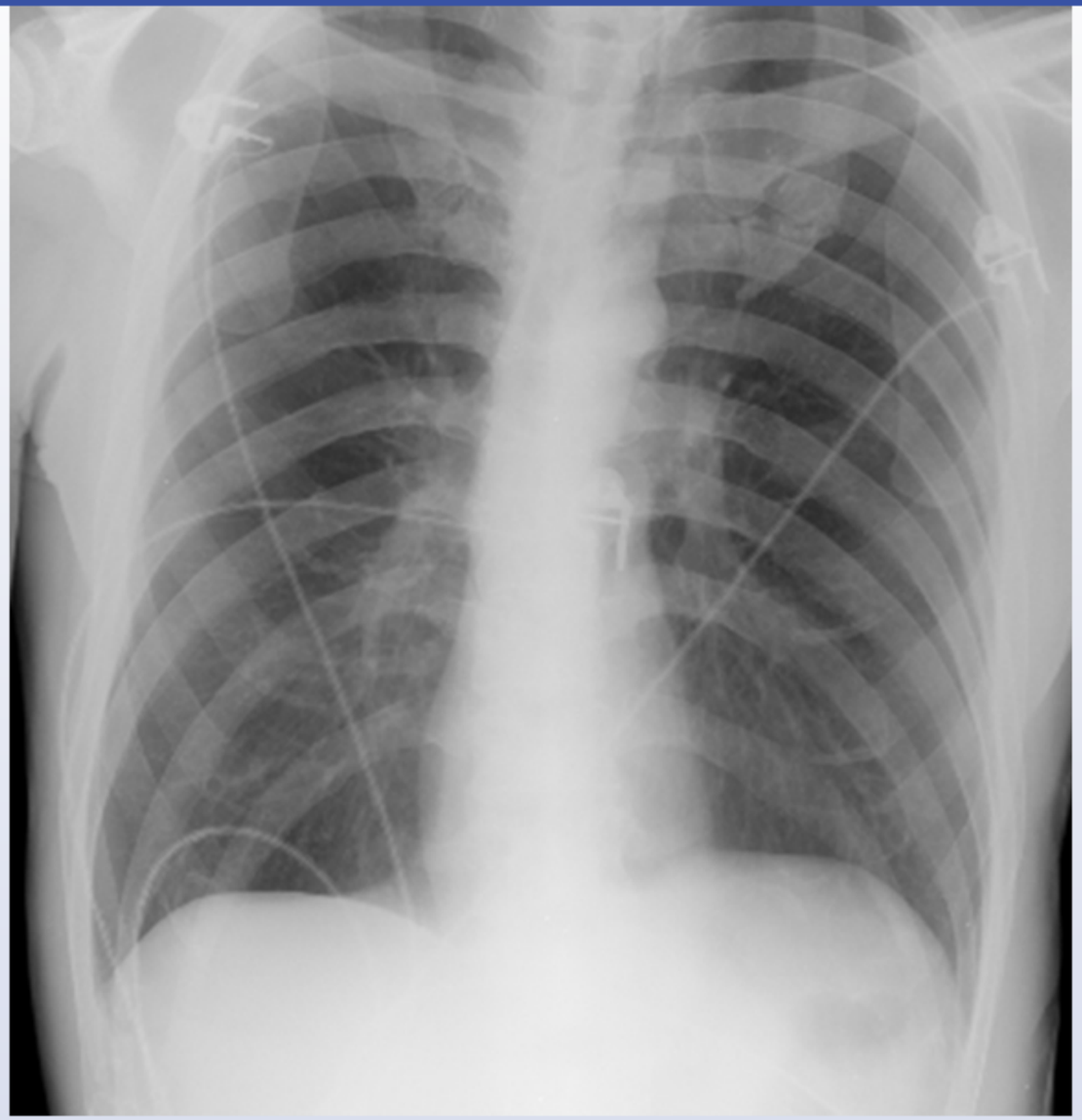

Block Time Remaining: 00:01:38
TUTOR

Feedback

Suspend

End Block

Settings

1 2 3 4 5 6 7 8 9 10 11 12 13 14 15 16 17 18 19 20 21 22 23 24 25 26 27 28 29 30

Item 33 of 40
Question Id: 15233

Mark | Previous | Next | Full Screen | Tutorial | Lab Values | Notes | Calculator | Reverse Color | Text Zoom | Settings

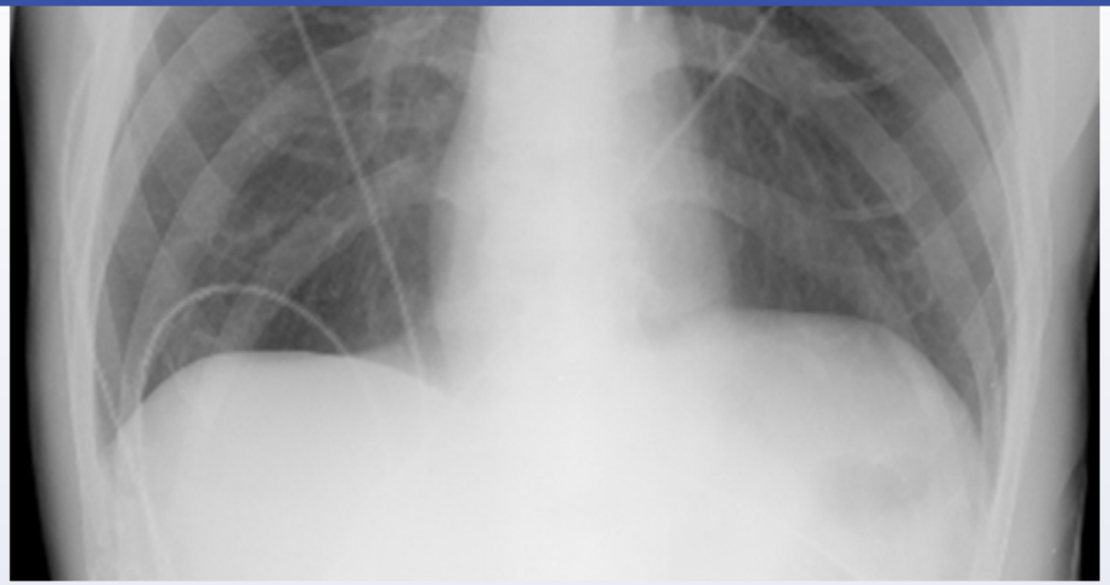

Which of the following measures is most likely increased in this patient?

- A. Diffusing capacity of the lung for carbon monoxide
- B. Forced expiratory volume in 1 second
- C. Forced expiratory volume in 1 second/forced vital capacity ratio
- D. Forced vital capacity
- E. Residual volume/total lung capacity ratio

Submit

Block Time Remaining: 00:01:41
TUTOR

Feedback | Suspend | End Block

Settings

1 2 3 4 5 6 7 8 9 10 11 12 13 14 15 16 17 18 19 20 21 22 23 24 25 26 27 28 29 30

Item 33 of 40
Question Id: 15233

Mark | Previous | Next | Full Screen | Tutorial | Lab Values | Notes | Calculator | Reverse Color | Text Zoom | Settings

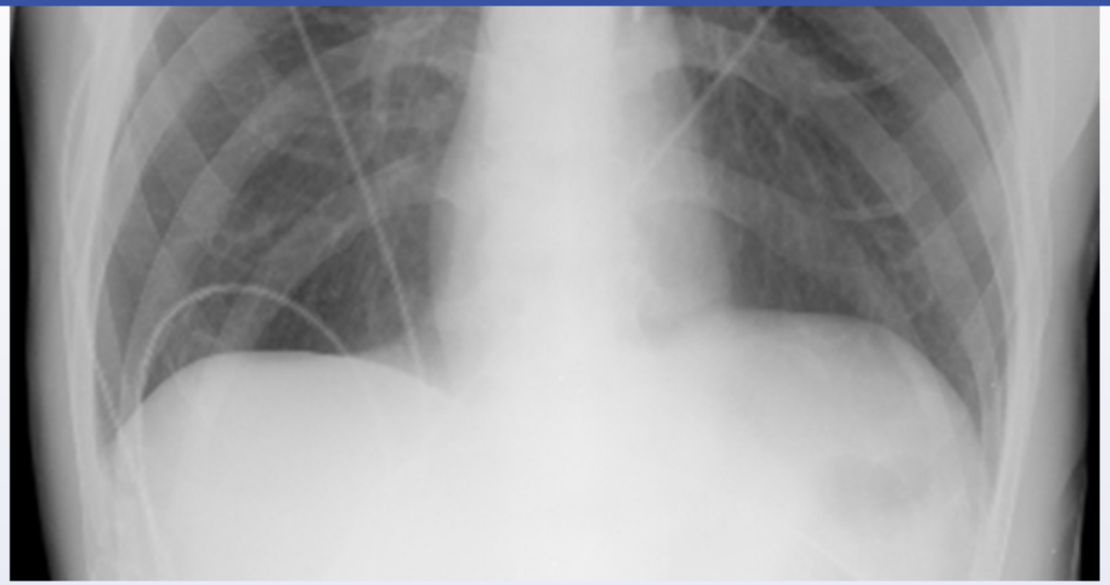

Which of the following measures is most likely increased in this patient?

A. Diffusing capacity of the lung for carbon monoxide (3%)

B. Forced expiratory volume in 1 second (1%)

C. Forced expiratory volume in 1 second/forced vital capacity ratio (7%)

D. Forced vital capacity (4%)

✓ E. Residual volume/total lung capacity ratio (83%)

Omitted
Correct answer

83%
Answered correctly

11 secs
Time Spent

06/01/2020
Last Updated

Block Time Remaining: 00:01:43
TUTOR

1 | Feedback | Suspend | End Block

Explanation

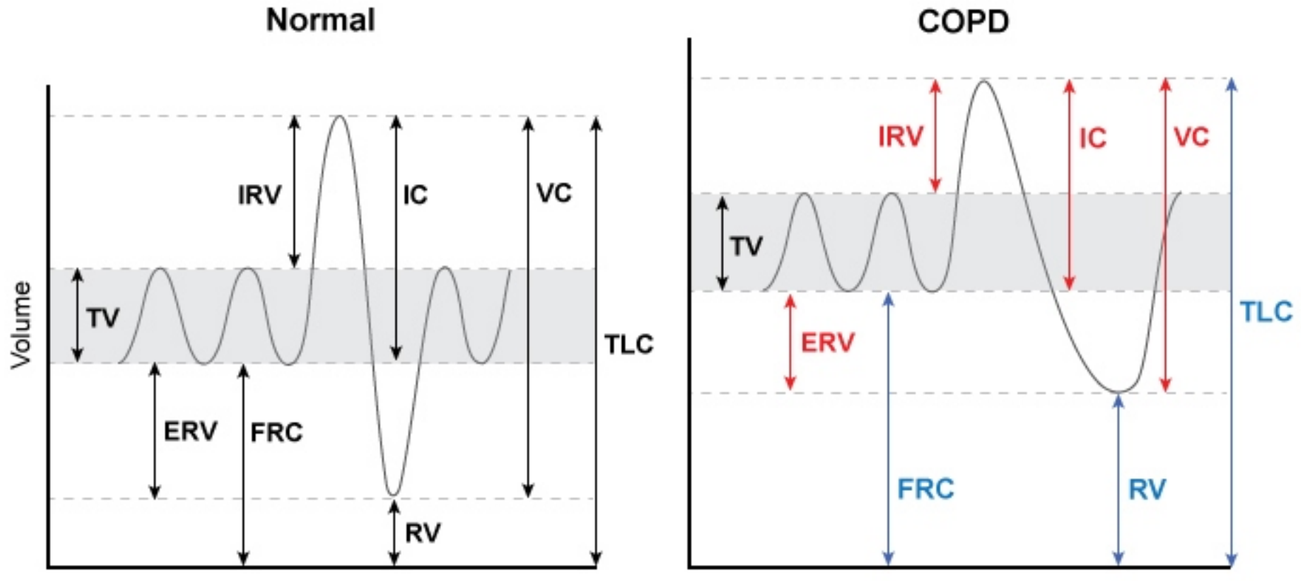

COPD = chronic obstructive pulmonary disease; **ERV** = expiratory reserve volume; **IC** = inspiratory capacity; **IRV** = inspiratory reserve volume; **FRC** = functional residual capacity; **RV** = residual volume; **TLC** = total lung capacity; **TV** = tidal volume; **VC** = vital capacity.

©UWorld

This patient's presentation with progressive shortness of breath, significant smoking history, and **hyperinflation** on chest x-ray (flattened diaphragm, narrowed mediastinum) is consistent with **chronic obstructive pulmonary disease** (COPD).

COPD causes air trapping and hyperinflation of the lungs, so these patients breathe at higher baseline lung volumes (**higher functional residual capacity**). The volume of air in the lungs that is not respired, the **residual volume** (RV), is substantially **increased**. The **total lung capacity** (TLC) **increases** as well, but to a lesser extent than RV. Therefore, the fraction of air in the lungs that is not involved in respiration, the **RV/TLC ratio**, is also **increased**. A high RV/TLC ratio correlates with poor outcomes in patients with COPD.

(Choice A) Diffusing capacity of the lung for carbon monoxide (DLCO) is decreased in COPD due to emphysematous destruction of the alveolar-

COPD = chronic obstructive pulmonary disease; **ERV** = expiratory reserve volume; **IC** = inspiratory capacity; **IRV** = inspiratory reserve volume; **FRC** = functional residual capacity; **RV** = residual volume; **TLC** = total lung capacity; **TV** = tidal volume; **VC** = vital capacity.
©UWorld

This patient's presentation with progressive shortness of breath, significant smoking history, and **hyperinflation** on chest x-ray (flattened diaphragm, narrowed mediastinum) is consistent with **chronic obstructive pulmonary disease** (COPD).

COPD causes air trapping and hyperinflation of the lungs, so these patients breathe at higher baseline lung volumes (**higher functional residual capacity**). The volume of air in the lungs that is not respired, the **residual volume** (RV), is substantially **increased**. The **total lung capacity** (TLC) **increases** as well, but to a lesser extent than RV. Therefore, the fraction of air in the lungs that is not involved in respiration, the **RV/TLC ratio**, is also **increased**. A high RV/TLC ratio correlates with poor outcomes in patients with COPD.

(Choice A) Diffusing capacity of the lung for carbon monoxide (DLCO) is decreased in COPD due to emphysematous destruction of the alveolar-arterial membrane.

(Choices B, C, and D) Both forced vital capacity (FVC) and forced expiratory volume in 1 second (FEV1) are decreased in COPD due to airway obstruction. Because FEV1 is decreased more than FVC, the FEV1/FVC ratio is also decreased (<0.7 in COPD).

Educational objective:
Chronic obstructive pulmonary disease causes air trapping and hyperinflation; consequently, these patients breathe at higher baseline lung volumes (higher functional residual capacity). The volume of air in the lungs that is not respired (residual volume) increases substantially, as does the fraction of air in the lungs that is not involved in respiration (residual volume/total lung capacity ratio).

References

- The prognostic value of residual volume/total lung capacity in patients with chronic obstructive pulmonary disease.

Pathophysiology	Pulmonary & Critical Care	COPD
Subject	System	Topic

Copyright © UWorld. All rights reserved.

A 1-month-old boy is brought to the office on a hot summer day due to vomiting and excessive sleepiness. He had been exclusively breastfeeding with normal feeding patterns until this afternoon, when he had 2 episodes of emesis and appeared much sleepier than usual. The infant was born at 41 weeks gestation after an unremarkable pregnancy. Newborn screening was positive for a homozygous ΔF508 mutation affecting an epithelial transmembrane protein; further confirmatory testing is pending. Physical examination shows a somnolent boy with a sunken fontanelle and dry mucous membranes. Which of the following electrolyte disturbances is most likely responsible for this patient's current symptoms?

A. Hyperchloremia
B. Hyperkalemia
C. Hypernatremia
D. Hypomagnesemia
E. Hyponatremia

Submit

A 1-month-old boy is brought to the office on a hot summer day due to vomiting and excessive sleepiness. He had been exclusively breastfeeding with normal feeding patterns until this afternoon, when he had 2 episodes of emesis and appeared much sleepier than usual. The infant was born at 41 weeks gestation after an unremarkable pregnancy. Newborn screening was positive for a homozygous ΔF508 mutation affecting an epithelial transmembrane protein; further confirmatory testing is pending. Physical examination shows a somnolent boy with a sunken fontanelle and dry mucous membranes. Which of the following electrolyte disturbances is most likely responsible for this patient's current symptoms?

- A. Hyperchloremia (23%)
- B. Hyperkalemia (2%)
- C. Hypernatremia (19%)
- D. Hypomagnesemia (1%)
- ✓ E. Hyponatremia (52%)

Omitted
Correct answer
E

52%
Answered correctly

03 secs
Time Spent

01/12/2020
Last Updated

Explanation

Sweat ducts

Normal	Cystic fibrosis

Sweat ducts

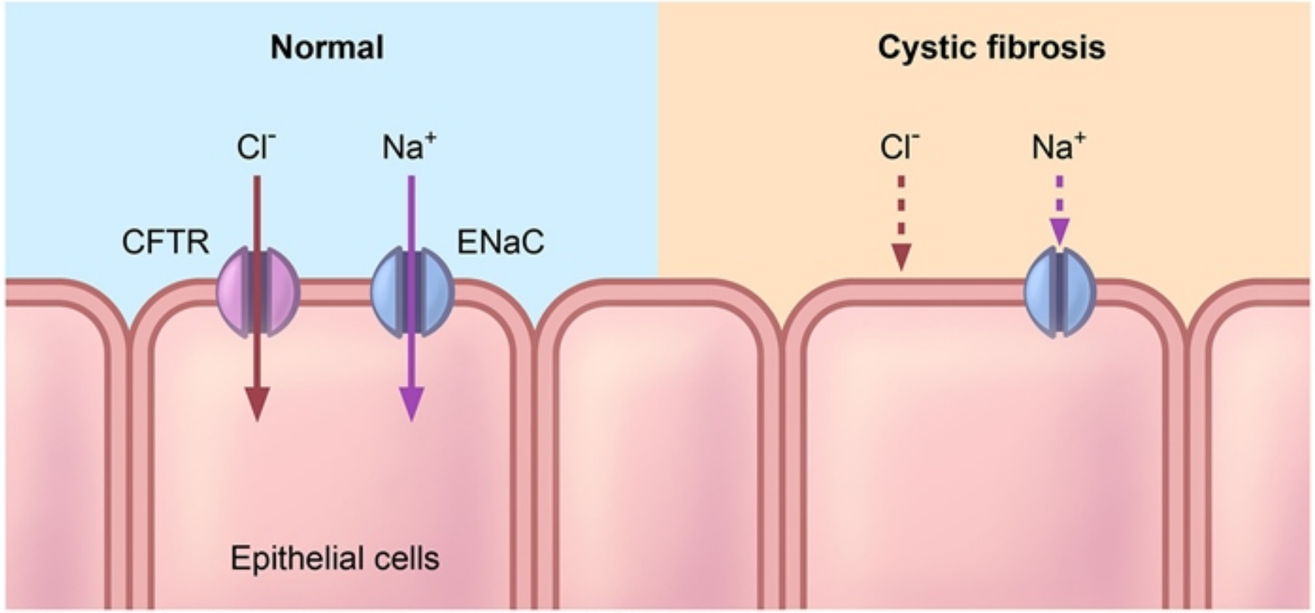

CFTR = cystic fibrosis transmembrane conductance regulator; **ENaC** = epithelial sodium channel.

©UWorld

The **ΔF508 mutation** in the cystic fibrosis transmembrane conductance regulator (**CFTR**) protein is the most common mutation in patients with **cystic fibrosis** (CF). In unaffected individuals, the CFTR protein serves as a chloride channel that regulates the flow of sodium, chloride, and water across the epithelial membranes of the airways, biliary tree, intestines, sweat ducts, and pancreatic ducts.

Newborn screening for CF is performed in the United States, but positive results should be confirmed by **sweat testing**. When eccrine sweat is first produced, it is isotonic with extracellular fluid. As sweat travels through the eccrine duct to the skin's surface, chloride is normally resorbed via CFTR, and sodium and water follow. CFTR facilitates production of hypotonic sweat in patients without CF. However, patients with CF are unable to reabsorb chloride and sodium in the eccrine ducts and therefore secrete **sweat with high sodium and chloride** levels.

The most likely cause of this patient's symptoms (lethargy, vomiting) is **hyponatremia due to excessive salt wasting** from his sweat. Risk

The **ΔF508 mutation** in the cystic fibrosis transmembrane conductance regulator (**CFTR**) protein is the most common mutation in patients with **cystic fibrosis** (CF). In unaffected individuals, the CFTR protein serves as a chloride channel that regulates the flow of sodium, chloride, and water across the epithelial membranes of the airways, biliary tree, intestines, sweat ducts, and pancreatic ducts.

Newborn screening for CF is performed in the United States, but positive results should be confirmed by **sweat testing**. When eccrine sweat is first produced, it is isotonic with extracellular fluid. As sweat travels through the eccrine duct to the skin's surface, chloride is normally resorbed via CFTR, and sodium and water follow. CFTR facilitates production of hypotonic sweat in patients without CF. However, patients with CF are unable to reabsorb chloride and sodium in the eccrine ducts and therefore secrete **sweat with high sodium and chloride** levels.

The most likely cause of this patient's symptoms (lethargy, vomiting) is **hyponatremia due to excessive salt wasting** from his sweat. Risk factors for hyponatremia in patients with CF include exclusive breast or formula feeding prior to the introduction of sodium-rich, solid foods; exposure to high-temperature environments; and exercise. Therefore, **salt supplementation** is recommended for patients with CF.

(Choice A) Chloride ions are an important contributor to extracellular fluid volume, and hypochloremia is also very common in patients with CF due to sweat losses. In contrast, hyperchloremia is more likely to develop in normal patients with excessive sweating due to increased free water loss from hypotonic sweat.

(Choice B) Hyperkalemia typically occurs with cell lysis (eg, rhabdomyolysis, tumor lysis syndrome), metabolic acidosis (due to intracellular to extracellular K^+ shift), or abnormalities with renal excretion.

(Choice C) Hypernatremia classically occurs with excessive salt intake or free water loss (eg, diarrhea, diabetes insipidus, improperly prepared infant formula). Patients with CF typically do not experience hypernatremia as they lose excess sodium through their sweat glands.

(Choice D) Hypomagnesemia most commonly arises from urinary loss due to medications (eg, loop diuretics), alcohol use, or uncontrolled diabetes mellitus with polyuria.

Educational objective:
Patients with cystic fibrosis (CF) produce eccrine sweat with higher-than-normal concentrations of sodium and chloride. Exposure to high temperature or exercise can lead to hyponatremia and hypochloremia due to excessive sodium chloride loss through sweat; therefore, salt supplementation is recommended.

A 64-year-old woman comes to the emergency department with a 4-day history of productive cough and breathlessness. Her medical conditions include polymyalgia rheumatica, for which she takes low-dose prednisone. Physical examination shows dullness to percussion and decreased breath sounds over the right lower lobe. The abdomen is soft, nondistended, and nontender. Chest x-ray shows a right lower lobe parenchymal opacity and a moderate right pleural effusion. Thoracentesis is performed, yielding serosanguinous fluid. Pleural fluid and serum findings are as follows:

	Pleural fluid	Serum
Total protein	4.5 g/dL	6.5 g/dL
Lactate dehydrogenase	40 U/L	60 U/L

Which of the following is contributing most to the pathogenesis of this patient's pleural effusion?

- A. Decreased plasma oncotic pressure
- B. Decreased thoracic lymphatic flow
- C. Increased intraabdominal hydrostatic pressure
- D. Increased intrapleural negative pressure
- E. Increased pleural vascular permeability
- F. Increased thoracic hydrostatic pressure

Submit

A 64-year-old woman comes to the emergency department with a 4-day history of productive cough and breathlessness. Her medical conditions include polymyalgia rheumatica, for which she takes low-dose prednisone. Physical examination shows dullness to percussion and decreased breath sounds over the right lower lobe. The abdomen is soft, nondistended, and nontender. Chest x-ray shows a right lower lobe parenchymal opacity and a moderate right pleural effusion. Thoracentesis is performed, yielding serosanguinous fluid. Pleural fluid and serum findings are as follows:

	Pleural fluid	Serum
Total protein	4.5 g/dL	6.5 g/dL
Lactate dehydrogenase	40 U/L	60 U/L

Which of the following is contributing most to the pathogenesis of this patient's pleural effusion?

A. Decreased plasma oncotic pressure (11%)
B. Decreased thoracic lymphatic flow (8%)
C. Increased intraabdominal hydrostatic pressure (1%)
D. Increased intrapleural negative pressure (2%)
✓ E. Increased pleural vascular permeability (64%)
F. Increased thoracic hydrostatic pressure (12%)

Omitted
Correct answer
E

64%
Answered correctly

03 secs
Time Spent

04/05/2020
Last Updated

Exudative & transudative pleural effusions		
	Exudate	**Transudate**
Light criteria	• Pleural fluid protein/serum protein ratio >0.5 OR • Pleural fluid LDH/serum LDH ratio >0.6 OR • Pleural fluid LDH >two-thirds upper limit of normal of serum LDH	• Exudate criteria not met
Pathophysiology	• Inflammation	• Hydrostatic or oncotic pressure
Common causes	• Infection (eg, pneumonia) • Malignancy • Rheumatologic disease	• Heart failure • Cirrhosis (hepatic hydrothorax) • Nephrotic syndrome

LDH = lactate dehydrogenase.

Under normal physiologic conditions, **pleural fluid** enters the pleural space from parietal pleural microvessels and is removed by lymphatics at a constant rate. Pathologic states that disrupt pleural capillary hydrostatic or oncotic pressure, decrease pleural space pressure, reduce lymphatic drainage, or increase vascular membrane permeability can lead to **pleural effusion**. Pleural effusions that develop due to **pressure changes** (eg, heart failure, cirrhosis, nephrotic syndrome) are typically **transudative**, whereas those that develop due to **inflammation** and consequent **increased vascular membrane permeability** (eg, infection, malignancy, rheumatologic disease), are typically **exudative**.

The Light criteria are used to differentiate transudative and exudative pleural effusions and aid in the differential diagnosis. Transudative effusions have a low fluid-to-serum ratio of total protein and lactate dehydrogenase and low absolute levels of lactate dehydrogenase. In contrast, **exudative effusions** have a **high fluid-to-serum ratio** of **total protein (>0.5)** or **lactate dehydrogenase (>0.6)** or high absolute levels of lactate dehydrogenase (>2/3 the serum upper limit of normal).

This patient with a pleural fluid-to-serum total protein ratio >0.5 has an exudative effusion likely due to pneumonia (ie, parapneumonic effusion).

Under normal physiologic conditions, **pleural fluid** enters the pleural space from parietal pleural microvessels and is removed by lymphatics at a constant rate. Pathologic states that disrupt pleural capillary hydrostatic or oncotic pressure, decrease pleural space pressure, reduce lymphatic drainage, or increase vascular membrane permeability can lead to **pleural effusion**. Pleural effusions that develop due to **pressure changes** (eg, heart failure, cirrhosis, nephrotic syndrome) are typically **transudative**, whereas those that develop due to **inflammation** and consequent **increased vascular membrane permeability** (eg, infection, malignancy, rheumatologic disease), are typically **exudative**.

The Light criteria are used to differentiate transudative and exudative pleural effusions and aid in the differential diagnosis. Transudative effusions have a low fluid-to-serum ratio of total protein and lactate dehydrogenase and low absolute levels of lactate dehydrogenase. In contrast, **exudative effusions** have a **high fluid-to-serum ratio** of **total protein (>0.5)** or **lactate dehydrogenase (>0.6)** or high absolute levels of lactate dehydrogenase (>2/3 the serum upper limit of normal).

This patient with a pleural fluid-to-serum total protein ratio >0.5 has an exudative effusion likely due to pneumonia (ie, parapneumonic effusion).

(Choice A) Decreased plasma oncotic pressure occurs in conditions that cause hypoalbuminemia (eg, cirrhosis, nephrotic syndrome) and can lead to transudative pleural effusion.

(Choice B) Decreased thoracic lymphatic flow (eg, due to malignant involvement of lymphatic ducts) can cause a chylous effusion (chylothorax). Although this type of effusion is usually exudative by Light criteria, the fluid is typically milky white (rather than serosanguinous) in gross appearance due to high triglyceride (ie, chylomicron) content.

(Choice C) Increased intraabdominal hydrostatic pressure occurs with abdominal ascites that develops due to portal hypertension (eg, cirrhosis). The ascites can be forced into the right-sided pleural cavity through fenestrations in the diaphragm, resulting in a transudative pleural effusion known as hepatic hydrothorax.

(Choice D) Increased intrapleural negative pressure occurs in large-volume atelectasis (lung collapse) and can lead to a transudative pleural effusion.

(Choice F) Increased hydrostatic pressure in the pulmonary venous system occurs in heart failure and leads to transudative pleural effusion.

Educational objective:
Transudative effusions are typically caused by alterations in hydrostatic or oncotic pressure (eg, heart failure, cirrhosis, nephrotic syndrome),

Settings

1 2 3 4 5 6 7 8 9 10 11 12 13 14 15 16 17 18 19 20 21 22 23 24 25 26 27 28 29 30

Item 35 of 40
Question Id: 15420

Mark | Previous | Next | Full Screen | Tutorial | Lab Values | Notes | Calculator | Reverse Color | Text Zoom | Settings

Exhibit Display

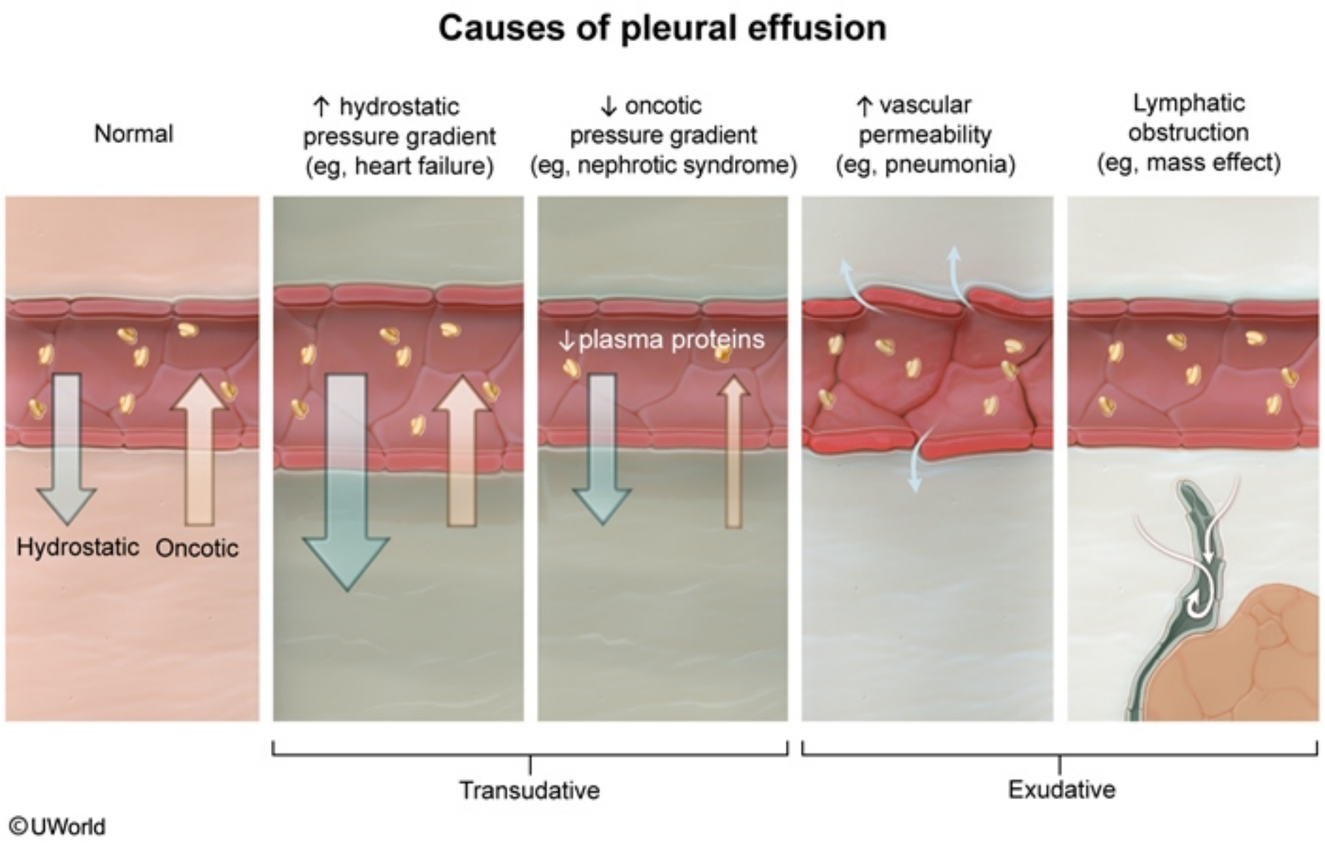

Zoom In | Zoom Out | Reset | Add To New Card | Existing Card

Transudative effusions are typically caused by alterations in hydrostatic or oncotic pressure (eg, heart failure, cirrhosis, nephrotic syndrome),

Block Time Remaining: 00:01:49
TUTOR

4 | Feedback | Suspend | End Block

This patient with a pleural fluid to serum total protein ratio > 0.6 has an exudative effusion likely due to pneumonia (ie, parapneumonic effusion).

(Choice A) Decreased plasma oncotic pressure occurs in conditions that cause hypoalbuminemia (eg, cirrhosis, nephrotic syndrome) and can lead to transudative pleural effusion.

(Choice B) Decreased thoracic lymphatic flow (eg, due to malignant involvement of lymphatic ducts) can cause a chylous effusion (chylothorax). Although this type of effusion is usually exudative by Light criteria, the fluid is typically milky white (rather than serosanguinous) in gross appearance due to high triglyceride (ie, chylomicron) content.

(Choice C) Increased intraabdominal hydrostatic pressure occurs with abdominal ascites that develops due to portal hypertension (eg, cirrhosis). The ascites can be forced into the right-sided pleural cavity through fenestrations in the diaphragm, resulting in a transudative pleural effusion known as hepatic hydrothorax.

(Choice D) Increased intrapleural negative pressure occurs in large-volume atelectasis (lung collapse) and can lead to a transudative pleural effusion.

(Choice F) Increased hydrostatic pressure in the pulmonary venous system occurs in heart failure and leads to transudative pleural effusion.

Educational objective:
Transudative effusions are typically caused by alterations in hydrostatic or oncotic pressure (eg, heart failure, cirrhosis, nephrotic syndrome), whereas exudative effusions typically result from inflammation and consequent increased vascular membrane permeability (eg, infection, malignancy, rheumatologic disease). Exudative effusions are characterized by a high ratio of pleural fluid to serum total protein (>0.5) or lactate dehydrogenase (>0.6), or high absolute levels of lactate dehydrogenase.

References

- Is the pleural fluid transudate or exudate? A revisit of the diagnostic criteria.

Pathophysiology	Pulmonary & Critical Care	Pleural effusion
Subject	System	Topic

Copyright © UWorld. All rights reserved.

A 14-year-old girl is brought to the office due to intermittent shortness of breath over the past 4 months. She is unable to link the episodes to specific events or exposures. The patient has no prior medical conditions and takes no medications. She does not smoke and has no second-hand tobacco exposure. Her family has a cat that remains indoors. There is no significant family history. Blood pressure is 110/65 mm Hg, pulse is 80/min, and respirations are 16/min. On physical examination, heart sounds are normal and the lungs are clear to auscultation. Lung function tests reveal a FEV1/FVC ratio of 83%. Which of the following would be most helpful in excluding a diagnosis of asthma in this patient?

- A. Absence of peripheral blood eosinophilia
- B. Negative allergy skin tests
- C. Negative methacholine challenge
- D. Normal chest radiography
- E. Normal total serum IgE level

Submit

A 14-year-old girl is brought to the office due to intermittent shortness of breath over the past 4 months. She is unable to link the episodes to specific events or exposures. The patient has no prior medical conditions and takes no medications. She does not smoke and has no second-hand tobacco exposure. Her family has a cat that remains indoors. There is no significant family history. Blood pressure is 110/65 mm Hg, pulse is 80/min, and respirations are 16/min. On physical examination, heart sounds are normal and the lungs are clear to auscultation. Lung function tests reveal a FEV1/FVC ratio of 83%. Which of the following would be most helpful in excluding a diagnosis of asthma in this patient?

- A. Absence of peripheral blood eosinophilia (1%)
- B. Negative allergy skin tests (1%)
- ✓ C. Negative methacholine challenge (93%)
- D. Normal chest radiography (0%)
- E. Normal total serum IgE level (2%)

Omitted
Correct answer
C

93%
Answered correctly

03 secs
Time Spent

05/14/2020
Last Updated

Explanation

Asthma is a disease of airway inflammation and bronchial hyperreactivity, with **variable airflow obstruction** that improves with bronchodilator medications. Classic symptoms include cough, shortness of breath, and wheeze, although these are nonspecific. Most patients with asthma have a chronic reduction in the FEV1/FVC ratio (≤70%; normal ~80%) due to increased expiratory airflow resistance. However, asymptomatic patients may have normal lung function tests, with alterations in lung function occurring only during exacerbations. This patient with intermittent shortness of breath has a normal FEV1/FVC ratio, therefore, further studies are required to exclude the diagnosis of asthma.

Explanation

Asthma is a disease of airway inflammation and bronchial hyperreactivity, with **variable airflow obstruction** that improves with bronchodilator medications. Classic symptoms include cough, shortness of breath, and wheeze, although these are nonspecific. Most patients with asthma have a chronic reduction in the FEV1/FVC ratio (≤70%; normal ~80%) due to increased expiratory airflow resistance. However, asymptomatic patients may have normal lung function tests, with alterations in lung function occurring only during exacerbations. This patient with intermittent shortness of breath has a normal FEV1/FVC ratio, therefore, further studies are required to exclude the diagnosis of asthma.

Bronchial challenge testing is a highly sensitive test with **high negative predictive value** used to assess **bronchial hyperreactivity** and exclude asthma. A provocative stimulus (typically aerosolized **methacholine**, a cholinergic muscarinic agonist) is administered at increasing concentrations to induce bronchoconstriction. Patients with asthma are hyperresponsive to this stimulus and experience a decline in FEV1 at lower doses than nonasthmatics. However, the test is nonspecific and positive results may also be seen with chronic obstructive pulmonary disease, cystic fibrosis, and allergic rhinitis.

(Choice A) Although peripheral eosinophil counts may be elevated in asthmatics, the presence of eosinophilia is not a sensitive or specific indicator of asthma and may be seen in other allergic diseases (eg, allergic rhinitis, drug reactions), parasitic infections (eg, strongyloides), and certain myeloid neoplasms.

(Choice B) Most patients with asthma are sensitive to a variety of inhaled allergens, and in such patients, skin tests to various allergens will provoke a localized, immediate, type I hypersensitivity reaction. However, patients may have allergic disease without asthma and patients with nonallergic (intrinsic) asthma may not have allergies; therefore this test is not useful for diagnosing asthma.

(Choice D) During an asthma attack, the lungs may appear hyperinflated on chest x-ray. However, chest x-rays are often normal between attacks; therefore, a chest x-ray cannot exclude asthma.

(Choice E) Although serum IgE levels are generally elevated in patients with allergic asthma, patients with nonimmune-mediated asthma have normal levels of serum IgE. Intrinsic asthma can be precipitated by pulmonary infections (especially viral), aspirin ingestion, cold air, inhaled irritants (eg, perfumes), stress, and exercise.

Educational objective:
Bronchial challenge testing is a highly sensitive but nonspecific measure that can help exclude a diagnosis of asthma. A provocative stimulus

exclude asthma. A provocative stimulus (typically aerosolized **methacholine**, a cholinergic muscarinic agonist) is administered at increasing concentrations to induce bronchoconstriction. Patients with asthma are hyperresponsive to this stimulus and experience a decline in FEV1 at lower doses than nonasthmatics. However, the test is nonspecific and positive results may also be seen with chronic obstructive pulmonary disease, cystic fibrosis, and allergic rhinitis.

(Choice A) Although peripheral eosinophil counts may be elevated in asthmatics, the presence of eosinophilia is not a sensitive or specific indicator of asthma and may be seen in other allergic diseases (eg, allergic rhinitis, drug reactions), parasitic infections (eg, strongyloides), and certain myeloid neoplasms.

(Choice B) Most patients with asthma are sensitive to a variety of inhaled allergens, and in such patients, skin tests to various allergens will provoke a localized, immediate, type I hypersensitivity reaction. However, patients may have allergic disease without asthma and patients with nonallergic (intrinsic) asthma may not have allergies; therefore this test is not useful for diagnosing asthma.

(Choice D) During an asthma attack, the lungs may appear hyperinflated on chest x-ray. However, chest x-rays are often normal between attacks; therefore, a chest x-ray cannot exclude asthma.

(Choice E) Although serum IgE levels are generally elevated in patients with allergic asthma, patients with nonimmune-mediated asthma have normal levels of serum IgE. Intrinsic asthma can be precipitated by pulmonary infections (especially viral), aspirin ingestion, cold air, inhaled irritants (eg, perfumes), stress, and exercise.

Educational objective:
Bronchial challenge testing is a highly sensitive but nonspecific measure that can help exclude a diagnosis of asthma. A provocative stimulus (typically aerosolized methacholine) is administered at increasing concentrations to induce bronchoconstriction. Patients with asthma are hyperresponsive to this stimulus and experience a decline in FEV1 at lower doses than nonasthmatics.

Pathophysiology	Pulmonary & Critical Care	Asthma
Subject	System	Topic

Copyright © UWorld. All rights reserved.

A 38-year-old man comes to the office with reports of dyspnea on exertion and decreased exercise tolerance. His medical history is unremarkable, and he has no history of childhood asthma or cough. He has never smoked and has no known occupational exposures. The patient has gained almost 100 lb over the past 4 years since leaving the military due to a sedentary lifestyle. He currently weighs 135 kg (297.6 lb) and has a BMI of 41 kg/m^2. His respiratory rate is 22/min and pulse oximetry is 93% on room air at rest. Physical examination is notable for central obesity. Lungs are clear on auscultation bilaterally. Which of the following changes (forced expiratory volume in 1 second [FEV_1], forced vital capacity [FVC], expiratory reserve volume [ERV], residual volume [RV], and total lung capacity [TLC]) are most likely to be seen on pulmonary function testing in this patient?

	FEV_1	FVC	ERV	RV	TLC
A.	↓	↓	↓	Normal	↓
B.	↓	↓	Normal	↑	↑
C.	↓	Normal	Normal	↑	↑
D.	↑	↑	↓	Normal	Normal
E.	↑	Normal	↑	↑	↑

Submit

A 38-year-old man comes to the office with reports of dyspnea on exertion and decreased exercise tolerance. His medical history is unremarkable, and he has no history of childhood asthma or cough. He has never smoked and has no known occupational exposures. The patient has gained almost 100 lb over the past 4 years since leaving the military due to a sedentary lifestyle. He currently weighs 135 kg (297.6 lb) and has a BMI of 41 kg/m^2. His respiratory rate is 22/min and pulse oximetry is 93% on room air at rest. Physical examination is notable for central obesity. Lungs are clear on auscultation bilaterally. Which of the following changes (forced expiratory volume in 1 second [FEV_1], forced vital capacity [FVC], expiratory reserve volume [ERV], residual volume [RV], and total lung capacity [TLC]) are most likely to be seen on pulmonary function testing in this patient?

	FEV_1	FVC	ERV	RV	TLC
✓ A. (63%)	↓	↓	↓	Normal	↓
B. (15%)	↓	↓	Normal	↑	↑
C. (6%)	↓	Normal	Normal	↑	↑
D. (12%)	↑	↑	↓	Normal	Normal
E. (3%)	↑	Normal	↑	↑	↑

Omitted
Correct answer
A

63%
Answered correctly

02 secs
Time Spent

02/26/2020
Last Updated

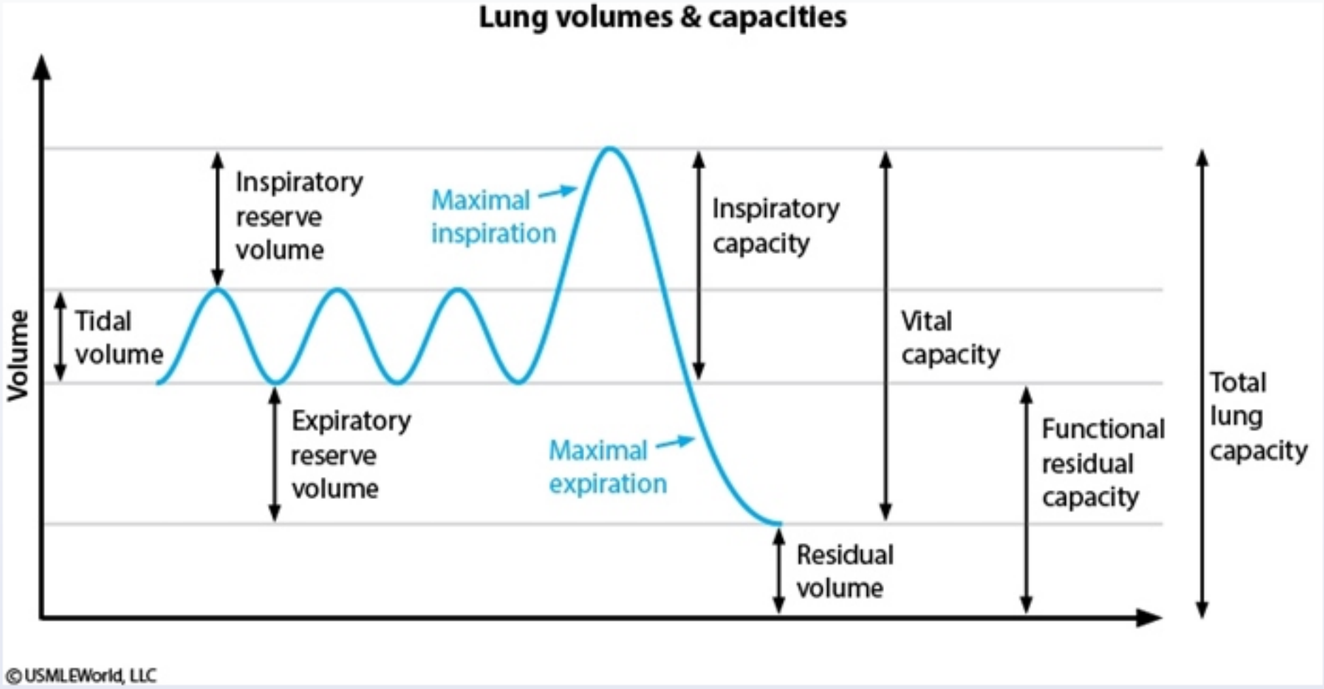

This young patient presenting with respiratory symptoms and **central obesity** without a history of pulmonary disease likely has obesity-related **restrictive lung disease**. Obesity alters respiratory compliance, which is the ability of the lung and chest wall to stretch in response to increased lung pressures. Respiratory compliance is diminished both by a reduction in chest wall compliance from increased weight and by a reduction in lung compliance due to microatelectasis. To compensate for the reduced compliance, obese patients typically have increased respiratory rates with reduced tidal volumes (rapid-shallow breathing).

The most common indicator of obesity-related disease is a **reduction** in **expiratory reserve volume** (ERV), which is the maximum volume of air that can be expired after a normal tidal expiration. Obesity has minimal effect on residual volume (RV), but **functional residual capacity**, which is the sum of RV and ERV, is reduced due to the marked reduction in ERV. Obesity can also cause reductions of forced vital capacity (FVC), forced expiratory volume in 1 second (FEV_1), and total lung capacity (TLC), depending on the severity of obesity and body fat distribution (abdominal

© USMLEWorld, LLC

This young patient presenting with respiratory symptoms and **central obesity** without a history of pulmonary disease likely has obesity-related **restrictive lung disease**. Obesity alters respiratory compliance, which is the ability of the lung and chest wall to stretch in response to increased lung pressures. Respiratory compliance is diminished both by a reduction in chest wall compliance from increased weight and by a reduction in lung compliance due to microatelectasis. To compensate for the reduced compliance, obese patients typically have increased respiratory rates with reduced tidal volumes (rapid-shallow breathing).

The most common indicator of obesity-related disease is a **reduction** in **expiratory reserve volume** (ERV), which is the maximum volume of air that can be expired after a normal tidal expiration. Obesity has minimal effect on residual volume (RV), but **functional residual capacity**, which is the sum of RV and ERV, is reduced due to the marked reduction in ERV. Obesity can also cause reductions of forced vital capacity (FVC), forced expiratory volume in 1 second (FEV_1), and total lung capacity (TLC), depending on the severity of obesity and body fat distribution (abdominal obesity causes greater impairment). However, these reductions are generally modest, especially relative to decrements in ERV.

(Choices B and C) These are patterns that may be seen in a patient with chronic obstructive pulmonary disease, with FEV_1 reduced and FVC normal or only mildly diminished in comparison to FEV_1. TLC and RV are increased with emphysema.

(Choices D and E) FEV_1, FVC, and TLC may be increased in trained athletes.

Educational objective:
Obesity, particularly morbid, central obesity, can cause a pattern of extrinsic restrictive pulmonary function tests. The most common indicator of obesity-related disease is a reduction in expiratory reserve volume and functional residual capacity, but forced expiratory volume in 1 second, forced vital capacity, and total lung capacity are also typically decreased.

References

- Altered resting and exercise respiratory physiology in obesity.

Pathophysiology	Pulmonary & Critical Care	Obesity
Subject	System	Topic

Copyright © UWorld. All rights reserved.

This young patient presenting with respiratory symptoms and **central obesity** without a history of pulmonary disease likely has obesity-related **restrictive lung disease**. Obesity alters respiratory compliance, which is the ability of the lung and chest wall to stretch in response to increased lung pressures. Respiratory compliance is diminished both by a reduction in chest wall compliance from increased weight and by a reduction in lung compliance due to microatelectasis. To compensate for the reduced compliance, obese patients typically have increased respiratory rates with reduced tidal volumes (rapid-shallow breathing).

The most common indicator of obesity-related disease is a **reduction** in **expiratory reserve volume** (ERV), which is the maximum volume of air that can be expired after a normal tidal expiration. Obesity has minimal effect on residual volume (RV), but **functional residual capacity**, which is the sum of RV and ERV, is reduced due to the marked reduction in ERV. Obesity can also cause reductions of forced vital capacity (FVC), forced expiratory volume in 1 second (FEV_1), and total lung capacity (TLC), depending on the severity of obesity and body fat distribution (abdominal obesity causes greater impairment). However, these reductions are generally modest, especially relative to decrements in ERV.

(Choices B and C) These are patterns that may be seen in a patient with chronic obstructive pulmonary disease, with FEV_1 reduced and FVC normal or only mildly diminished in comparison to FEV_1. TLC and RV are increased with emphysema.

(Choices D and E) FEV_1, FVC, and TLC may be increased in trained athletes.

Educational objective:
Obesity, particularly morbid, central obesity, can cause a pattern of extrinsic restrictive pulmonary function tests. The most common indicator of obesity-related disease is a reduction in expiratory reserve volume and functional residual capacity, but forced expiratory volume in 1 second, forced vital capacity, and total lung capacity are also typically decreased.

References

- Altered resting and exercise respiratory physiology in obesity.

Pathophysiology	Pulmonary & Critical Care	Obesity
Subject	System	Topic

Copyright © UWorld. All rights reserved.

A 53-year-old man comes to the emergency department due to progressive shortness of breath and nonproductive cough. Medical history is significant for long-standing hypertension and type 2 diabetes mellitus, for which he takes lisinopril and metformin. The patient has no drug allergies. Blood pressure is 160/100 mm Hg, pulse is 110/min, and respirations are 20/min. On physical examination, heart sounds are regular. Lung examination reveals decreased tactile fremitus over the lower right lung along with dullness to percussion. Which of the following is the most likely diagnosis?

- A. Bronchospasm
- B. Emphysema
- C. Lobar consolidation
- D. Pericardial effusion
- E. Pleural effusion
- F. Pneumothorax
- G. Pulmonary edema

Submit

A 53-year-old man comes to the emergency department due to progressive shortness of breath and nonproductive cough. Medical history is significant for long-standing hypertension and type 2 diabetes mellitus, for which he takes lisinopril and metformin. The patient has no drug allergies. Blood pressure is 160/100 mm Hg, pulse is 110/min, and respirations are 20/min. On physical examination, heart sounds are regular. Lung examination reveals decreased tactile fremitus over the lower right lung along with dullness to percussion. Which of the following is the most likely diagnosis?

- A. Bronchospasm (0%)
- B. Emphysema (1%)
- C. Lobar consolidation (30%)
- D. Pericardial effusion (0%)
- ✓ E. Pleural effusion (47%)
- F. Pneumothorax (2%)
- G. Pulmonary edema (17%)

Omitted
Correct answer
E

47%
Answered correctly

04 secs
Time Spent

06/17/2020
Last Updated

Explanation

Pulmonary auscultation examination findings

Pulmonary auscultation examination findings			
Condition	**Breath sounds**	**Tactile fremitus**	**Percussion**
Normal lung	Normal	Normal	Resonance
Consolidation	Increased	Increased	Dullness
Pleural effusion	Decreased or absent	Decreased	Dullness
Pneumothorax	Decreased or absent	Decreased	Hyperresonance
Atelectasis	Decreased or absent	Decreased	Dullness

This patient most likely has a right-sided **pleural effusion**. Excess fluid within the pleural space acts to insulate vibrations and breath sounds that originate in the airways of the lungs. Consequently, **tactile fremitus**, the transmission of vibration from vocalized sound (eg, saying "ninety-nine"), is **decreased** over a pleural effusion. **Breath sounds** are also **decreased** or absent. The high density of pleural fluid compared to normal lung (alveolus-air composite) causes **dullness to percussion** over the effusion.

(Choice A) Bronchospasm is likely to have minimal effect on tactile fremitus and dullness to percussion.

(Choice B) The hyperinflated alveoli in emphysema should demonstrate hyperresonance to percussion and decreased tactile fremitus.

(Choices C and G) Because sound vibrations travel faster and more efficiently through liquids than through gases, alveolar filling processes such as lobar consolidation (alveoli filled with pus) and pulmonary edema (alveoli filled with transudate) create increased breath sound intensity and increased tactile fremitus.

(Choice D) A large pericardial effusion might cause dullness to percussion with decreased tactile fremitus over the precordium, but not over the lower lung.

(Choice F) Like pleural effusion, pneumothorax (air in the pleural space) acts to insulate sound originating in the airways; therefore, tactile

Atelectasis	Decreased or absent	Decreased	Dullness

This patient most likely has a right-sided **pleural effusion**. Excess fluid within the pleural space acts to insulate vibrations and breath sounds that originate in the airways of the lungs. Consequently, **tactile fremitus**, the transmission of vibration from vocalized sound (eg, saying "ninety-nine"), is **decreased** over a pleural effusion. **Breath sounds** are also **decreased** or absent. The high density of pleural fluid compared to normal lung (alveolus-air composite) causes **dullness to percussion** over the effusion.

(Choice A) Bronchospasm is likely to have minimal effect on tactile fremitus and dullness to percussion.

(Choice B) The hyperinflated alveoli in emphysema should demonstrate hyperresonance to percussion and decreased tactile fremitus.

(Choices C and G) Because sound vibrations travel faster and more efficiently through liquids than through gases, alveolar filling processes such as lobar consolidation (alveoli filled with pus) and pulmonary edema (alveoli filled with transudate) create increased breath sound intensity and increased tactile fremitus.

(Choice D) A large pericardial effusion might cause dullness to percussion with decreased tactile fremitus over the precordium, but not over the lower lung.

(Choice F) Like pleural effusion, pneumothorax (air in the pleural space) acts to insulate sound originating in the airways; therefore, tactile fremitus and breath sounds are decreased. However, the low density of air compared to normal lung creates hyperresonance to percussion.

Educational objective:
Fluid in the pleural space acts to insulate sound vibrations that originate in the airways; therefore, pleural effusion causes decreased tactile fremitus and decreased intensity of breath sounds. The high density of pleural fluid compared to normal lung tissue also causes dullness to percussion.

Pathophysiology	Pulmonary & Critical Care	Pleural effusion
Subject	System	Topic

Copyright © UWorld. All rights reserved.

A 63-year-old woman comes to the office due to slowly progressive dyspnea on exertion and cough productive of white-yellow sputum over the past several years. She has a history of rheumatoid arthritis and seasonal allergies. The patient has smoked a pack of cigarettes daily for 40 years. Blood pressure is 135/80 mm Hg and pulse is 76/min. Lung examination demonstrates mild, bilateral expiratory wheezes, and chest x-ray reveals hyperinflated lungs. Pulmonary function test results are as follows:

Forced expiratory volume in 1 second (FEV1)	58% of predicted	(normal >80%)
FEV1/Forced vital capacity ratio	62%	(normal >75%)
Diffusion capacity	67% of predicted	(normal >80%)

Which of the following cells most likely played a major role in the pathogenesis of this patient's lung condition?

A. B lymphocytes
B. $CD4^+$ T lymphocytes
C. Eosinophils
D. Mast cells
E. Neutrophils

Submit

A 63-year-old woman comes to the office due to slowly progressive dyspnea on exertion and cough productive of white-yellow sputum over the past several years. She has a history of rheumatoid arthritis and seasonal allergies. The patient has smoked a pack of cigarettes daily for 40 years. Blood pressure is 135/80 mm Hg and pulse is 76/min. Lung examination demonstrates mild, bilateral expiratory wheezes, and chest x-ray reveals hyperinflated lungs. Pulmonary function test results are as follows:

Forced expiratory volume in 1 second (FEV1)	58% of predicted	(normal >80%)
FEV1/Forced vital capacity ratio	62%	(normal >75%)
Diffusion capacity	67% of predicted	(normal >80%)

Which of the following cells most likely played a major role in the pathogenesis of this patient's lung condition?

A. B lymphocytes (1%)
B. $CD4^+$ T lymphocytes (15%)
C. Eosinophils (9%)
D. Mast cells (10%)
✓ E. Neutrophils (63%)

Omitted
Correct answer
E

63%
Answered correctly

01 sec
Time Spent

02/03/2020
Last Updated

Explanation

Explanation

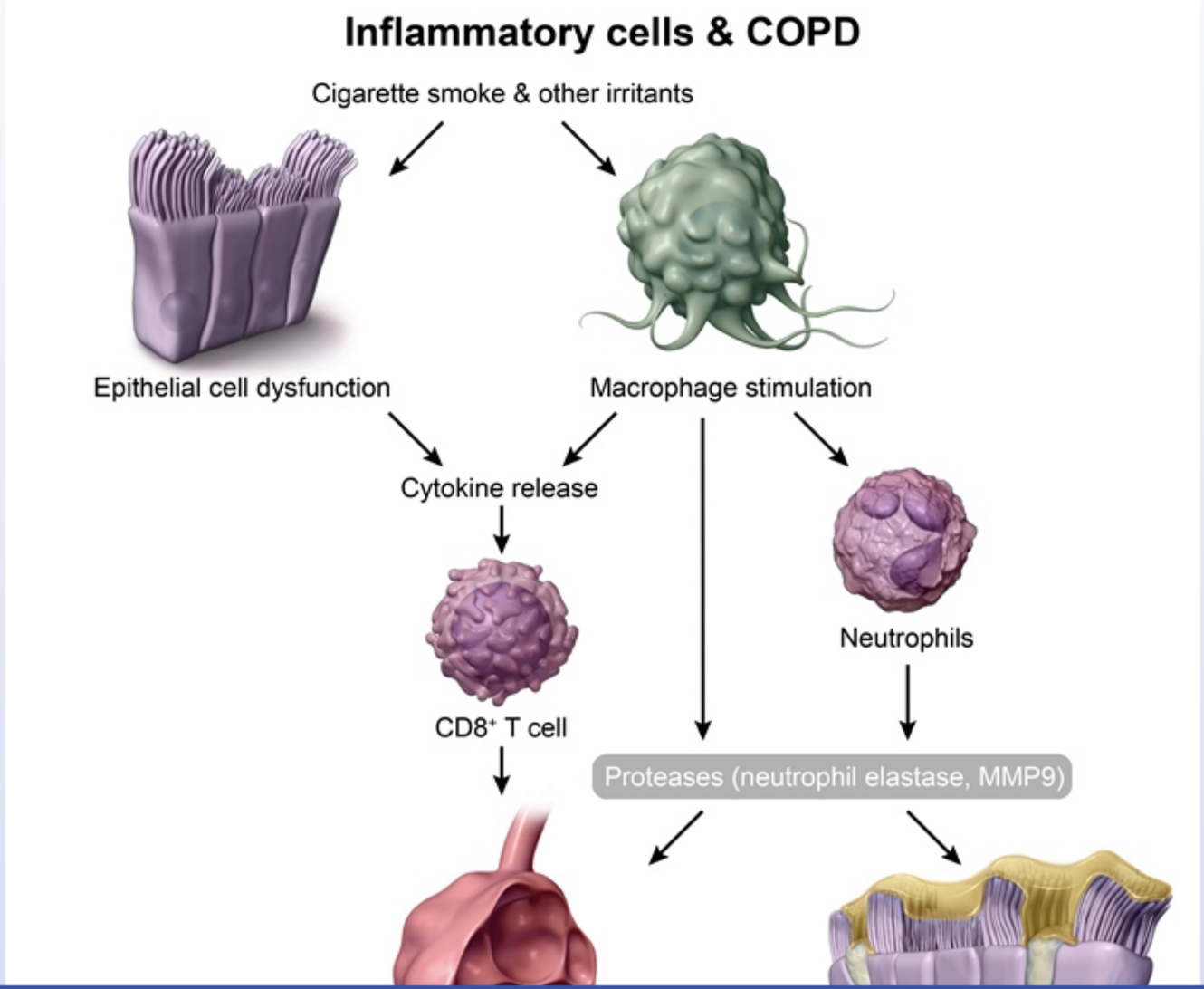

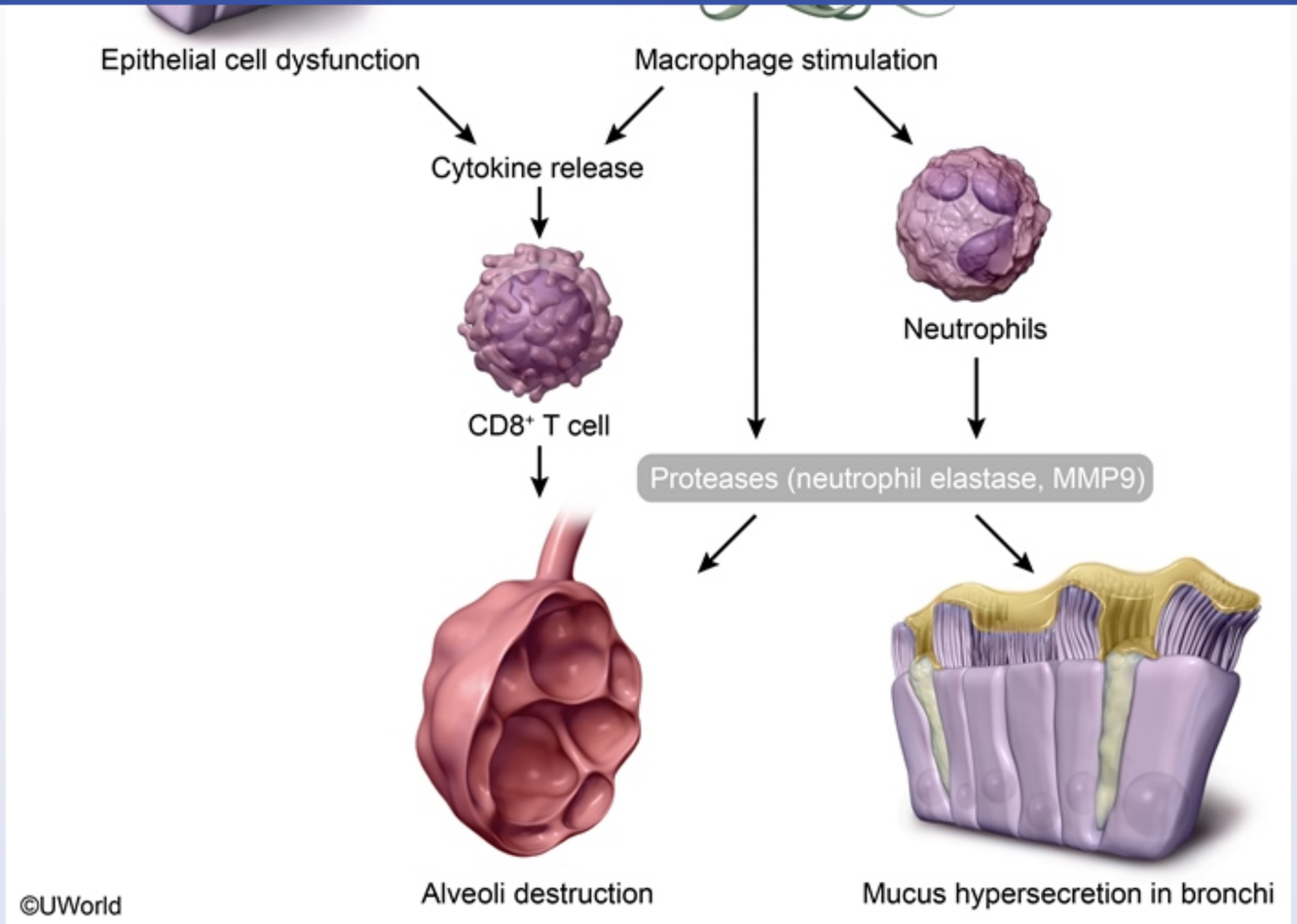

This patient with dyspnea, productive cough, and an obstructive pattern on pulmonary function testing—in the setting of a prolonged smoking history—likely has **chronic obstructive pulmonary disease** (COPD). COPD is characterized by chronic airway inflammation, which results in both parenchymal destruction (emphysema) and remodeling of the airways (chronic bronchitis). The primary cell lines that are increased in COPD are **neutrophils**, **macrophages**, and **CD8⁺ T lymphocytes**. These cells release enzymes and proteases, such as neutrophil **elastase**, that cause alveolar damage, reduced ciliary motion, and increased mucus secretion by goblet cells. In addition, the inflammatory cells show impaired

©UWorld

Alveoli destruction

Mucus hypersecretion in bronchi

This patient with dyspnea, productive cough, and an obstructive pattern on pulmonary function testing—in the setting of a prolonged smoking history—likely has **chronic obstructive pulmonary disease** (COPD). COPD is characterized by chronic airway inflammation, which results in both parenchymal destruction (emphysema) and remodeling of the airways (chronic bronchitis). The primary cell lines that are increased in COPD are **neutrophils**, **macrophages**, and **$CD8^+$ T lymphocytes**. These cells release enzymes and proteases, such as neutrophil **elastase**, that cause alveolar damage, reduced ciliary motion, and increased mucus secretion by goblet cells. In addition, the inflammatory cells show impaired ability to phagocytize bacterial pathogens, possibly contributing to increased risk of respiratory infections such as community-acquired pneumonia.

(Choice A) The involvement of B lymphocytes in COPD pathogenesis is controversial; however, they do not appear to have a major role, and their increased numbers may actually be protective against bacterial colonization.

(Choice B) Although $CD4^+$ T lymphocytes are slightly increased in COPD, their numbers and pathologic role are much less significant than those of $CD8^+$ T lymphocytes. However, $CD4^+$ T lymphocytes have been implicated in asthma pathogenesis.

(Choice C) Eosinophils play an important role in asthma but do not appear to have a major impact in COPD. Their increased presence in patients with COPD may indicate coexisting asthma.

(Choice D) Patients with mast cell disorders can have flushing, abdominal discomfort, and respiratory symptoms such as dyspnea and wheezing due to bronchoconstriction. However, mast cells do not play an important role in the pathogenesis of COPD.

Educational objective:
Neutrophils, macrophages, and $CD8^+$ T lymphocytes are the primary mediators of disease in chronic obstructive pulmonary disease. They secrete enzymes and proteases that cause and perpetuate both the alveolar destruction of emphysema and the mucus hypersecretion found in chronic bronchitis.

References

- Cellular and molecular mechanisms in chronic obstructive pulmonary disease: an overview.
- Inflammatory cells and chronic obstructive pulmonary disease.
- Cellular and molecular mechanisms of chronic obstructive pulmonary disease.

A 47-year-old man comes to the office due to worsening shortness of breath for several months. The patient has no fever, weight loss, or cough. He has no other medical conditions and takes no medications. The patient does not use tobacco, alcohol, or illicit drugs. Vital signs are normal. Pulmonary examination demonstrates wheezing and poor air movement. Laboratory results are as follows:

Platelets	160,000/mm^3
Leukocytes	6,500/mm^3
Creatinine	0.8 mg/dL
Total bilirubin	1.3 mg/dL
Aspartate aminotransferase (SGOT)	112 U/L
Alanine aminotransferase (SGPT)	124 U/L

A liver biopsy is subsequently performed. Light microscopy of the tissue specimen after treatment with diastase and periodic acid–Schiff staining is shown in the exhibits. Given these findings, which of the following is the most likely cause of this patient's shortness of breath?

- A. Bronchial hyperreactivity
- B. Interalveolar septa destruction
- C. Interstitial infiltration
- D. Intraalveolar substance accumulation
- E. Pulmonary congestion
- F. Pulmonary vascular obstruction

Settings

1 2 3 4 5 6 7 8 9 10 11 12 13 14 15 16 17 18 19 20 21 22 23 24 25 26 27 28 29 30

Item 40 of 40
Question Id: 399

Mark | Previous | Next | Full Screen | Tutorial | Lab Values | Notes | Calculator | Reverse Color | Text Zoom | Settings

Exhibit Display

Exhibit 1 Exhibit 2

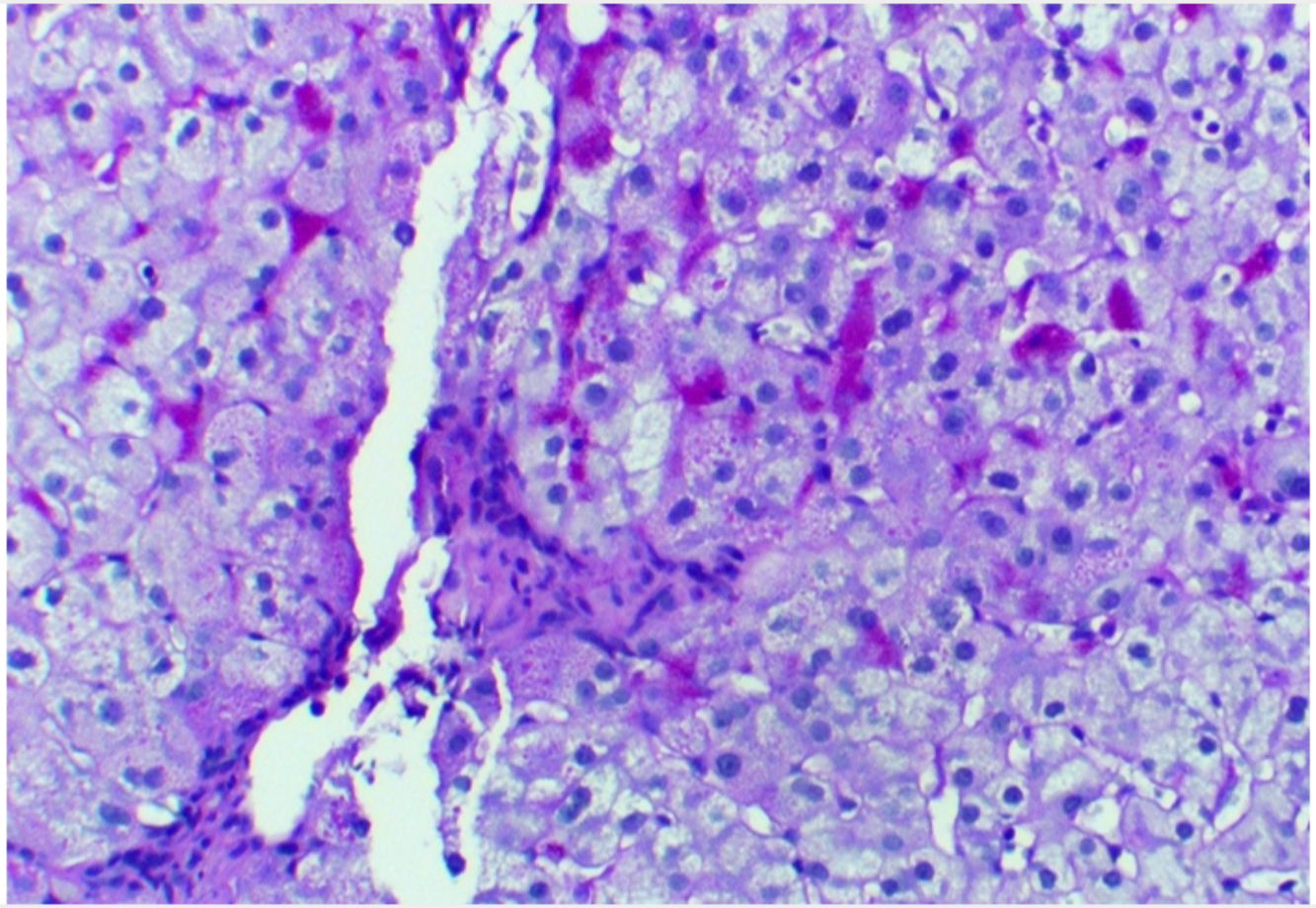

Zoom In | Zoom Out | Reset | Add To New Card | Existing Card

Block Time Remaining: 00:02:05
TUTOR

4 | Feedback | Suspend | End Block

Settings

1 2 3 4 5 6 7 8 9 10 11 12 13 14 15 16 17 18 19 20 21 22 23 24 25 26 27 28 29 30

Item 40 of 40
Question Id: 399

Mark | Previous | Next | Full Screen | Tutorial | Lab Values | Notes | Calculator | Reverse Color | Text Zoom | Settings

Exhibit Display

Exhibit 1 Exhibit 2

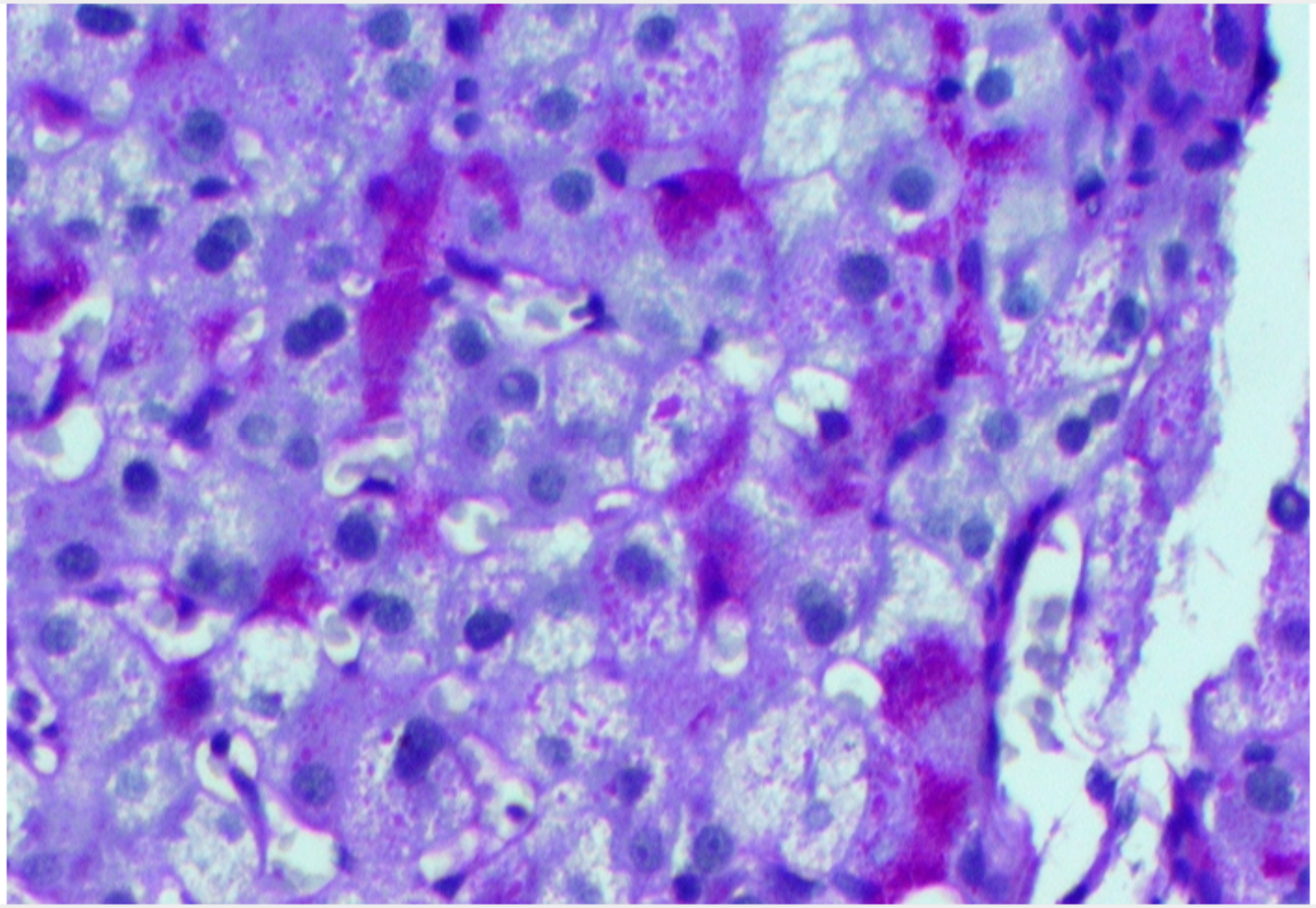

Zoom In | Zoom Out | Reset | Add To New Card | Existing Card

Block Time Remaining: 00:02:10
TUTOR

4 | Feedback | Suspend | End Block

He has no other medical conditions and takes no medications. The patient does not use tobacco, alcohol, or illicit drugs. Vital signs are normal. Pulmonary examination demonstrates wheezing and poor air movement. Laboratory results are as follows:

Platelets	160,000/mm^3
Leukocytes	6,500/mm^3
Creatinine	0.8 mg/dL
Total bilirubin	1.3 mg/dL
Aspartate aminotransferase (SGOT)	112 U/L
Alanine aminotransferase (SGPT)	124 U/L

A liver biopsy is subsequently performed. Light microscopy of the tissue specimen after treatment with diastase and periodic acid–Schiff staining is shown in the exhibits. Given these findings, which of the following is the most likely cause of this patient's shortness of breath?

- A. Bronchial hyperreactivity
- B. Interalveolar septa destruction
- C. Interstitial infiltration
- D. Intraalveolar substance accumulation
- E. Pulmonary congestion
- F. Pulmonary vascular obstruction

Submit

He has no other medical conditions and takes no medications. The patient does not use tobacco, alcohol, or illicit drugs. Vital signs are normal. Pulmonary examination demonstrates wheezing and poor air movement. Laboratory results are as follows:

Platelets	160,000/mm^3
Leukocytes	6,500/mm^3
Creatinine	0.8 mg/dL
Total bilirubin	1.3 mg/dL
Aspartate aminotransferase (SGOT)	112 U/L
Alanine aminotransferase (SGPT)	124 U/L

A liver biopsy is subsequently performed. Light microscopy of the tissue specimen after treatment with diastase and periodic acid–Schiff staining is shown in the exhibits. Given these findings, which of the following is the most likely cause of this patient's shortness of breath?

A. Bronchial hyperreactivity (4%)
✓ B. Interalveolar septa destruction (56%)
C. Interstitial infiltration (12%)
D. Intraalveolar substance accumulation (11%)
E. Pulmonary congestion (10%)
F. Pulmonary vascular obstruction (3%)

Omitted
Correct answer

56%
Answered correctly

16 secs
Time Spent

03/29/2020
Last Updated

Alpha-1 antitrypsin deficiency	
Etiology	• Autosomal codominant inheritance • ↓ Alpha-1 antitrypsin leads to unchecked elastase activity
Clinical presentation	• Early-onset (age ≤45) panacinar emphysema • Basilar lung areas predominantly affected • Smoking accelerates disease • Associated liver dysfunction or cirrhosis
Diagnosis	• Obstructive pattern on PFT: ↓ FEV1/FVC ratio, ↓ DLCO • ↓ Serum alpha-1 antitrypsin level & genetic testing

DLCO = diffusing capacity of the lung for carbon monoxide; PFT = pulmonary function testing.

This patient has **alpha-1 antitrypsin** (AAT) **deficiency**, an autosomal codominant disorder that can affect the lungs and liver. Produced primarily in the liver, AAT is a serum protein that inhibits several different proteolytic enzymes (in particular, neutrophil elastase), thereby reducing tissue damage caused by inflammation. Most individuals with AAT deficiency are homozygous for the Z allele, which causes decreased secretion of AAT secondary to abnormal protein folding. The diagnosis of AAT deficiency is established by measurement of the serum AAT level, followed by confirmatory genetic testing.

Most individuals with AAT deficiency eventually develop severe **panacinar emphysema** due to unchecked destruction of the **interalveolar septa** (which contain large amounts of elastin). Smoking plays a synergistic role in the disease process by inducing lung inflammation and permanently inactivating AAT through oxidation of a crucial methionine residue. Therefore, smokers with AAT deficiency tend to develop dyspnea at a median age of 36 versus a median age of 51 in nonsmokers.

Some patients with AAT deficiency develop liver disease due to **intrahepatocyte accumulation** of polymerized AAT molecules; the liver disease can progress to **cirrhosis** (the second most common cause of death behind emphysema in this population) and hepatocellular carcinoma. Histologically, intracellular granules of unsecreted AAT are seen within the periportal hepatocytes. These globules resist digestion by diastase (an enzyme that breaks down glycogen) and appear reddish-pink with the periodic acid–Schiff stain (black arrows).

This patient has **alpha-1 antitrypsin** (AAT) **deficiency**, an autosomal codominant disorder that can affect the lungs and liver. Produced primarily in the liver, AAT is a serum protein that inhibits several different proteolytic enzymes (in particular, neutrophil elastase), thereby reducing tissue damage caused by inflammation. Most individuals with AAT deficiency are homozygous for the Z allele, which causes decreased secretion of AAT secondary to abnormal protein folding. The diagnosis of AAT deficiency is established by measurement of the serum AAT level, followed by confirmatory genetic testing.

Most individuals with AAT deficiency eventually develop severe **panacinar emphysema** due to unchecked destruction of the **interalveolar septa** (which contain large amounts of elastin). Smoking plays a synergistic role in the disease process by inducing lung inflammation and permanently inactivating AAT through oxidation of a crucial methionine residue. Therefore, smokers with AAT deficiency tend to develop dyspnea at a median age of 36 versus a median age of 51 in nonsmokers.

Some patients with AAT deficiency develop liver disease due to **intrahepatocyte accumulation** of polymerized AAT molecules; the liver disease can progress to **cirrhosis** (the second most common cause of death behind emphysema in this population) and hepatocellular carcinoma. Histologically, intracellular granules of unsecreted AAT are seen within the periportal hepatocytes. These globules resist digestion by diastase (an enzyme that breaks down glycogen) and appear reddish-pink with the periodic acid–Schiff stain (black arrows).

(Choice A) Bronchial hyperreactivity is a hallmark of chronic asthma.

(Choice C) Interstitial infiltration is a finding in interstitial pneumonitis.

(Choice D) Intraalveolar substance accumulation is a finding in alveolar proteinosis.

(Choice E) Pulmonary congestion is a finding in congestive heart failure.

(Choice F) Pulmonary vascular obstruction occurs in pulmonary embolism or vasculopathy.

Educational objective:
Alpha-1 antitrypsin (AAT) is a serum protein that, through the inhibition of neutrophil elastase, reduces tissue damage caused by inflammation. Histologically, AAT deficiency can demonstrate reddish-pink globules on periodic acid–Schiff stain; these globules represent unsecreted, polymerized AAT in the periportal hepatocytes.

Settings

1 2 3 4 5 6 7 8 9 10 11 12 13 14 15 16 17 18 19 20 21 22 23 24 25 26 27 28 29 30

Item 40 of 40
Question Id: 399

Mark | Previous | Next | Full Screen | Tutorial | Lab Values | Notes | Calculator | Reverse Color | Text Zoom | Settings

Exhibit Display

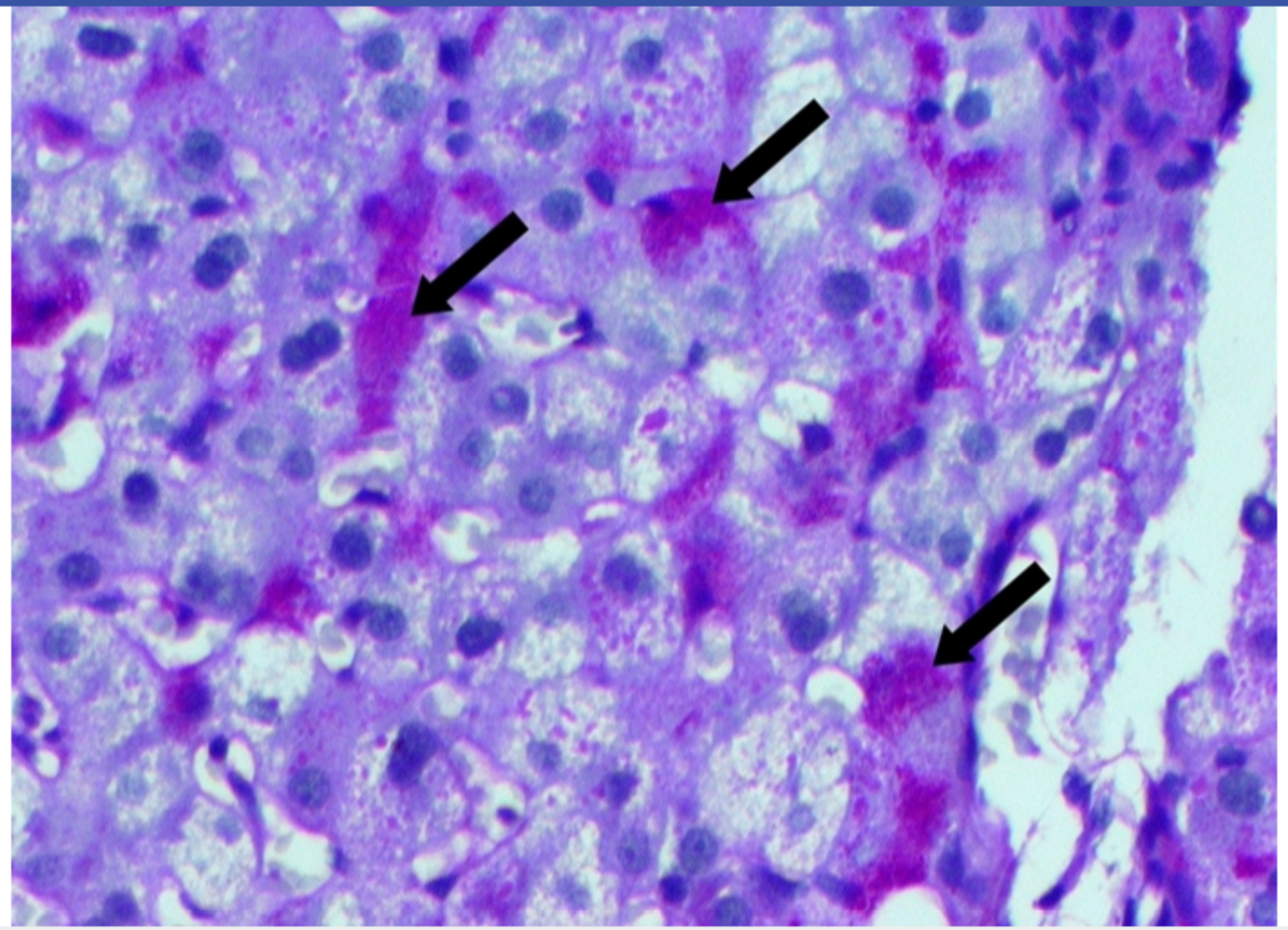

Zoom In | Zoom Out | Reset | Add To New Card | Existing Card

Block Time Remaining: 00:02:15
TUTOR

4 | Feedback | Suspend | End Block

inactivating AAT through oxidation of a crucial methionine residue. Therefore, smokers with AAT deficiency tend to develop dyspnea at a median age of 36 versus a median age of 51 in nonsmokers.

Some patients with AAT deficiency develop liver disease due to **intrahepatocyte accumulation** of polymerized AAT molecules; the liver disease can progress to **cirrhosis** (the second most common cause of death behind emphysema in this population) and hepatocellular carcinoma. Histologically, intracellular granules of unsecreted AAT are seen within the periportal hepatocytes. These globules resist digestion by diastase (an enzyme that breaks down glycogen) and appear reddish-pink with the periodic acid–Schiff stain (black arrows).

(Choice A) Bronchial hyperreactivity is a hallmark of chronic asthma.

(Choice C) Interstitial infiltration is a finding in interstitial pneumonitis.

(Choice D) Intraalveolar substance accumulation is a finding in alveolar proteinosis.

(Choice E) Pulmonary congestion is a finding in congestive heart failure.

(Choice F) Pulmonary vascular obstruction occurs in pulmonary embolism or vasculopathy.

Educational objective:
Alpha-1 antitrypsin (AAT) is a serum protein that, through the inhibition of neutrophil elastase, reduces tissue damage caused by inflammation. Histologically, AAT deficiency can demonstrate reddish-pink globules on periodic acid–Schiff stain; these globules represent unsecreted, polymerized AAT in the periportal hepatocytes.

References

- Diagnosis and management of patients with a1-antitrypsin (A1AT) deficiency.
- Alpha-1 antitrypsin deficiency.

Pathophysiology	Pulmonary & Critical Care	Alpha1 antitrypsin deficiency
Subject	System	Topic

Copyright © UWorld. All rights reserved.

Settings

1
2
3
4
5
6

Item 1 of 6
Question Id: 15156

Mark | Previous | Next | Full Screen | Tutorial | Lab Values | Notes | Calculator | Reverse Color | Text Zoom | Settings

An 8-year-old girl is brought to the emergency department due to worsening shortness of breath and chest tightness for the past 2 hours. On physical examination, the patient speaks in short sentences. Lung auscultation reveals diffuse wheezing. During the evaluation, the patient is instructed to take a deep breath and blow as hard as possible into the mouthpiece of a hand-held device. The measured airflow rate is significantly lower than expected. Treatment with an inhaled medication is begun. A repeat evaluation several minutes later shows an increase in the airflow rate. The administered medication most likely affected which of the following to produce the observed finding in this patient?

- A. Airway inflammatory response
- B. Alveolar surfactant production
- C. Bronchiolar smooth muscle tone
- D. Lower-airway bacterial load
- E. Pulmonary vascular resistance

Submit

Block Time Remaining: 00:00:01
TUTOR

0 | Feedback | Suspend | End Block

An 8-year-old girl is brought to the emergency department due to worsening shortness of breath and chest tightness for the past 2 hours. On physical examination, the patient speaks in short sentences. Lung auscultation reveals diffuse wheezing. During the evaluation, the patient is instructed to take a deep breath and blow as hard as possible into the mouthpiece of a hand-held device. The measured airflow rate is significantly lower than expected. Treatment with an inhaled medication is begun. A repeat evaluation several minutes later shows an increase in the airflow rate. The administered medication most likely affected which of the following to produce the observed finding in this patient?

- A. Airway inflammatory response (4%)
- B. Alveolar surfactant production (0%)
- ✓ C. Bronchiolar smooth muscle tone (94%)
- D. Lower-airway bacterial load (0%)
- E. Pulmonary vascular resistance (0%)

Omitted
Correct answer
C

94%
Answered correctly

03 secs
Time Spent

05/15/2020
Last Updated

Explanation

This patient's acute-onset shortness of breath and chest tightness are consistent with the **airway spasm** and **bronchoconstriction** that occurs in **asthma**. She received a **bronchodilator** to reduce airway resistance and increase airway flow. In asthma, bronchodilation is typically accomplished with a **beta-2 receptor agonist** (eg, albuterol); these drugs work by stimulating beta-2 adrenergic receptors on **bronchial smooth muscle cells**, leading to an increase in cyclic AMP and consequent **smooth muscle relaxation** (decrease in smooth muscle tone).

Omitted
Correct answer
C

94%
Answered correctly

03 secs
Time Spent

05/15/2020
Last Updated

Explanation

This patient's acute-onset shortness of breath and chest tightness are consistent with the **airway spasm** and **bronchoconstriction** that occurs in **asthma**. She received a **bronchodilator** to reduce airway resistance and increase airway flow. In asthma, bronchodilation is typically accomplished with a **beta-2 receptor agonist** (eg, albuterol); these drugs work by stimulating beta-2 adrenergic receptors on **bronchial smooth muscle cells**, leading to an increase in cyclic AMP and consequent **smooth muscle relaxation** (decrease in smooth muscle tone).

(Choices A and B) Corticosteroids, both inhaled (eg, budesonide, fluticasone) and systemic (eg, prednisone), modify gene transcription to reduce the airway inflammatory response in patients with asthma. Corticosteroids are also used to stimulate alveolar surfactant production and reduce the risk of neonatal respiratory distress syndrome in premature infants.

(Choice D) Inhaled antibiotics (eg, tobramycin) are used to reduce lower-airway bacterial load in patients with cystic fibrosis.

(Choice E) Several medications, including endothelin receptor antagonists (eg, bosentan), phosphodiesterase inhibitors (eg, sildenafil), and prostacyclin analogs, are used to lower pulmonary vascular resistance in patients with pulmonary arterial hypertension.

Educational objective:
Bronchodilators induce bronchial smooth muscle relaxation to relieve airway spasm and bronchoconstriction in patients with asthma. Bronchodilation is most commonly accomplished with beta-2 receptor agonists (eg, albuterol), which function by increasing cyclic AMP levels in bronchial smooth muscle.

Pathophysiology	Pulmonary & Critical Care	Asthma
Subject	System	Topic

Copyright © UWorld. All rights reserved.

Omitted
Correct answer
94%
03 secs
05/15/2020

Exhibit Display

G protein activation of adenylate cyclase

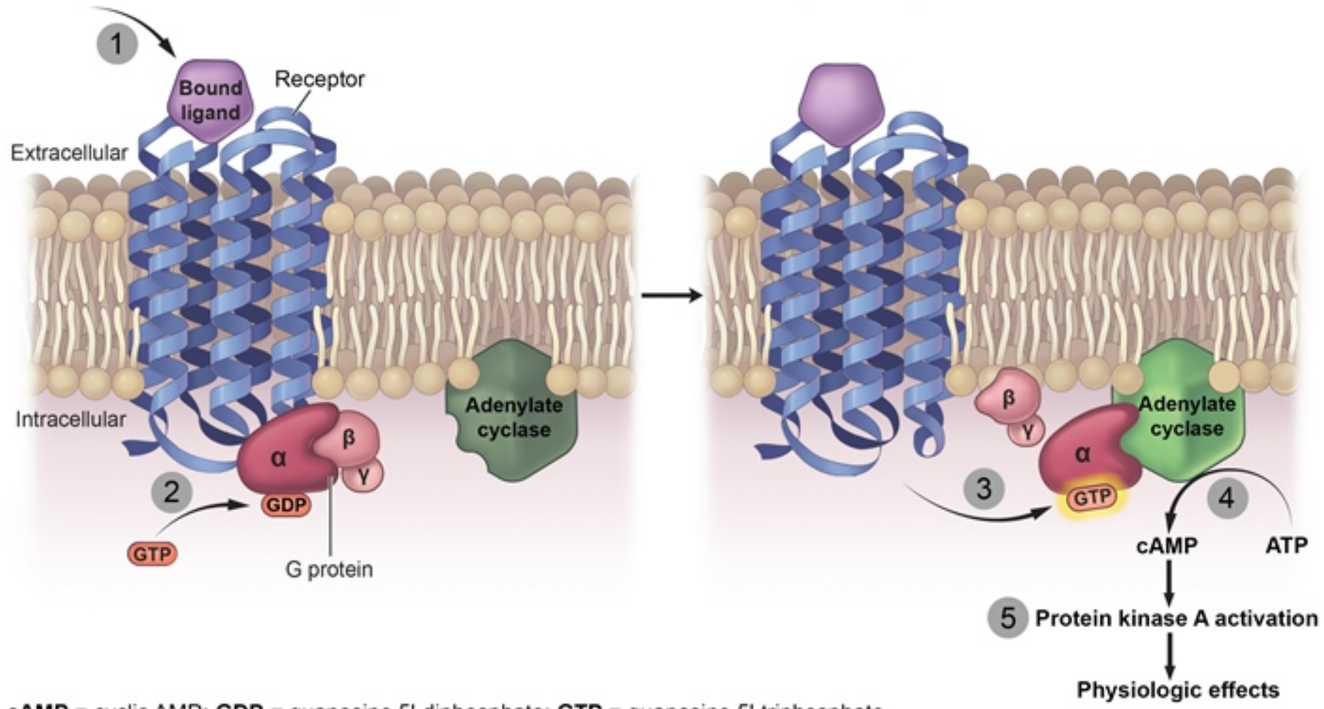

cAMP = cyclic AMP; **GDP** = guanosine 5'-diphosphate; **GTP** = guanosine 5'-triphosphate.

©UWorld

Zoom In | Zoom Out | Reset | Add To New Card | Existing Card

Omitted
Correct answer
94%
03 secs
05/15/2020

Exhibit Display

Targets of therapy for pulmonary arterial hypertension

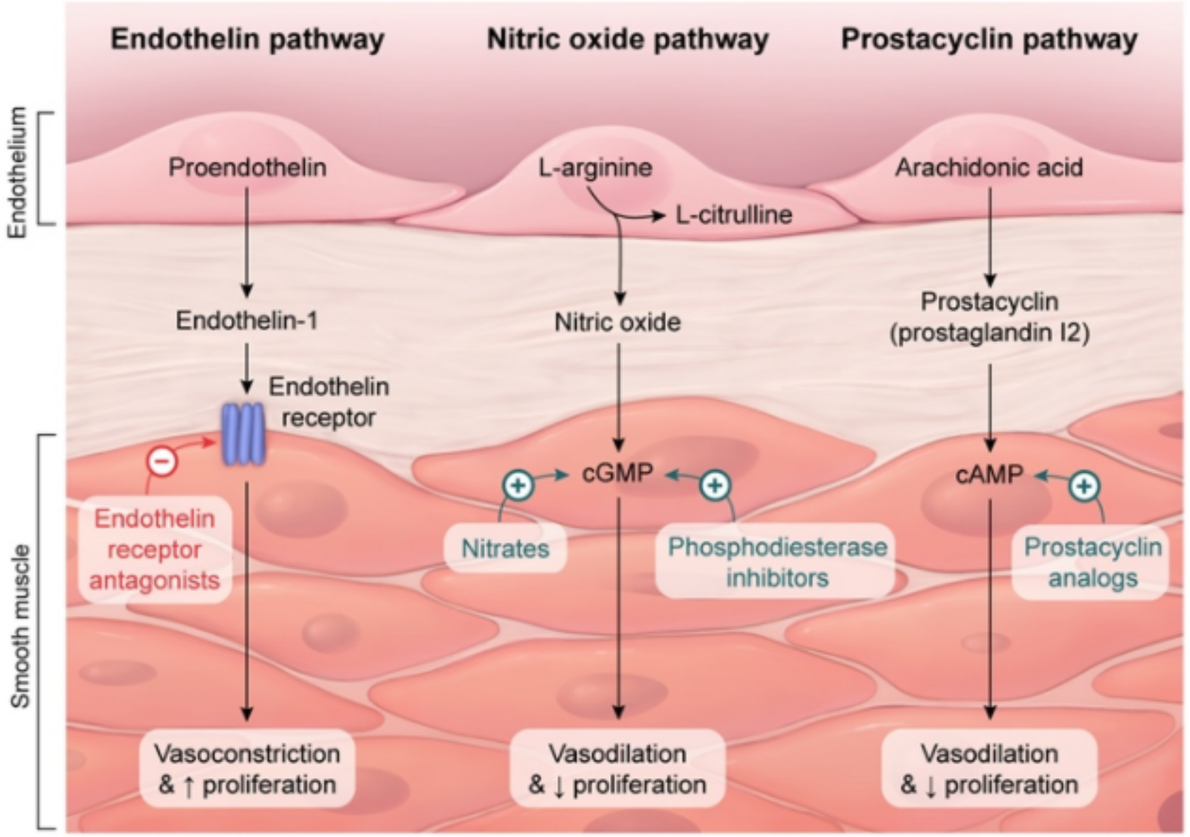

©UWorld

Zoom In | Zoom Out | Reset | Add To New Card | Existing Card

A 71-year-old man with a long history of smoking is found to have a new, 4-cm, irregular, spiculated, rounded mass in the right upper lobe. CT-guided biopsy is performed. Follow-up chest x-ray after the procedure is shown in the exhibit. Physical examination of the right lung would most likely show which of the following findings?

	Percussion	Tactile fremitus	Breath sounds
A.	Dullness	Decreased	Decreased
B.	Dullness	Increased	Bronchial
C.	Dullness	Increased	Decreased
D.	Hyperresonance	Decreased	Bronchial
E.	Hyperresonance	Decreased	Decreased
F.	Hyperresonance	Decreased	Increased
G.	Resonance	Normal	Vesicular

Submit

A 71-year-old man with a long history of smoking is found to have a new, 4-cm, irregular, spiculated, rounded mass in the right upper lobe. CT-guided biopsy is performed. Follow-up chest x-ray after the procedure is shown in the exhibit. Physical examination of the right lung would most likely show which of the following findings?

	Percussion	Tactile fremitus	Breath sounds
A. (14%)	Dullness	Decreased	Decreased
B. (4%)	Dullness	Increased	Bronchial
C. (8%)	Dullness	Increased	Decreased
D. (2%)	Hyperresonance	Decreased	Bronchial
✓ E. (65%)	Hyperresonance	Decreased	Decreased
F. (1%)	Hyperresonance	Decreased	Increased
G. (1%)	Resonance	Normal	Vesicular

Omitted
Correct answer
E

65%
Answered correctly

02 secs
Time Spent

06/17/2020
Last Updated

Pulmonary auscultation examination findings			
Condition	**Breath sounds**	**Tactile fremitus**	**Percussion**
Normal lung	Normal	Normal	Resonance
Consolidation	Increased	Increased	Dullness
Pleural effusion	Decreased or absent	Decreased	Dullness
Pneumothorax	Decreased or absent	Decreased	Hyperresonance
Atelectasis	Decreased or absent	Decreased	Dullness

This patient's chest x-ray after lung biopsy shows a right **pneumothorax**, which is recognized by the **continuous line** in the right lung field with **no visible lung markings** peripheral to it. This line is the outer edge of the collapsed right lung; the dark space peripheral to the lung represents air in the chest cavity.

The following characteristic physical examination findings are expected with pneumothorax:

- Tactile fremitus represents airway vibrations generated by vocalized sound (eg, saying "ninety-nine") and is measured by the examiner placing hands on the patient's back. Because air in the chest cavity insulates and dampens airway vibrations before they reach the patient's back, **decreased tactile fremitus** is expected **(Choice C)**.
- Breath sounds are caused by air movement within the airways, and the intensity varies by lung location. Vesicular breath sounds are normal over the periphery; bronchial breath sounds are higher-intensity sounds that are normal over the hilum but indicate pathology (eg, lobar consolidation) over the periphery. Because the lung is partially collapsed, leading to less air movement, and sounds from the airways are insulated by air in the chest cavity, **decreased breath sound intensity** is expected **(Choices D and F)**.
- Resonance refers to the frequency of sound generated by percussion, and it varies with density. Because air alone is less dense than a composite of lung parenchyma and air (ie, normal lung), higher-than-normal sound frequency to percussion (ie, **hyperresonance**) is

Visible lung markings peripheral to it. This line is the outer edge of the collapsed right lung; the dark space peripheral to the lung represents air in the chest cavity.

The following characteristic physical examination findings are expected with pneumothorax:

- Tactile fremitus represents airway vibrations generated by vocalized sound (eg, saying "ninety-nine") and is measured by the examiner placing hands on the patient's back. Because air in the chest cavity insulates and dampens airway vibrations before they reach the patient's back, **decreased tactile fremitus** is expected **(Choice C)**.
- Breath sounds are caused by air movement within the airways, and the intensity varies by lung location. Vesicular breath sounds are normal over the periphery; bronchial breath sounds are higher-intensity sounds that are normal over the hilum but indicate pathology (eg, lobar consolidation) over the periphery. Because the lung is partially collapsed, leading to less air movement, and sounds from the airways are insulated by air in the chest cavity, **decreased breath sound intensity** is expected **(Choices D and F)**.
- Resonance refers to the frequency of sound generated by percussion, and it varies with density. Because air alone is less dense than a composite of lung parenchyma and air (ie, normal lung), higher-than-normal sound frequency to percussion (ie, **hyperresonance**) is expected.

(Choice A) Like pneumothorax, fluid in the chest cavity (ie, pleural effusion) insulates airway vibrations and sounds, causing decreased tactile fremitus and breath sound intensity. However, because fluid is more dense than normal lung, dullness to percussion is expected. Atelectasis generates findings similar to those of pleural effusion; the collapsed lung reduces air movement and vibration within the airways, and the airless lung parenchyma is more dense than normal, air-filled lung.

(Choice B) Consolidated, fluid-filled lung (eg, lobar pneumonia) is more dense than normal lung. This leads to increased transmission of vibration and sound (ie, increased tactile fremitus and breath sound intensity) and dullness to percussion.

(Choice G) Normal lung demonstrates resonance to percussion, baseline tactile fremitus, and vesicular (normal-intensity) breath sounds.

Educational objective:
Pneumothorax is recognized on chest x-ray by a continuous line without lung markings peripheral to it. Decreased tactile fremitus, decreased breath sound intensity, and hyperresonance to percussion are expected on physical examination.

Settings

1
2
3
4
5
6

Item 2 of 6
Question Id: 19332

Mark | Previous | Next | Full Screen | Tutorial | Lab Values | Notes | Calculator | Reverse Color | Text Zoom | Settings

Condition	Breath sounds	Tactile fremitus	Percussion

Exhibit Display

Pneumothorax

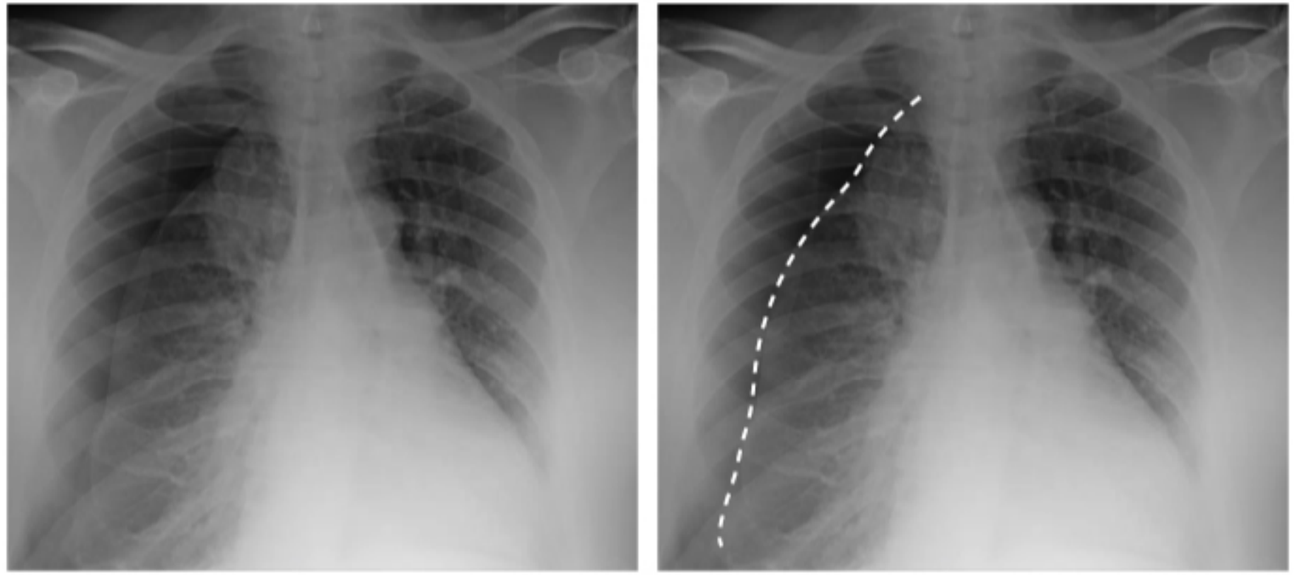

©UWorld

Zoom In | Zoom Out | Reset | Add To Flash Card

fremitus and breath sound intensity. However, because fluid is more dense than normal lung, dullness to percussion is expected. Atelectasis

Block Time Remaining: 00:00:05
TUTOR

0 | Feedback | Suspend | End Block

Settings

1
2
3
4
5
6

Item 3 of 6
Question Id: 527

Mark | Previous | Next | Full Screen | Tutorial | Lab Values | Notes | Calculator | Reverse Color | Text Zoom | Settings

A 24-year-old man comes to the office due to paroxysmal episodes of breathlessness and wheezing for the past 6 months. He does not recognize any triggers for these episodes and reports they are not associated with exercise or stress. The patient has no history of recent illness. He had eczema as a child. The patient has no other medical conditions and takes no medications. Vital signs are within normal limits. Lung examination shows good air movement and no wheezing. Sputum microscopy reveals many granule-containing cells and crystalloid masses. The sputum findings in this patient are a direct result of which of the following cytokines?

A. IL-1
B. IL-5
C. IL-12
D. Interferon-gamma
E. TGF-β

Submit

Block Time Remaining: 00:00:05
TUTOR

5 | Feedback | Suspend | End Block

A 24-year-old man comes to the office due to paroxysmal episodes of breathlessness and wheezing for the past 6 months. He does not recognize any triggers for these episodes and reports they are not associated with exercise or stress. The patient has no history of recent illness. He had eczema as a child. The patient has no other medical conditions and takes no medications. Vital signs are within normal limits. Lung examination shows good air movement and no wheezing. Sputum microscopy reveals many granule-containing cells and crystalloid masses. The sputum findings in this patient are a direct result of which of the following cytokines?

A. IL-1 (4%)
✓ B. IL-5 (71%)
C. IL-12 (8%)
D. Interferon-gamma (11%)
E. TGF-β (4%)

Omitted
Correct answer
B

71%
Answered correctly

02 secs
Time Spent

05/01/2020
Last Updated

Explanation

Pathogenesis of asthma

Initial exposure **Repeat exposure**

Pathogenesis of asthma

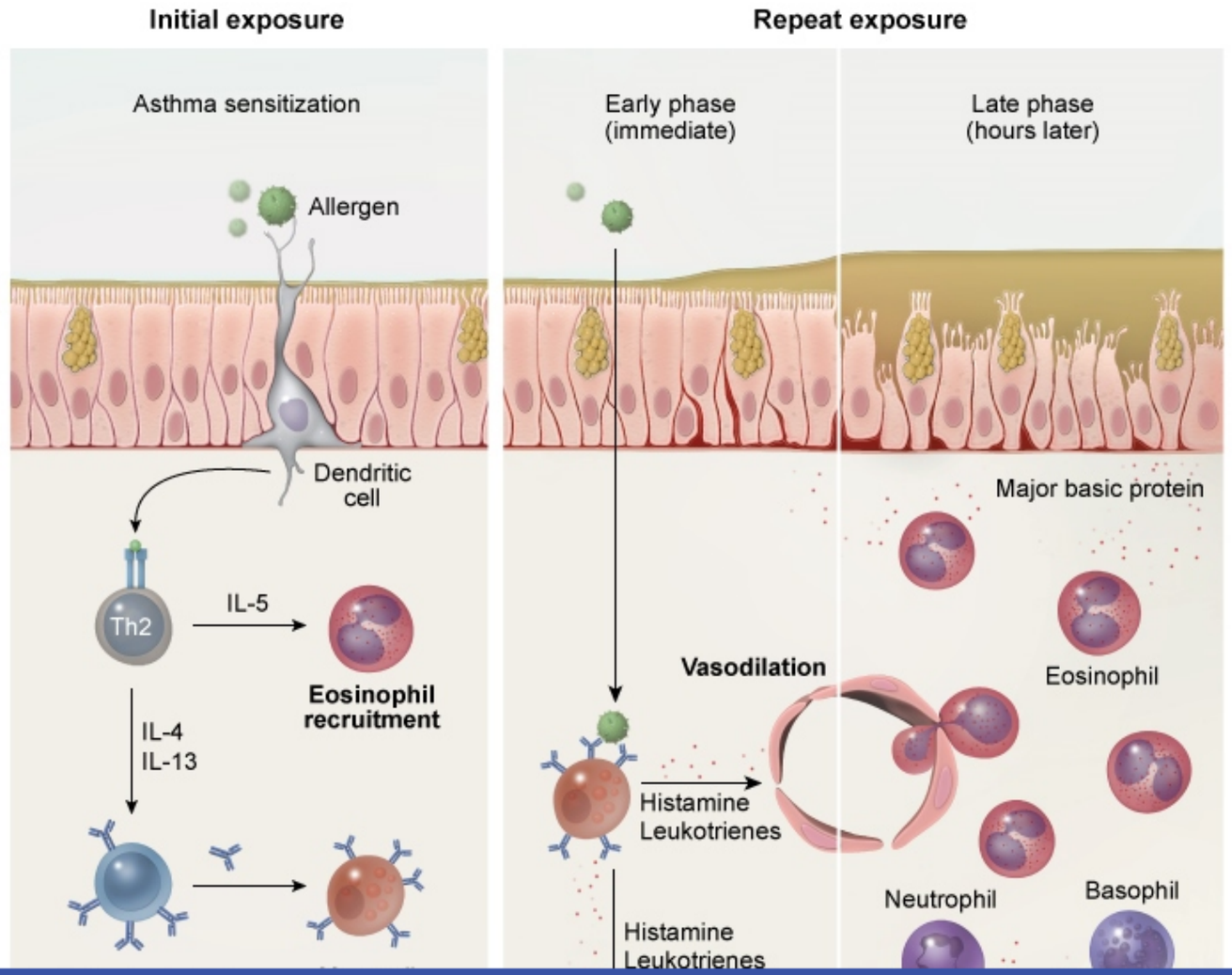

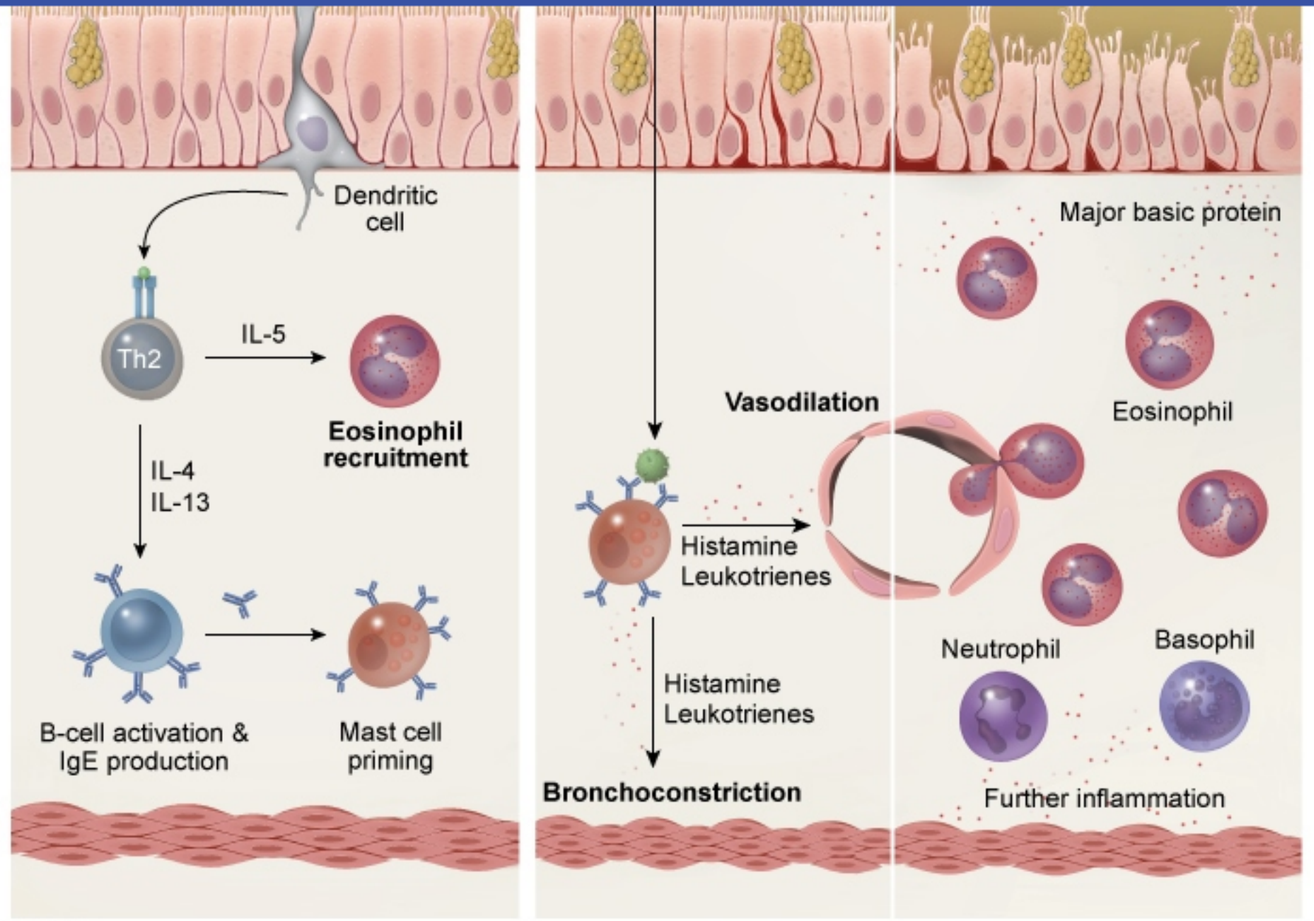

©UWorld

This young patient with paroxysmal dyspnea and wheezing likely has **asthma**, a disease characterized by airway inflammation, bronchial hyperreactivity, and a variable airflow obstruction. Symptoms that cannot be related to pulmonary infection, inhalation of irritants, stress, exercise, or aspirin ingestion should raise suspicion for **atopic (extrinsic) asthma**. Atopic asthma occurs in genetically predisposed individuals; patients often have a family history of asthma, allergies, or eczema. Sputum microscopy classically demonstrates elevated levels of eosinophils (granule-containing cells) with Charcot-Leyden crystals (bipyramidal-shaped accumulations of eosinophil membrane protein).

©UWorld

This young patient with paroxysmal dyspnea and wheezing likely has **asthma**, a disease characterized by airway inflammation, bronchial hyperreactivity, and a variable airflow obstruction. Symptoms that cannot be related to pulmonary infection, inhalation of irritants, stress, exercise, or aspirin ingestion should raise suspicion for **atopic (extrinsic) asthma**. Atopic asthma occurs in genetically predisposed individuals; patients often have a family history of asthma, allergies, or eczema. Sputum microscopy classically demonstrates elevated levels of eosinophils (granule-containing cells) with Charcot-Leyden crystals (bipyramidal-shaped accumulations of eosinophil membrane protein).

Atopic asthma occurs due to an excessive **T_H2-mediated** reaction to environmental aero-antigens (eg, pollen, pet dander). In response to allergic stimuli, these cells secrete **IL-5**, a critical cytokine for **eosinophilic activation**, **recruitment**, and **prolonged survival** in the bronchial mucosa. T_H2 cells also synthesize IL-4, which stimulates IgE formation by plasma cells. As with other type I hypersensitivity reactions, these antigen-specific antibodies bind to receptors on mast cells, and repeated exposure induces mast cell degranulation. This leads to bronchoconstriction, increased vascular permeability, and increased mucus production associated with acute asthma exacerbations. Eosinophils also release inflammatory mediators (ie, major basic protein, eosinophil cationic protein) that damage the bronchial epithelium later in the immune response.

(Choice A) Although IL-1 release from macrophages is involved in asthma pathogenesis, it is not a specific cytokine. IL-1 release is a component of almost all inflammatory processes and does not necessarily cause eosinophil infiltration.

(Choice C) IL-12 functions to promote the differentiation of T_H1 cells; it is not directly involved in eosinophil recruitment.

(Choice D) Interferon-gamma is secreted by helper T cells and functions to activate macrophages, thereby promoting adaptive immunity against intracellular pathogens. It is not directly chemotactic for eosinophils.

(Choice E) Transforming growth factor beta (TGF-β) is a growth factor involved in tissue regeneration and repair; high levels are associated with subepithelial fibrosis and airway remodeling seen in chronic asthma. However, it is not chemotactic for eosinophils.

Educational objective:
Paroxysmal breathlessness and wheezing in a young patient that are unrelated to ingestion of aspirin, pulmonary infection, inhalation of irritants, and/or exercise should raise a strong suspicion for atopic (extrinsic) asthma. Classic sputum findings include eosinophils and Charcot-Leyden crystals. Eosinophils are recruited and activated by IL-5 secreted by T_H2 type T cells.

Settings

1
2
3
4
5
6

Item 3 of 6
Question Id: 527

Mark | Previous | Next | Full Screen | Tutorial | Lab Values | Notes | Calculator | Reverse Color | Text Zoom | Settings

©UWorld

Exhibit Display

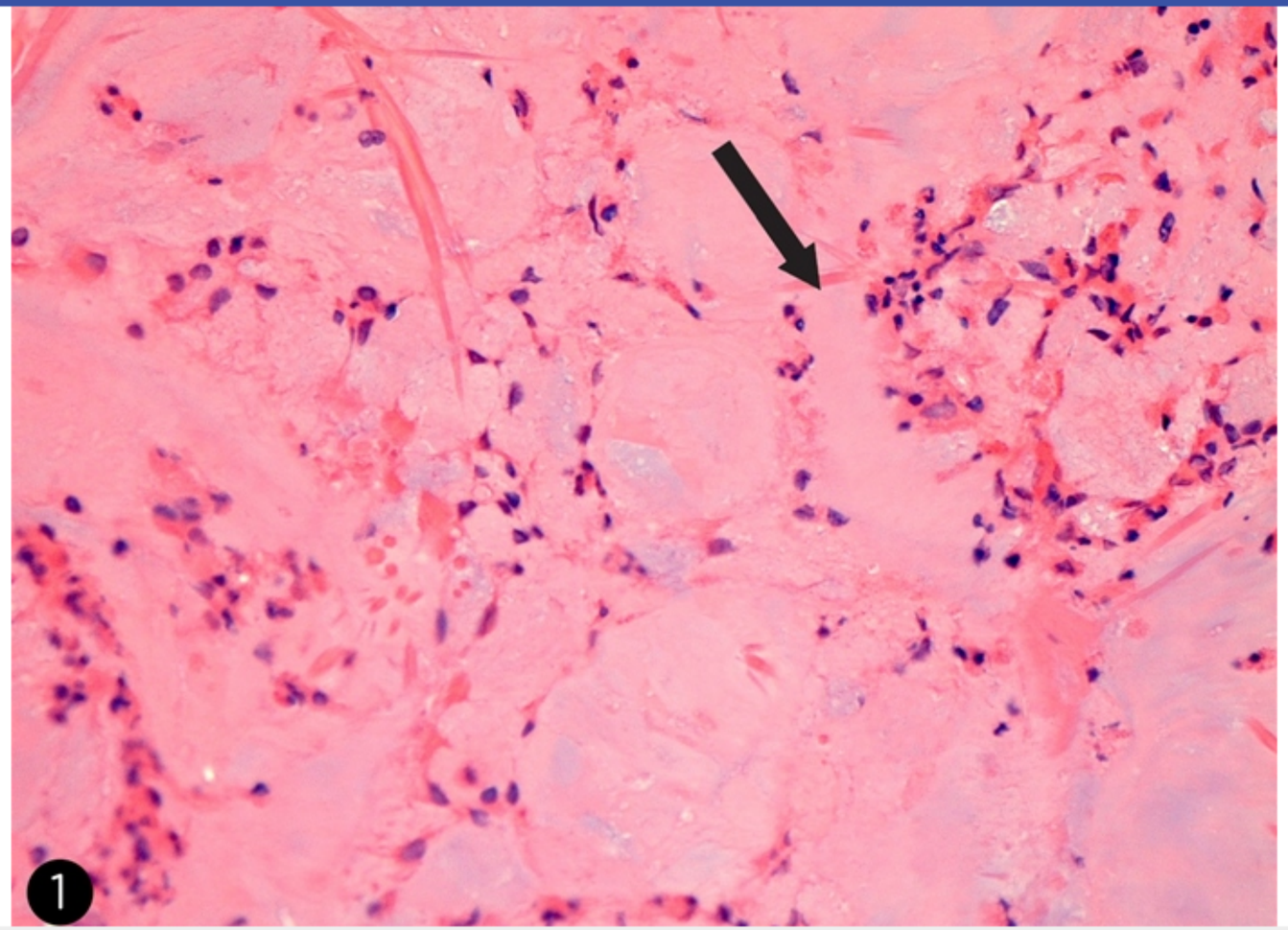

Zoom In | Zoom Out | Reset | Add To New Card | Existing Card

Block Time Remaining: 00:00:07
TUTOR

5 | Feedback | Suspend | End Block

Settings

1
2
3
4
5
6

Item 3 of 6
Question Id: 527

Mark | Previous | Next | Full Screen | Tutorial | Lab Values | Notes | Calculator | Reverse Color | Text Zoom | Settings

©UWorld

Exhibit Display

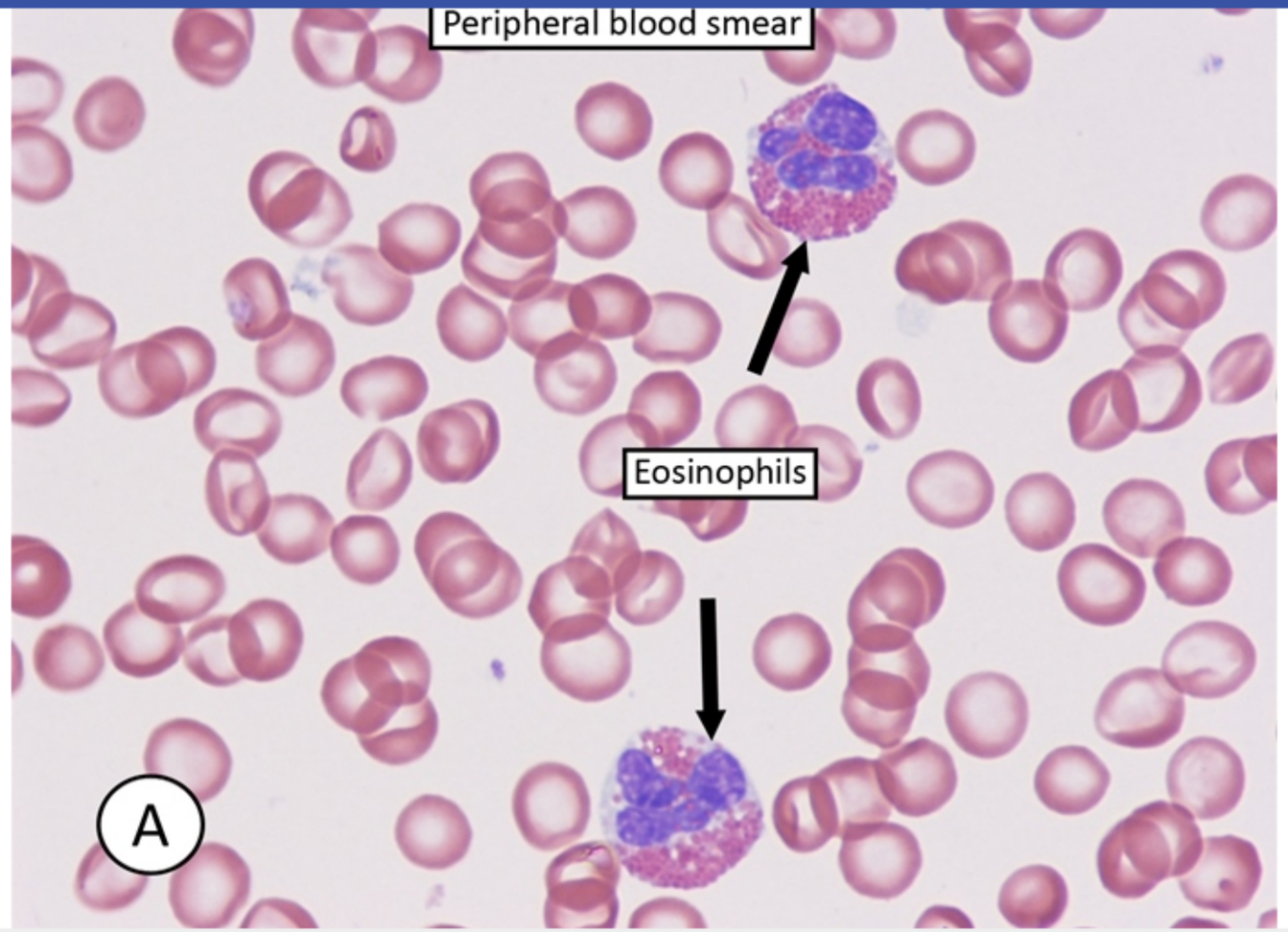

Zoom In | Zoom Out | Reset | Add To New Card | Existing Card

Block Time Remaining: 00:00:07
TUTOR

5 | Feedback | Suspend | End Block

often have a family history of asthma, allergies, or eczema. Sputum microscopy classically demonstrates elevated levels of eosinophils (granule-containing cells) with Charcot-Leyden crystals (bipyramidal-shaped accumulations of eosinophil membrane protein).

Atopic asthma occurs due to an excessive **T_H2-mediated** reaction to environmental aero-antigens (eg, pollen, pet dander). In response to allergic stimuli, these cells secrete **IL-5**, a critical cytokine for **eosinophilic activation**, **recruitment**, and **prolonged survival** in the bronchial mucosa. T_H2 cells also synthesize IL-4, which stimulates IgE formation by plasma cells. As with other type I hypersensitivity reactions, these antigen-specific antibodies bind to receptors on mast cells, and repeated exposure induces mast cell degranulation. This leads to bronchoconstriction, increased vascular permeability, and increased mucus production associated with acute asthma exacerbations. Eosinophils also release inflammatory mediators (ie, major basic protein, eosinophil cationic protein) that damage the bronchial epithelium later in the immune response.

(Choice A) Although IL-1 release from macrophages is involved in asthma pathogenesis, it is not a specific cytokine. IL-1 release is a component of almost all inflammatory processes and does not necessarily cause eosinophil infiltration.

(Choice C) IL-12 functions to promote the differentiation of T_H1 cells; it is not directly involved in eosinophil recruitment.

(Choice D) Interferon-gamma is secreted by helper T cells and functions to activate macrophages, thereby promoting adaptive immunity against intracellular pathogens. It is not directly chemotactic for eosinophils.

(Choice E) Transforming growth factor beta (TGF-β) is a growth factor involved in tissue regeneration and repair; high levels are associated with subepithelial fibrosis and airway remodeling seen in chronic asthma. However, it is not chemotactic for eosinophils.

Educational objective:
Paroxysmal breathlessness and wheezing in a young patient that are unrelated to ingestion of aspirin, pulmonary infection, inhalation of irritants, and/or exercise should raise a strong suspicion for atopic (extrinsic) asthma. Classic sputum findings include eosinophils and Charcot-Leyden crystals. Eosinophils are recruited and activated by IL-5 secreted by T_H2 type T cells.

Pathophysiology	Pulmonary & Critical Care	Asthma
Subject	System	Topic

Copyright © UWorld. All rights reserved.

Settings

1
2
3
4
5
6

Item 4 of 6
Question Id: 18928

Mark | Previous | Next | Full Screen | Tutorial | Lab Values | Notes | Calculator | Reverse Color | Text Zoom | Settings

A 60-year-old woman is brought to the hospital due to progressive shortness of breath and cough for 2 weeks. The patient was diagnosed with right breast cancer and completed radiation therapy 6 weeks ago. Temperature is 37.3 C (99.1 F), blood pressure is 110/70 mm Hg, pulse is 90/min, and respirations are 22/min. Oxygen saturation is 93% on room air. Examination reveals inspiratory crackles over the right lung anteriorly; the lungs are otherwise clear to auscultation. Chest radiograph shows ground-glass opacities in the right lung where radiation was delivered. Laboratory studies reveal no significant changes. Acute radiation-induced lung injury is suspected. Histopathologic examination would most likely reveal formation of which of the following?

- A. Alveolar hyaline membranes
- B. Hemosiderin-laden macrophages
- C. Necrotizing vasculitis
- D. Neutrophilic abscess

Submit

Block Time Remaining: 00:00:07
TUTOR

0 | Feedback | Suspend | End Block

A 60-year-old woman is brought to the hospital due to progressive shortness of breath and cough for 2 weeks. The patient was diagnosed with right breast cancer and completed radiation therapy 6 weeks ago. Temperature is 37.3 C (99.1 F), blood pressure is 110/70 mm Hg, pulse is 90/min, and respirations are 22/min. Oxygen saturation is 93% on room air. Examination reveals inspiratory crackles over the right lung anteriorly; the lungs are otherwise clear to auscultation. Chest radiograph shows ground-glass opacities in the right lung where radiation was delivered. Laboratory studies reveal no significant changes. Acute radiation-induced lung injury is suspected. Histopathologic examination would most likely reveal formation of which of the following?

- ✓ A. Alveolar hyaline membranes (69%)
- B. Hemosiderin-laden macrophages (9%)
- C. Necrotizing vasculitis (14%)
- D. Neutrophilic abscess (6%)

Omitted
Correct answer
A

69%
Answered correctly

01 sec
Time Spent

06/29/2020
Last Updated

Explanation

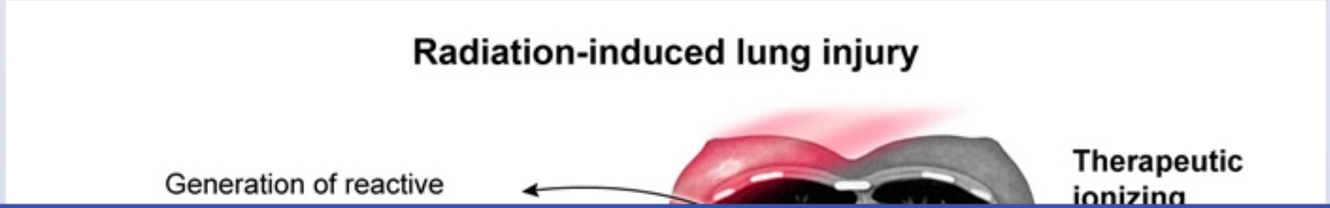

Radiation-induced lung injury

Therapeutic ionizing radiation

Generation of reactive oxygen and nitrogen species

↓

DNA and cellular damage

↓

Inflammatory response: Leukocyte infiltration, excess cytokine (eg, IL-1, IL-6, TNFα, TGF-β) production → Fibroblast proliferation with collagen deposition

↓

Acute manifestations (3-12 weeks)

- Impaired gas exchange

↓

Delayed manifestations (6-12 months)

- Diminished lung volume

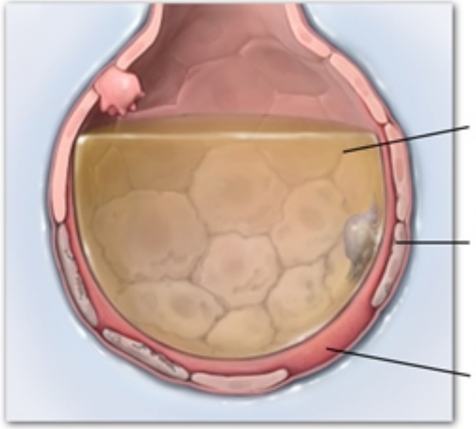

Radiation pneumonitis

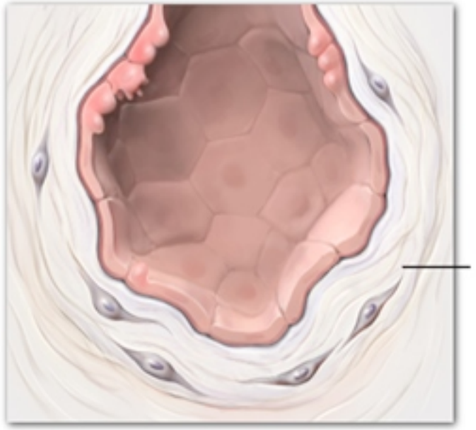

Pulmonary fibrosis

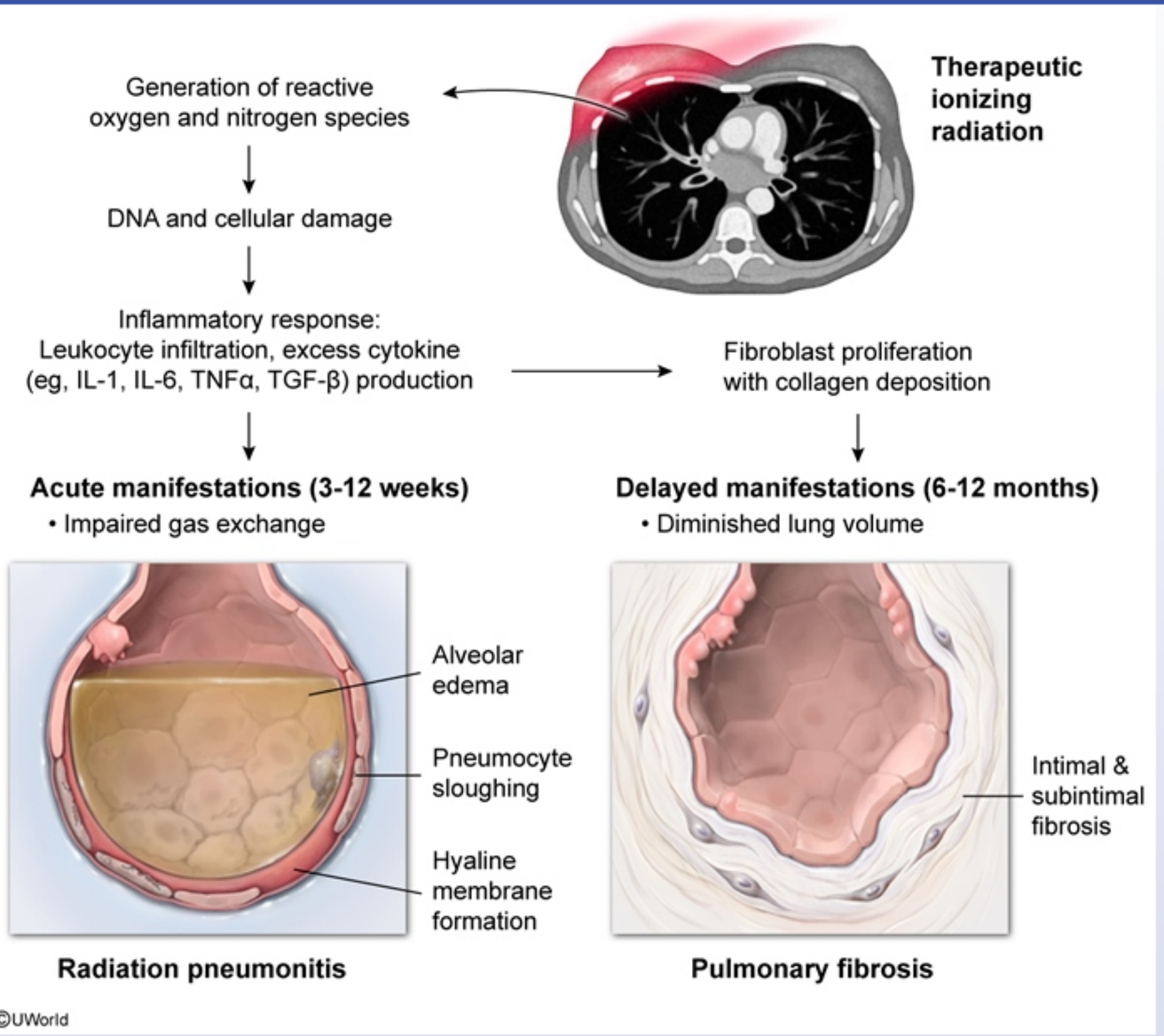
Generation of reactive oxygen and nitrogen species
DNA and cellular damage
Inflammatory response: Leukocyte infiltration, excess cytokine (eg, IL-1, IL-6, TNFα, TGF-β) production
Fibroblast proliferation with collagen deposition
Therapeutic ionizing radiation
Acute manifestations (3-12 weeks)
• Impaired gas exchange
Delayed manifestations (6-12 months)
• Diminished lung volume
Alveolar edema
Pneumocyte sloughing
Hyaline membrane formation
Intimal & subintimal fibrosis
Radiation pneumonitis
Pulmonary fibrosis
©UWorld

©UWorld

Radiation-induced lung injury usually occurs following **thoracic irradiation** for the treatment of malignancy (eg, breast or lung cancers, lymphoma). Ionizing radiation causes **DNA damage** directly (eg, double-strand breaks) and indirectly through generation of reactive oxygen and nitrogen species that can damage both DNA and other cellular components.

In the lung, this damage primarily affects the alveolar-capillary barrier, formed from alveolar epithelial cells (ie, **pneumocytes**) and vascular endothelial cells, and initiates an **inflammatory response** with a cascade of cytokines (eg, IL-1, TNFα) and growth factors (eg, PDGF, TGF-β). Manifestation vary based on chronicity:

- **Acutely**, immune-mediated damage results in impaired gas exchange due to **exudative alveolitis**, with sloughing of pneumocytes and vascular endothelial cells, alveolar/interstitial edema, and **hyaline membrane formation**. Clinically, this usually manifests as dyspnea and cough 3-12 weeks after initial radiation exposure.
- **Radiation fibrosis** is a **delayed** manifestation of radiation-induced lung injury that can develop 6-12 months after initial radiation exposure. TGF-β released by immune cells and the surrounding tissue initiates fibroblast proliferation, collagen deposition, and formation of **dense fibrous bands**. The result is decreased lung volume, dilated bronchi and bronchioles (ie, traction bronchiectasis), impaired mucociliary clearance, and predisposition to **chronic infections**.

(Choices B and C) Hemosiderin-laden macrophages (due to diffuse alveolar hemorrhage) and necrotizing vasculitis are both associated with autoimmune vasculitis (eg, anti-GBM disease). These patients typically have hemoptysis and/or other systemic effects of vasculitis (eg, glomerulonephritis, arthralgias).

(Choice D) Although significant neutrophilic infiltrate occurs in patients with radiation-induced lung injury, frank formation of an abscess usually occurs following introduction of anaerobic bacteria to the lung parenchyma due to aspiration (eg, alcoholism) or septic embolism.

Educational objective:
Radiation-induced lung injury typically occurs following thoracic irradiation (eg, breast cancer), which damages pneumocytes and vascular endothelial cells and initiates an inflammatory response (eg, IL-1, TNFα, TGF-β). This immune response can have both acute (eg, exudative alveolitis, hyaline membrane formation) and delayed (eg, dense fibrosis) effects that typically manifest with cough and dyspnea.

References

Manifestation vary based on chronicity:

- **Acutely**, immune-mediated damage results in impaired gas exchange due to **exudative alveolitis**, with sloughing of pneumocytes and vascular endothelial cells, alveolar/interstitial edema, and **hyaline membrane formation**. Clinically, this usually manifests as dyspnea and cough 3-12 weeks after initial radiation exposure.
- **Radiation fibrosis** is a **delayed** manifestation of radiation-induced lung injury that can develop 6-12 months after initial radiation exposure. TGF-β released by immune cells and the surrounding tissue initiates fibroblast proliferation, collagen deposition, and formation of **dense fibrous bands**. The result is decreased lung volume, dilated bronchi and bronchioles (ie, traction bronchiectasis), impaired mucociliary clearance, and predisposition to **chronic infections**.

(Choices B and C) Hemosiderin-laden macrophages (due to diffuse alveolar hemorrhage) and necrotizing vasculitis are both associated with autoimmune vasculitis (eg, anti-GBM disease). These patients typically have hemoptysis and/or other systemic effects of vasculitis (eg, glomerulonephritis, arthralgias).

(Choice D) Although significant neutrophilic infiltrate occurs in patients with radiation-induced lung injury, frank formation of an abscess usually occurs following introduction of anaerobic bacteria to the lung parenchyma due to aspiration (eg, alcoholism) or septic embolism.

Educational objective:
Radiation-induced lung injury typically occurs following thoracic irradiation (eg, breast cancer), which damages pneumocytes and vascular endothelial cells and initiates an inflammatory response (eg, IL-1, TNFα, TGF-β). This immune response can have both acute (eg, exudative alveolitis, hyaline membrane formation) and delayed (eg, dense fibrosis) effects that typically manifest with cough and dyspnea.

References

- Radiation-induced lung injury (RILI).

Pathophysiology	Pulmonary & Critical Care	Radiation injury
Subject	System	Topic

Copyright © UWorld. All rights reserved.

A 62-year-old man comes to the office for evaluation of progressive exertional dyspnea. His medical history is significant for pneumonia and hypertension. He has a 45-pack-year smoking history. On physical examination, breath sounds are decreased bilaterally and wheezes are heard. A CT scan of the chest is shown below.

Which of the following cells are most responsible for the development of this patient's lung condition?

A. Club cells

B. Eosinophils

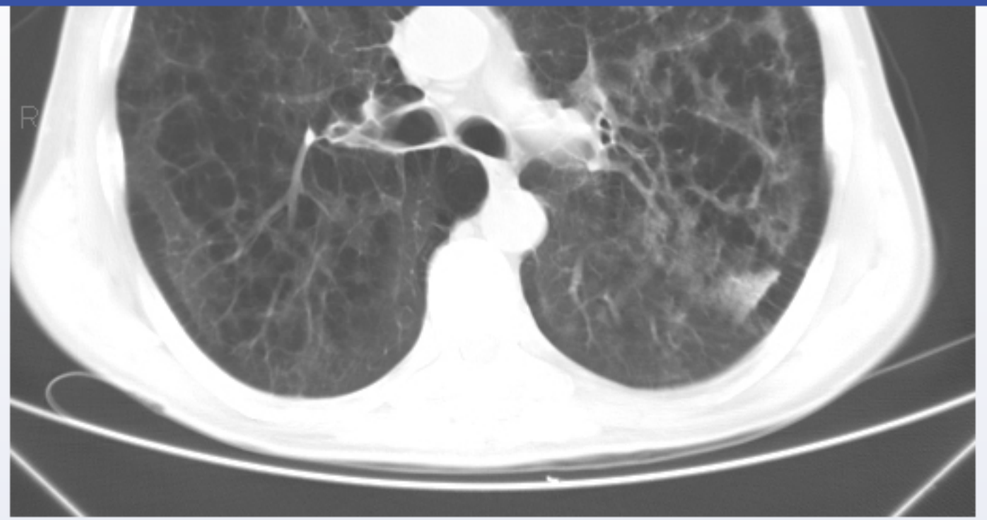

Which of the following cells are most responsible for the development of this patient's lung condition?

- A. Club cells
- B. Eosinophils
- C. Mast cells
- D. Neutrophils
- E. Type I pneumocytes
- F. Type II pneumocytes

Submit

Settings

1
2
3
4
5
6

Item 5 of 6
Question Id: 488

Mark | Previous | Next | Full Screen | Tutorial | Lab Values | Notes | Calculator | Reverse Color | Text Zoom | Settings

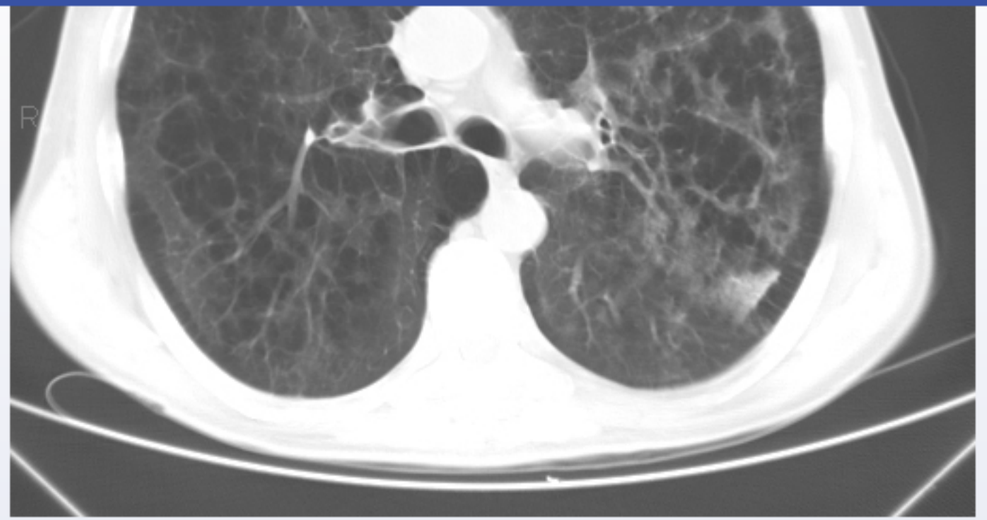

Which of the following cells are most responsible for the development of this patient's lung condition?

- A. Club cells (6%)
- B. Eosinophils (4%)
- C. Mast cells (5%)
- ✓ D. Neutrophils (58%)
- E. Type I pneumocytes (8%)
- F. Type II pneumocytes (17%)

Omitted
Correct answer

58%
Answered correctly

16 secs
Time Spent

02/14/2020
Last Updated

Block Time Remaining: 00:00:24
TUTOR

5 | Feedback | Suspend | End Block

Settings

1
2
3
4
5
6

Item 5 of 6
Question Id: 488

Mark | Previous | Next | Full Screen | Tutorial | Lab Values | Notes | Calculator | Reverse Color | Text Zoom | Settings

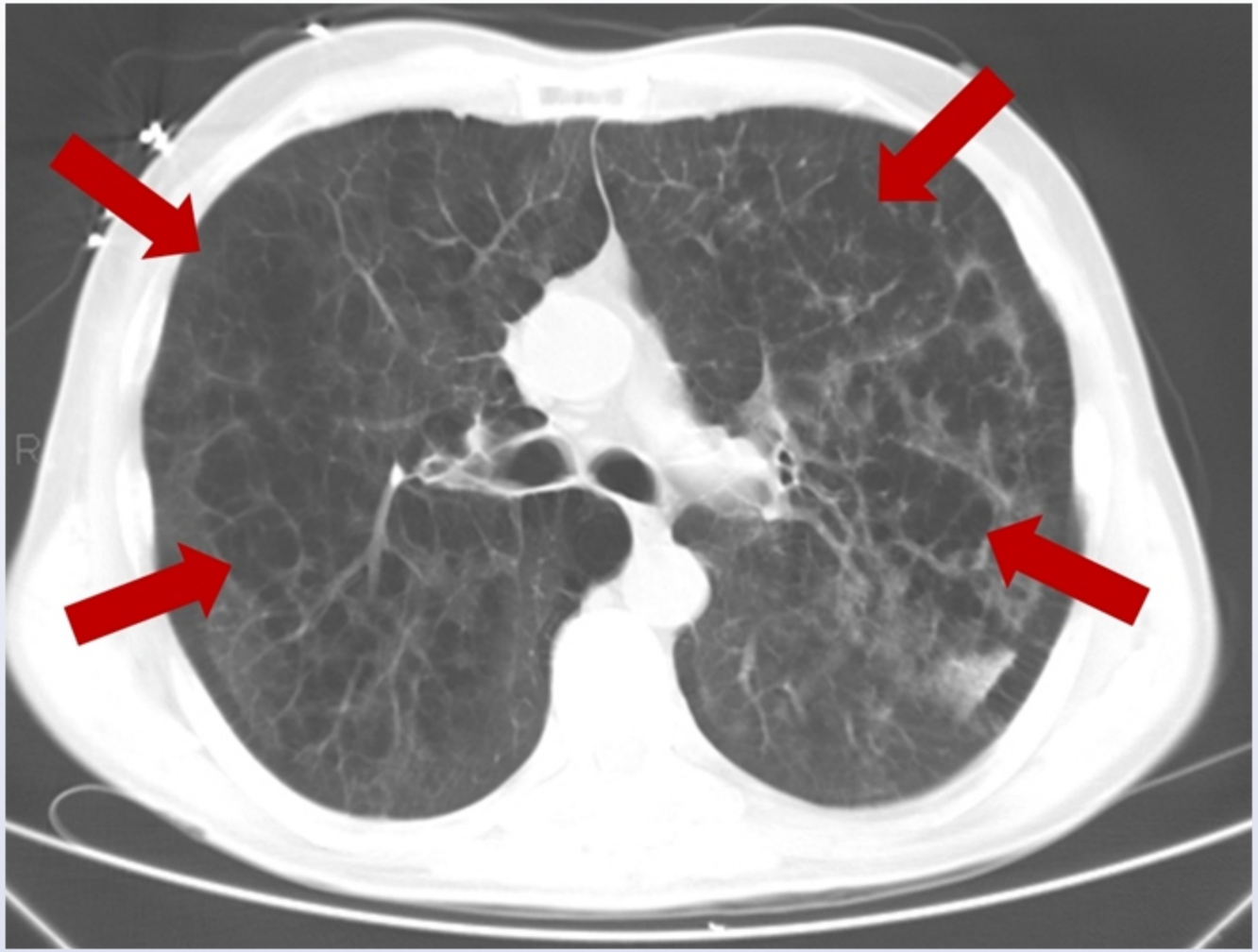

This patient's heavy smoking history, exertional dyspnea, and **dilated airspaces** (red arrows) on CT scan (compared with normal) are indicative of **centriacinar emphysema**. The pathogenesis of smoking-induced emphysema involves oxidative injury to the respiratory bronchioles and activation of resident alveolar macrophages by components of cigarette smoke. This is followed by inflammatory recruitment of neutrophils into

Block Time Remaining: 00:00:24
TUTOR

5 | Feedback | Suspend | End Block

This patient's heavy smoking history, exertional dyspnea, and **dilated airspaces** (red arrows) on CT scan (compared with normal) are indicative of **centriacinar emphysema**. The pathogenesis of smoking-induced emphysema involves oxidative injury to the respiratory bronchioles and activation of resident alveolar macrophages by components of cigarette smoke. This is followed by inflammatory recruitment of neutrophils into the affected airspaces. Activated **macrophages** and **neutrophils** release **proteases**, including elastase and others (eg, cathepsins, matrix metalloproteinases), that degrade the extracellular matrix and also generate oxygen free radicals that impair the function of protease inhibitors (eg, alpha-1 antitrypsin). The resultant **protease-antiprotease imbalance** leads to acinar wall destruction and irreversible airspace dilation distal to the terminal bronchioles.

Excess protease activity is also implicated in panacinar emphysema, such as occurs with alpha-1 antitrypsin deficiency.

(Choice A) Club (formerly Clara) cells are nonciliated, secretory constituents of the terminal respiratory epithelium. They secrete club cell secretory protein and surfactant components and also help detoxify inhaled substances (eg, tobacco smoke) by a cytochrome P450 mechanism.

(Choice B) Eosinophils play an important role in the late-phase component of Type I immediate hypersensitivity reactions. In the lung, they are recruited to help sustain the localized inflammatory response that follows exposure to allergens.

(Choice C) Interstitial pulmonary mast cells play a central role in the pathogenesis of allergic asthma by releasing histamine and leukotrienes that induce bronchospasm.

(Choice E) Type I pneumocytes constitute >95% of the inner epithelial lining of the alveoli. In emphysema, these cells are destroyed by the acinar wall damage inflicted by neutrophils and other inflammatory cells.

(Choice F) Type II pneumocytes are the source of pulmonary surfactant and the main cell type responsible for repair of alveolar epithelium after destruction of Type I pneumocytes.

Educational objective:
The pathogenesis of centriacinar emphysema associated with chronic, heavy smoking predominantly involves the release of proteases, especially elastase, from infiltrating neutrophils and alveolar macrophages.

Pathophysiology Pulmonary & Critical Care COPD

A 48-year-old man comes to the office for an initial visit. He says that he feels well and has no medical problems. The patient has a 20-pack-year smoking history and does not use alcohol or illicit drugs. He is counseled on smoking cessation. To explain how smoking affects lung function, the patient is shown a graph of the expected change in forced expiratory volume in 1 second (FEV1) over time if he continues to smoke at the same rate (curve D in image). Which of the following curves most likely demonstrates the expected FEV1 over time if this patient were to stop smoking now?

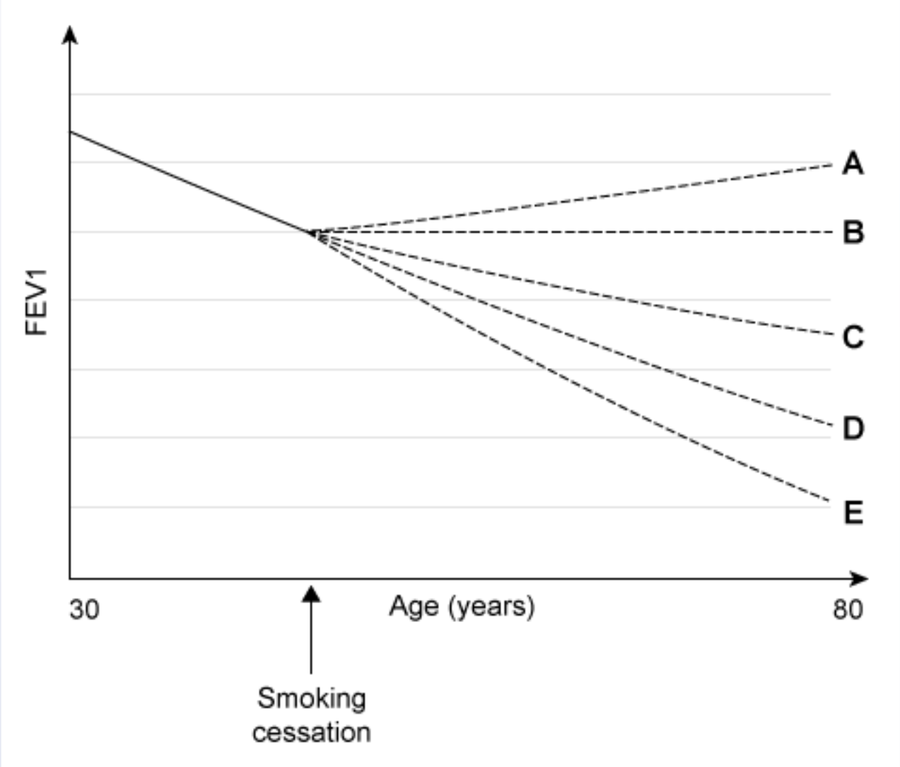

A. A

B. B

Settings

1
2
3
4
5
6

Item 6 of 6
Question Id: 7558

Mark | Previous | Next | Full Screen | Tutorial | Lab Values | Notes | Calculator | Reverse Color | Text Zoom | Settings

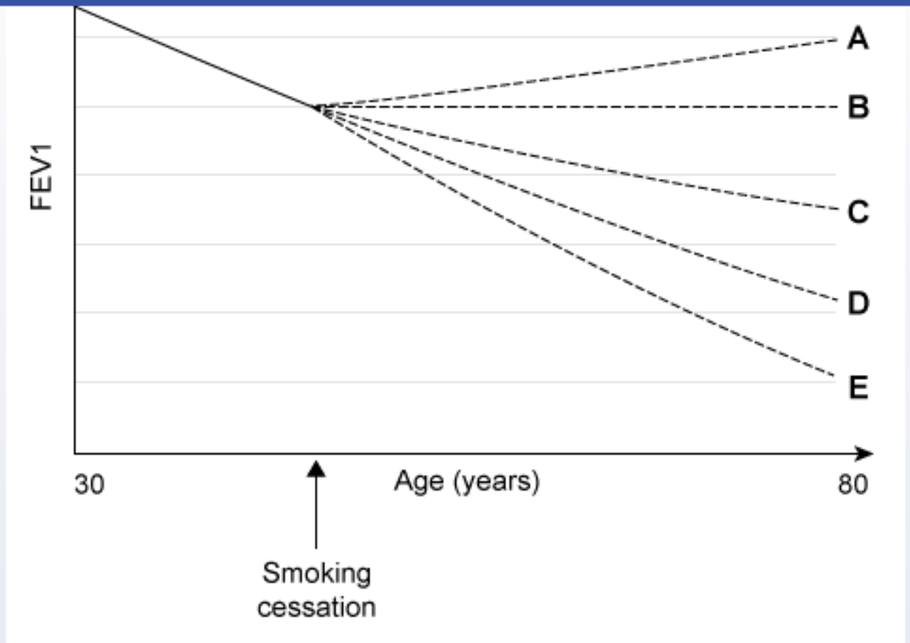

A. A (21%)
B. B (23%)
✓ C. C (49%)
D. D (3%)
E. E (2%)

Omitted
Correct answer

49%
Answered correctly

05 secs
Time Spent

01/30/2020
Last Updated

Block Time Remaining: 00:00:29
TUTOR

3 | Feedback | Suspend | End Block

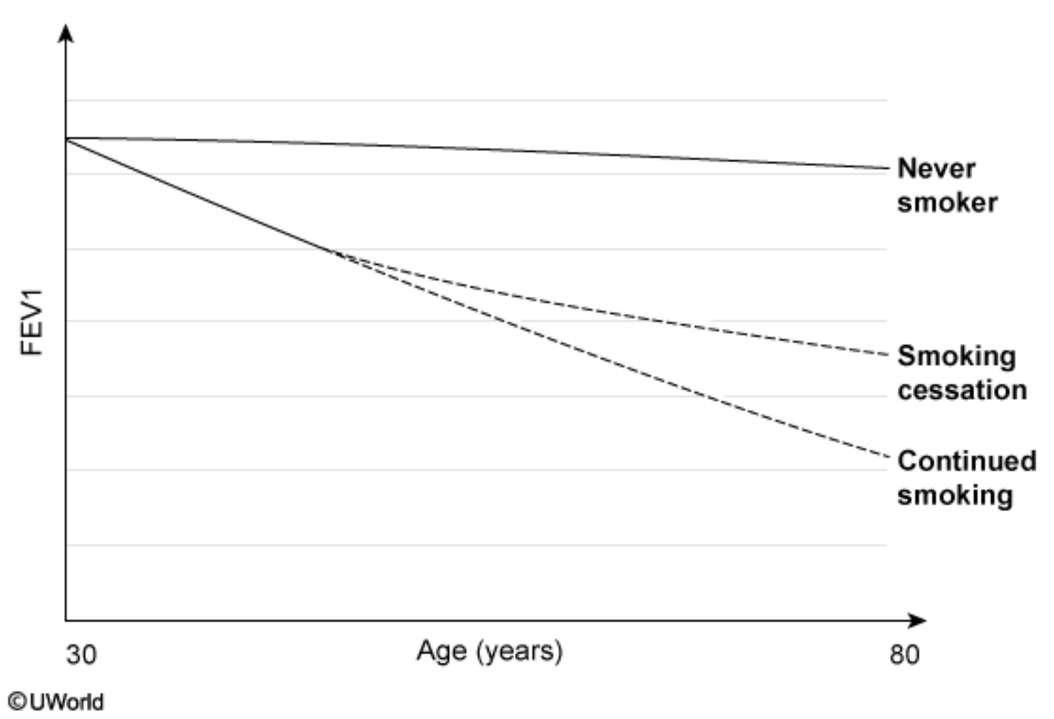

Smoking is the strongest risk factor for **chronic obstructive pulmonary disease** (COPD). Cigarette smoke contains numerous toxins (eg, formaldehyde, cadmium) that **impair ciliary function** (contributing to chronic bronchitis) and cause **oxidative cellular damage** (contributing to centrilobular emphysema). These changes are responsible for the airway obstruction and air-trapping that cause the reduction in forced expiratory volume in 1 second (FEV1) that characterizes COPD.

Beginning at approximately age 30, there is a gradual decline in FEV1 with age. Smoking-induced lung damage in COPD rapidly accelerates this normal age-related decline in FEV1, and once the decline occurs it is not recoverable. However, **smoking cessation** can markedly **slow the decline in FEV1** in patients with COPD, an improvement that is typically apparent within the first year of smoking cessation.

Following smoking cessation, the trajectory of this patient's FEV1 decline will improve compared with if he had continued to smoke, but his FEV1 will not return to the level it would have been had he never smoked. This trajectory is best represented by curve C.

formaldehyde, cadmium) that **impair ciliary function** (contributing to chronic bronchitis) and cause **oxidative cellular damage** (contributing to centrilobular emphysema). These changes are responsible for the airway obstruction and air-trapping that cause the reduction in forced expiratory volume in 1 second (FEV1) that characterizes COPD.

Beginning at approximately age 30, there is a gradual decline in FEV1 with age. Smoking-induced lung damage in COPD rapidly accelerates this normal age-related decline in FEV1, and once the decline occurs it is not recoverable. However, **smoking cessation** can markedly **slow the decline in FEV1** in patients with COPD, an improvement that is typically apparent within the first year of smoking cessation.

Following smoking cessation, the trajectory of this patient's FEV1 decline will improve compared with if he had continued to smoke, but his FEV1 will not return to the level it would have been had he never smoked. This trajectory is best represented by curve C.

(Choice A) It is not physiologically possible for FEV1 to increase with age in either smokers or nonsmokers.

(Choice B) The FEV1 does not remain constant after age 30, even in nonsmokers.

(Choice D) With smoking cessation, the trajectory of this patient's FEV1 decline will improve rather than stay the same.

(Choice E) This patient would experience a more rapid decline in FEV1 if he were to increase his rate of smoking.

Educational objective:
Smoking is the strongest risk factor for chronic obstructive pulmonary disease (COPD) and is responsible for accelerated decline in forced expiratory volume in 1 second (FEV1) in patients with COPD. Smoking cessation will slow the accelerated decline in FEV1, but FEV1 will not return to the level it would have been had the patient never smoked.

References

- Smoking cessation: effects on symptoms, spirometry and future trends in COPD.

Pathophysiology	Pulmonary & Critical Care	COPD
Subject	System	Topic

Copyright © UWorld. All rights reserved.

formaldehyde, cadmium) that **impair ciliary function** (contributing to chronic bronchitis) and cause **oxidative cellular damage** (contributing to

Exhibit Display

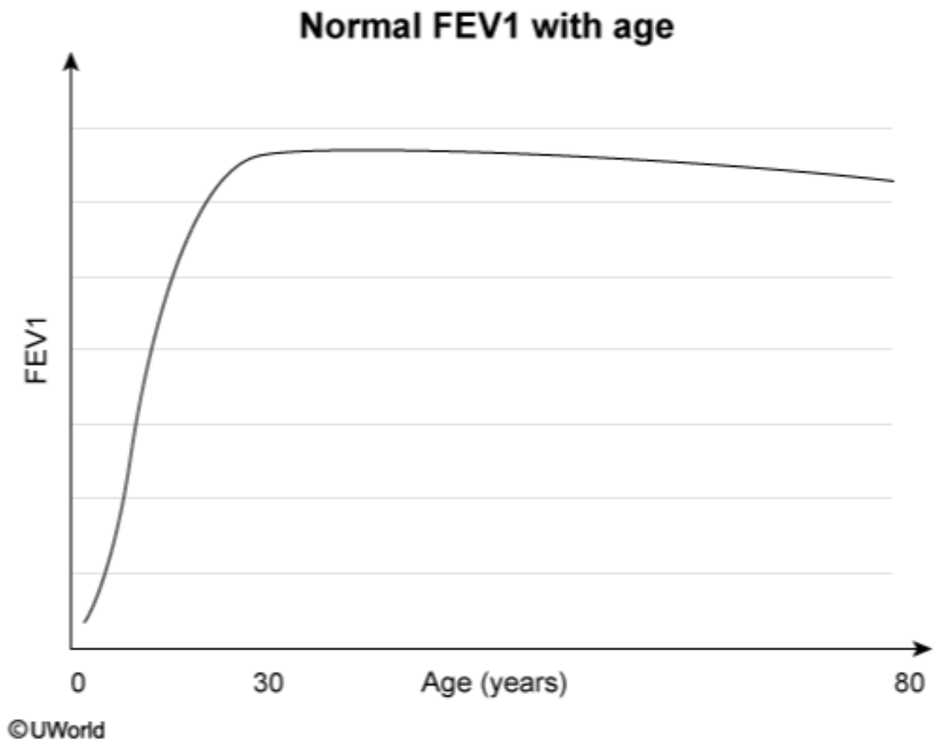

Zoom In | Zoom Out | Reset | Add To New Card | Existing Card

An 8-year-old boy is brought to the office for rapid and irregular movements of his hands for one week. His parents say that he is also making unintentional "funny faces" and has trouble controlling the volume of his voice. His temperature is 38.9 C (102 F). On physical examination, the boy moves his hands frequently and erratically. He has a new III/VI systolic murmur and several circular, faintly erythematous lesions on his abdomen. Which of the following is the most likely mechanism for this patient's condition?

A. Nonspecific T cell receptor activation

B. Cross-reactivity of antibodies against bacterial and host antigens

C. Embolization of an infected thrombus

D. Injury from immune complex deposition

E. Release of an erythrogenic toxin

Submit

An 8-year-old boy is brought to the office for rapid and irregular movements of his hands for one week. His parents say that he is also making unintentional "funny faces" and has trouble controlling the volume of his voice. His temperature is 38.9 C (102 F). On physical examination, the boy moves his hands frequently and erratically. He has a new III/VI systolic murmur and several circular, faintly erythematous lesions on his abdomen. Which of the following is the most likely mechanism for this patient's condition?

- A. Nonspecific T cell receptor activation (4%)
- ✓ B. Cross-reactivity of antibodies against bacterial and host antigens (71%)
- C. Embolization of an infected thrombus (5%)
- D. Injury from immune complex deposition (8%)
- E. Release of an erythrogenic toxin (10%)

Omitted
Correct answer
B

71%
Answered correctly

42 secs
Time Spent

07/02/2020
Last Updated

Explanation

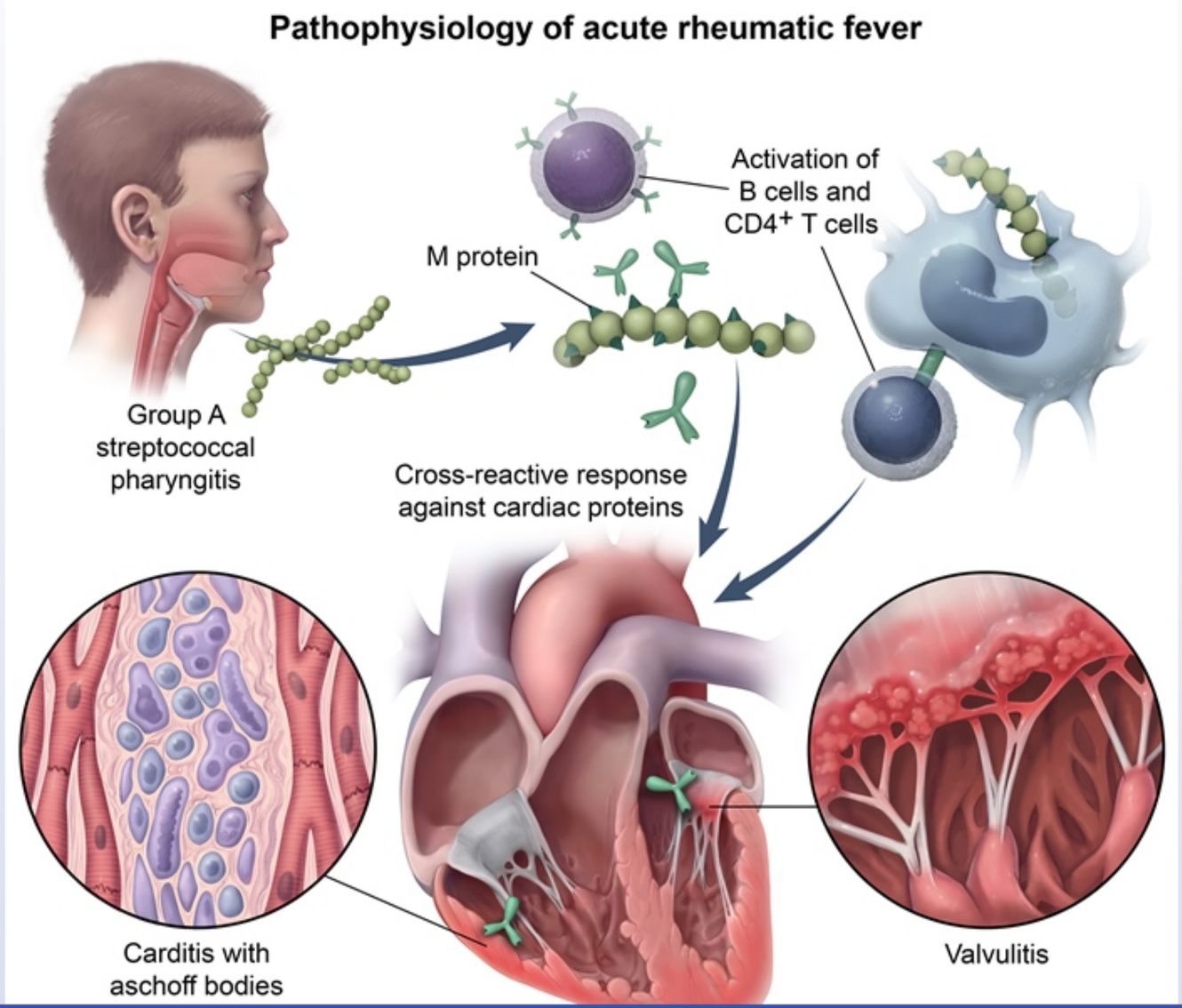
Pathophysiology of acute rheumatic fever
Activation of B cells and CD4+ T cells
M protein
Group A streptococcal pharyngitis
Cross-reactive response against cardiac proteins
Carditis with aschoff bodies
Valvulitis

This patient has acute rheumatic fever, an immune-mediated disease following an untreated **group A streptococcal** (GAS) infection. Antibodies against GAS **cross-react** with host tissues due to **molecular mimicry** between GAS antigens and cardiac and central nervous system antigens. Specifically, antibodies directed against GAS antigens, **M protein** and **N-acetyl-beta-D-glucosamine**, subsequently attack myosin, a cardiac protein, and lysoganglioside, a neuronal cell surface protein.

The major manifestations of acute rheumatic fever include arthritis, pancarditis, Sydenham chorea, erythema marginatum, and subcutaneous nodules. This patient's murmur is likely due to acute **mitral regurgitation** from pancarditis. **Sydenham chorea** presents with non-rhythmic movements of the hands, feet, and face. Patients often have sudden changes in voice pitch and volume. Erythema marginatum presents as faintly erythematous, circular lesions with central clearing that come and go on the trunk and extremities.

(Choice A) Superantigens cause a tremendous release of cytokines through nonspecific T cell receptor activation, leading to acute fever, hypotension, and erythroderma. This is the mechanism of action of the toxic shock syndrome exotoxins produced by both *Staphylococcus aureus* and *Streptococcus pyogenes*.

(Choice C) An embolic stroke from infective endocarditis can present with fever, a new-onset murmur, and focal neurologic deficits. In addition, Janeway lesions, Osler nodes, and Roth spots are specific findings of infectious endocarditis. The most common pathogens are *S aureus*, viridans group streptococci, and enterococci.

(Choice D) The deposition of streptococcal antigen immune complexes in glomeruli causes post-streptococcal glomerulonephritis, a type III hypersensitivity reaction. Patients have microscopic or gross hematuria, edema, hypertension, and proteinuria.

(Choice E) Scarlet fever is caused by the body's response to an erythrogenic (pyrogenic) toxin released by group A *Streptococcus*. It presents with a diffuse, erythematous, "sandpaper"-textured rash most notable in the skin folds (eg, inguinal, axillary, antecubital areas). Scarlet fever can occur with pharyngitis and can lead to acute rheumatic fever if untreated.

Educational objective:
Acute rheumatic fever is an autoimmune reaction following an untreated group A streptococcal pharyngitis. Anti-group A *Streptococcus* antibodies (eg, anti-M protein, anti-N-acetyl-beta-D-glucosamine) cross-react and attack cardiac and central nervous system antigens.

References

- Rheumatic fever, autoimmunity, and molecular mimicry: the streptococcal connection

This patient has acute rheumatic fever, an immune-mediated disease following an untreated **group A streptococcal** (GAS) infection. Antibodies against GAS **cross-react** ... s. Specifically, antibodies dir... protein, and lysoganglioside...

The major manifestations ... nodules. This patient's m... movements of the hands, ... faintly erythematous, circu...

(Choice A) Superantigen ... hypotension, and erythrod... *eus* and *Streptococcus pyoge*...

(Choice C) An embolic st... n, Janeway lesions, Osler no... viridans group streptococc...

(Choice D) The depositio... hypersensitivity reaction.

(Choice E) Scarlet fever ... s with a diffuse, erythemato... an occur with pharyngitis and...

Educational objective:
Acute rheumatic fever is a... dies (eg, anti-M protein, anti-N...

References

- Rheumatic fever, autoimmunity, and molecular mimicry: the streptococcal connection

Exhibit Display

Acute rheumatic fever	
Epidemiology	• Endemic in developing countries
Pathogenesis	• Occurs 2-4 weeks after acute group A streptococcal pharyngitis • Molecular mimicry: Anti-streptococcal antibodies attack cardiac & neuronal antigens

Clinical features	• Acute/subacute
	  ◦ Migratory arthritis
	  ◦ Pancarditis (mitral regurgitation)
	  ◦ Sydenham chorea
	• Chronic
	  ◦ Mitral stenosis

Prevention	• Prompt treatment of streptococcal pharyngitis with penicillin

Add To New Card | Existing Card

Settings

1
2
3
4

Item 1 of 4
Question Id: 724

Mark | Previous | Next | Full Screen | Tutorial | Lab Values | Notes | Calculator | Reverse Color | Text Zoom | Settings

This patient has acute rheumatic fever, an immune mediated disease following an untreated group A streptococcal (GAS) infection. Antibodies

Exhibit Display

Zoom In | Zoom Out | Reset | Add To New Card | Existing Card

Rheumatic fever, autoimmunity, and molecular mimicry: the streptococcal connection

Block Time Remaining: 00:00:42
TUTOR

5 | Feedback | Suspend | End Block

(Choice A) Superantigens cause a tremendous release of cytokines through nonspecific T cell receptor activation, leading to acute fever, hypotension, and erythroderma. This is the mechanism of action of the toxic shock syndrome exotoxins produced by both *Staphylococcus aureus* and *Streptococcus pyogenes*.

(Choice C) An embolic stroke from infective endocarditis can present with fever, a new-onset murmur, and focal neurologic deficits. In addition, Janeway lesions, Osler nodes, and Roth spots are specific findings of infectious endocarditis. The most common pathogens are *S aureus*, viridans group streptococci, and enterococci.

(Choice D) The deposition of streptococcal antigen immune complexes in glomeruli causes post-streptococcal glomerulonephritis, a type III hypersensitivity reaction. Patients have microscopic or gross hematuria, edema, hypertension, and proteinuria.

(Choice E) Scarlet fever is caused by the body's response to an erythrogenic (pyrogenic) toxin released by group A *Streptococcus*. It presents with a diffuse, erythematous, "sandpaper"-textured rash most notable in the skin folds (eg, inguinal, axillary, antecubital areas). Scarlet fever can occur with pharyngitis and can lead to acute rheumatic fever if untreated.

Educational objective:
Acute rheumatic fever is an autoimmune reaction following an untreated group A streptococcal pharyngitis. Anti-group A *Streptococcus* antibodies (eg, anti-M protein, anti-N-acetyl-beta-D-glucosamine) cross-react and attack cardiac and central nervous system antigens.

References

- Rheumatic fever, autoimmunity, and molecular mimicry: the streptococcal connection.
- Streptococcus and rheumatic fever.
- Acute rheumatic fever and streptococci: the quintessential pathogenic trigger of autoimmunity.

Pathophysiology	Infectious Diseases	Rheumatic fever
Subject	System	Topic

Copyright © UWorld. All rights reserved.

A 37-year-old woman comes to the office due to right-sided abdominal discomfort that has been getting progressively worse over the past few weeks. She has not had any nausea or vomiting. The patient's family moved to the United States from rural Kazakhstan when she was a child. The patient has no drug allergies. She does not use tobacco or alcohol. She has a dog at home. Temperature is 36.7 C (98.1 F). Physical examination is notable for hepatomegaly. Ultrasound reveals a large liver mass with cystic lesions. During surgery to resect the mass, the patient suffers from a procedural complication and dies. At the family's request, an autopsy is performed. A cut section of a portion of the mass is shown in the image below.

Displayed with permission from Springer Healthcare Ltd. © Copyright 1997, 2004 by Current Medicine

Displayed with permission from Springer Healthcare Ltd. © Copyright 1997, 2004 by Current Medicine

Which of the following is the most likely cause of this patient's death?

- A. Anaphylaxis
- B. Fulminant liver failure
- C. Hypovolemia
- D. Pulmonary embolism
- E. Septic shock

Submit

Displayed with permission from Springer Healthcare Ltd. © Copyright 1997, 2004 by Current Medicine

Which of the following is the most likely cause of this patient's death?

- A. Anaphylaxis
- B. Fulminant liver failure
- C. Hypovolemia
- D. Pulmonary embolism
- E. Septic shock

Submit

Displayed with permission from Springer Healthcare Ltd. © Copyright 1997, 2004 by Current Medicine

Which of the following is the most likely cause of this patient's death?

- ✓ A. Anaphylaxis (48%)
- B. Fulminant liver failure (12%)
- C. Hypovolemia (6%)
- D. Pulmonary embolism (15%)
- E. Septic shock (17%)

Omitted
Correct answer

48%
Answered correctly

01 min, 02 secs
Time Spent

06/22/2020
Last Updated

Explanation

The tapeworm ***Echinococcus granulosus*** is the most common cause of **hydatid cysts**. Most cases occur in individuals from endemic regions (eg, eastern Mediterranean, Middle East, South America, sub-Saharan Africa, former Soviet Union, western China) or those residing in the southwestern United States with **sheep** and **dog** (participate in the tapeworm life cycle) exposure. Initial infection is generally asymptomatic, with subsequent manifestations depending on cyst location and size. The **liver** is often affected (leading to hepatomegaly or right upper quadrant pain), but other organs such as the lungs or muscles can be involved. Unilocular lesions are typical of *E granulosus*, and multilocular lesions are typical of *E multilocularis*.

When infection occurs, echinococcal larvae implant within the capillaries, triggering an inflammatory reaction involving monocytes and eosinophils. Some larvae encyst. Microscopic examination demonstrates an encapsulated and calcified cyst ("**eggshell calcification**") containing fluid and budding cells that will eventually become daughter cysts. The outer wall is composed of gelatinous sheets surrounded by a thick fibrous capsule. Imaging (ultrasound, CT, MRI) and serology testing can be used for diagnosis.

Depending on the size of the cyst, surgery and adjunctive chemotherapy (eg, albendazole) are the treatment of choice for symptomatic patients. Cyst manipulation (eg, surgery, aspiration) should be performed with caution, as spilling of cyst contents can cause **anaphylactic shock**, which likely occurred in this patient.

(Choices B, C, D, and E) Fulminant liver failure can arise due to numerous conditions, including viral hepatitis, acetaminophen toxicity, idiosyncratic drug reactions, or Wilson disease. Hypovolemia is typically caused by severe blood loss, although excessive loss of other bodily fluids (eg, diarrhea, vomiting, burns, dehydration) may also be responsible. Pulmonary emboli are typically caused by the propagation of venous thrombi, with less common sources including air bubbles, fat droplets, amniotic fluid, or clumps of parasites or malignant cells. Overwhelming systemic infection with bacterial organisms can cause septic shock (hypotension, low blood flow). None of these conditions is typically associated with hydatid cysts.

Educational objective:
Echinococcus granulosus is the most common cause of hydatid cysts. Spilling of cyst contents can cause anaphylactic shock. Surgical manipulation should be performed with caution.

southwestern United States with **sheep** and **dog** (participate in the tapeworm life cycle) exposure. Initial infection is generally asymptomatic, with subsequent manifestations depending on cyst location and size. The **liver** is often affected (leading to hepatomegaly or right upper quadrant pain), but other organs such as the lungs or muscles can be involved. Unilocular lesions are typical of *E granulosus*, and multilocular lesions are typical of *E multilocularis*.

When infection occurs, echinococcal larvae implant within the capillaries, triggering an inflammatory reaction involving monocytes and eosinophils. Some larvae encyst. Microscopic examination demonstrates an encapsulated and calcified cyst ("**eggshell calcification**") containing fluid and budding cells that will eventually become daughter cysts. The outer wall is composed of gelatinous sheets surrounded by a thick fibrous capsule. Imaging (ultrasound, CT, MRI) and serology testing can be used for diagnosis.

Depending on the size of the cyst, surgery and adjunctive chemotherapy (eg, albendazole) are the treatment of choice for symptomatic patients. Cyst manipulation (eg, surgery, aspiration) should be performed with caution, as spilling of cyst contents can cause **anaphylactic shock**, which likely occurred in this patient.

(Choices B, C, D, and E) Fulminant liver failure can arise due to numerous conditions, including viral hepatitis, acetaminophen toxicity, idiosyncratic drug reactions, or Wilson disease. Hypovolemia is typically caused by severe blood loss, although excessive loss of other bodily fluids (eg, diarrhea, vomiting, burns, dehydration) may also be responsible. Pulmonary emboli are typically caused by the propagation of venous thrombi, with less common sources including air bubbles, fat droplets, amniotic fluid, or clumps of parasites or malignant cells. Overwhelming systemic infection with bacterial organisms can cause septic shock (hypotension, low blood flow). None of these conditions is typically associated with hydatid cysts.

Educational objective:
Echinococcus granulosus is the most common cause of hydatid cysts. Spilling of cyst contents can cause anaphylactic shock. Surgical manipulation should be performed with caution.

Pathophysiology	Infectious Diseases	Echinococcosis
Subject	System	Topic

Copyright © UWorld. All rights reserved.

A 72-year-old woman is brought to the emergency department from a nursing facility due to fever, chills, and hypotension. The patient has a history of diabetes mellitus, ischemic stroke, and neurogenic bladder. She has an indwelling urinary catheter. Temperature is 38.8 C (102 F), blood pressure is 80/40 mm Hg, and pulse is 130/min. The patient is lethargic and disoriented. Her extremities are warm, and her breathing is rapid and shallow. Lungs are clear on auscultation and there are no heart murmurs. There is left costovertebral angle tenderness. The urine in her catheter appears cloudy. Her leukocyte count is elevated with left shift, and urinalysis shows pyuria and bacteruria. Which of the following chemical mediators is most responsible for this patient's current condition?

A. Interleukin-3
B. Interleukin-4
C. Interleukin-10
D. Leukotriene B4
E. Transforming growth factor-beta
F. Tumor necrosis factor-alpha

Submit

A 72-year-old woman is brought to the emergency department from a nursing facility due to fever, chills, and hypotension. The patient has a history of diabetes mellitus, ischemic stroke, and neurogenic bladder. She has an indwelling urinary catheter. Temperature is 38.8 C (102 F), blood pressure is 80/40 mm Hg, and pulse is 130/min. The patient is lethargic and disoriented. Her extremities are warm, and her breathing is rapid and shallow. Lungs are clear on auscultation and there are no heart murmurs. There is left costovertebral angle tenderness. The urine in her catheter appears cloudy. Her leukocyte count is elevated with left shift, and urinalysis shows pyuria and bacteruria. Which of the following chemical mediators is most responsible for this patient's current condition?

A. Interleukin-3 (3%)
B. Interleukin-4 (5%)
C. Interleukin-10 (6%)
D. Leukotriene B4 (25%)
E. Transforming growth factor-beta (2%)
✓ F. Tumor necrosis factor-alpha (56%)

Omitted
Correct answer
F

56%
Answered correctly

02 secs
Time Spent

02/14/2020
Last Updated

Explanation

When observed in the setting of infection, the combination of hypotension, tachycardia, tachypnea, and markedly elevated or decreased body temperature is suggestive of **septic shock**. Early sepsis is characterized by peripheral vasodilation, a compensatory increase in cardiac output,

When observed in the setting of infection, the combination of hypotension, tachycardia, tachypnea, and markedly elevated or decreased body temperature is suggestive of **septic shock**. Early sepsis is characterized by peripheral vasodilation, a compensatory increase in cardiac output, and warm extremities.

Numerous **cytokines** are released in sepsis, resulting in widespread **systemic inflammation**. One of the most important mediators of sepsis is **tumor necrosis factor-alpha** (TNF-α), an acute-phase cytokine produced by activated macrophages. TNF-α stimulates systemic inflammation via recruitment of additional leukocytes (eg, neutrophils, macrophages) and increasing pro-inflammatory cytokine production. Other cytokines responsible for inducing the systemic inflammatory response in sepsis include IL-1 and IL-6.

(Choice A) IL-3 is a cytokine produced by activated T cells. It stimulates the growth and differentiation of stem cells in the bone marrow.

(Choice B) IL-4 is a cytokine produced by Th2 T-helper cells. It stimulates the growth of B cells and increases the number of Th2 T-helper cells at the site of inflammation.

(Choice C) IL-10 is an anti-inflammatory cytokine produced by macrophages and Th2 T-helper cells. IL-10 limits the production of pro-inflammatory cytokines (eg, interferon-gamma, IL-2, IL-3, TNF-α).

(Choice D) Leukotriene B4 is a metabolite of arachidonic acid. Its main function is to stimulate neutrophil migration to the site of inflammation.

(Choice E) Transforming growth factor-beta is released by macrophages and has anti-inflammatory roles in sepsis, including suppressing the release of IL-1 and TNF-α, and inhibiting lymphocyte proliferation.

Educational objective:
Tumor necrosis factor-alpha is released from activated macrophages and is one of the most important mediators of the systemic inflammatory response in sepsis. Other cytokines responsible for inducing the systemic inflammatory response include IL-1 and IL-6.

References

- Sepsis and septic shock.

Pathophysiology	Infectious Diseases	Sepsis
Subject	System	Topic

A 48-year-old homeless man is brought to the emergency department after being found unresponsive on the sidewalk. Medical history is unknown. Temperature is 38.3 C (101 F), blood pressure is 116/70 mm Hg, pulse is 108/min, and respirations are 26/min. Oxygen saturation is 88% on 100% oxygen via face mask. The patient is ill-appearing, thin, and disheveled with poor dentition. There are a few white patches on the oral mucosa, but no skin rash is present. Lung auscultation reveals bilateral crackles. There are healed abdominal scars from a previous surgery. The abdomen is soft with no hepatomegaly or splenomegaly. Chest x-ray reveals bilateral interstitial infiltrates. A silver-stained bronchoalveolar lavage specimen is shown in the image.

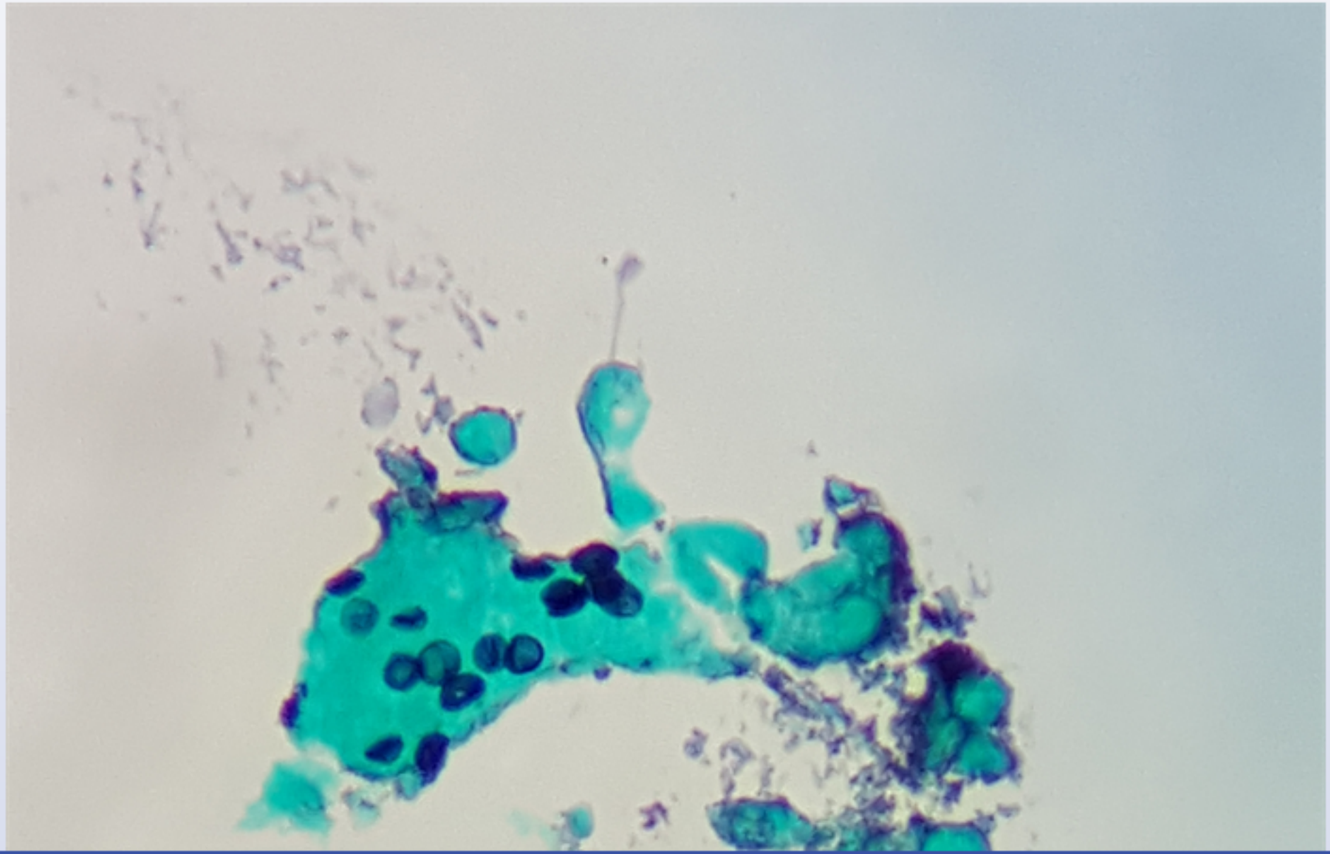

Settings

1
2
3
4

Item 4 of 4
Question Id: 14870

Mark | Previous | Next | Full Screen | Tutorial | Lab Values | Notes | Calculator | Reverse Color | Text Zoom | Settings

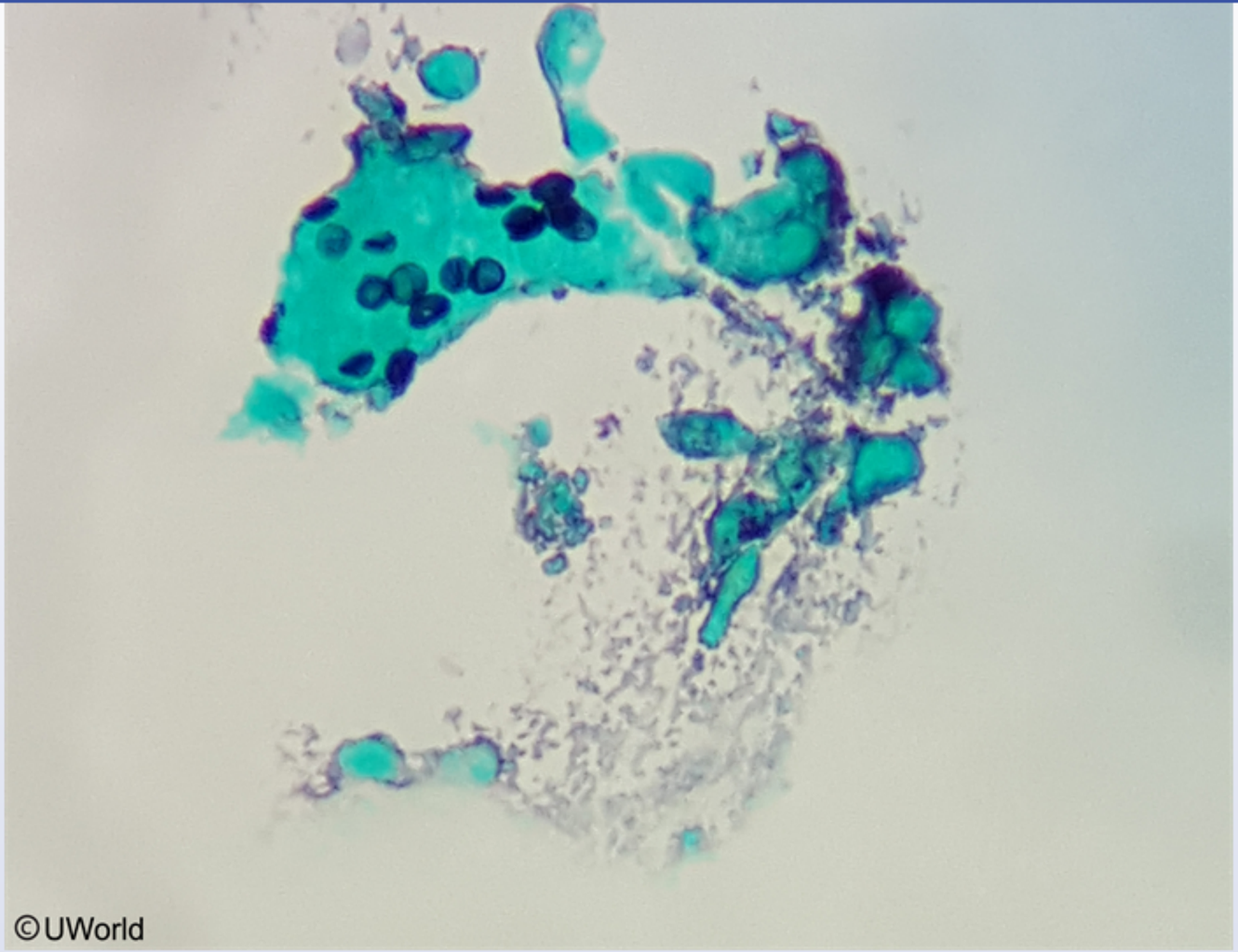

Which of the following most likely predisposed this patient to his current lung condition?

A. Aspiration of oropharyngeal secretion

Block Time Remaining: 00:01:54
TUTOR

3 | Feedback | Suspend | End Block

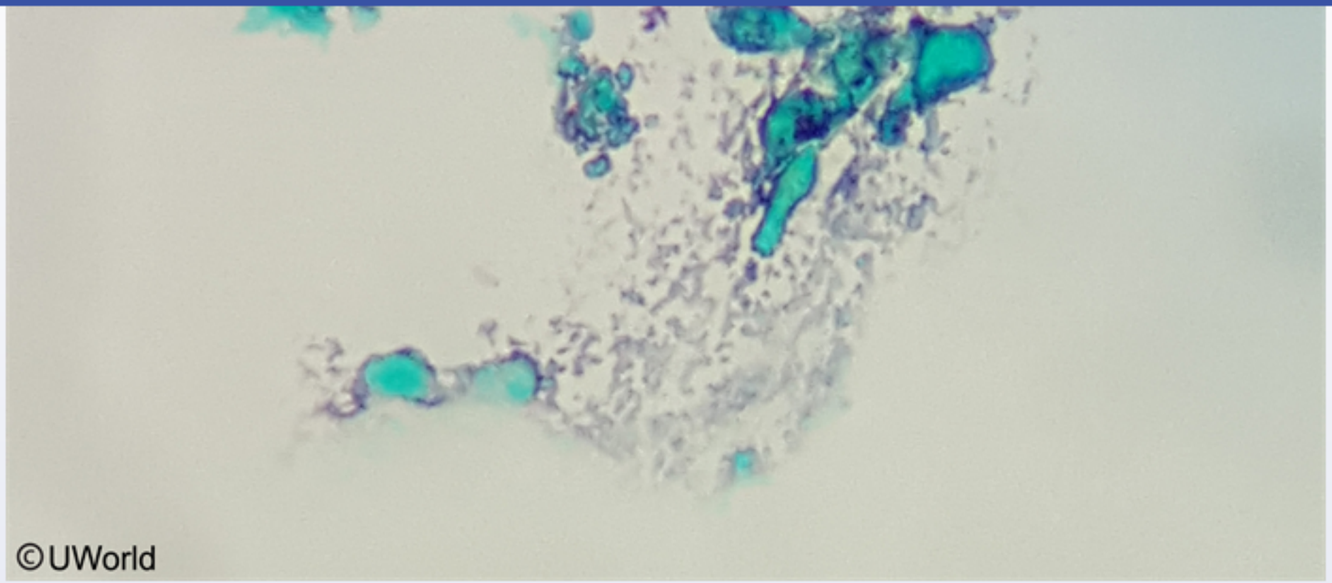

Which of the following most likely predisposed this patient to his current lung condition?

- A. Aspiration of oropharyngeal secretion
- B. Decreased mucociliary clearance
- C. Defective antibody-specific response
- D. Impaired cell-mediated immunity
- E. Postsplenectomy state

Submit

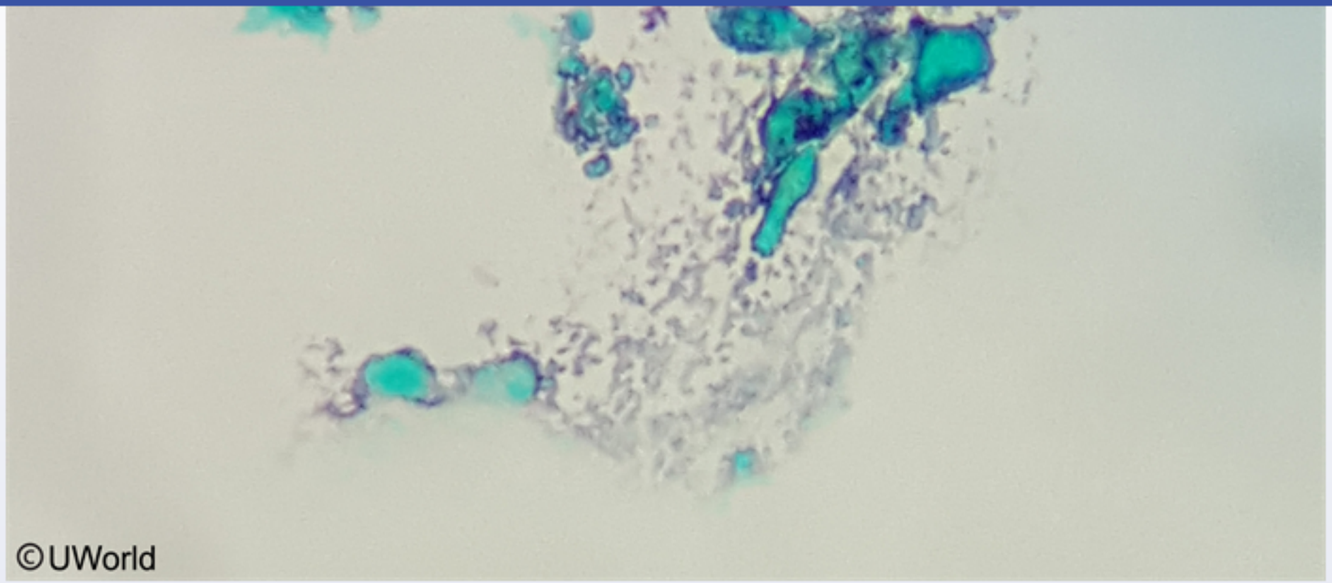

Which of the following most likely predisposed this patient to his current lung condition?

- A. Aspiration of oropharyngeal secretion (16%)
- B. Decreased mucociliary clearance (2%)
- C. Defective antibody-specific response (3%)
- ✓ D. Impaired cell-mediated immunity (71%)
- E. Postsplenectomy state (6%)

Omitted
Correct answer

71%
Answered correctly

12 secs
Time Spent

02/25/2020
Last Updated

Explanation

This homeless patient has hypoxia, bilateral interstitial infiltrates, and a positive silver stain indicating likely ***Pneumocystis* pneumonia** (PCP), an atypical fungal infection caused by the opportunistic pathogen *P jirovecii*. Inhalation of the organism leads to inoculation of the **alveolar space**. Healthy individuals rarely develop symptoms as alveolar monocytes and macrophages are stimulated by the cell-mediated immune response to rapidly clear the organism. However, patients with **impaired cell-mediated immunity**, particularly those with untreated **AIDS** (CD4 count <200/mm^3), often cannot eliminate the pathogen.

PCP typically manifests with slowly worsening pulmonary symptoms (eg, cough, dyspnea), hypoxia, and chest x-ray evidence of a diffuse, bilateral interstitial infiltrate. Because *P jirovecii* cannot be cultured, diagnosis is made by identifying the organism in respiratory secretions using specialized stains (eg, methenamine silver stain).

This patient also has oral pharyngeal candidiasis (white patches on the oral mucosa), an opportunistic infection often seen in those with impaired cell-mediated immunity.

(Choice A) Aspiration pneumonia is common in patients who have impaired levels of consciousness. It usually presents with cough productive of foul-smelling sputum, dyspnea, fever, and a lobar infiltrate on chest x-ray. Most cases are caused by a mixture of anaerobic organisms.

(Choices B and E) Cigarette smoking impairs the ability of the cilia to clear mucus, which can lead to recurrent bacterial pneumonia. Patients with splenectomy are at increased risk for fulminant bacterial infections, particularly with encapsulated organisms such as *Streptococcus pneumoniae*. Bacterial pneumonia usually presents with cough productive of sputum, dyspnea, fever, and a lobar infiltrate on chest x-ray. The presence of diffuse interstitial infiltrates and a positive silver stain make PCP more likely.

(Choice C) The humoral antibody response is important for the elimination of pathogenic bacterial and viral infections. Although viral pneumonia can cause bilateral interstitial infiltrates, viruses are not identified on silver stain.

Educational objective:
Pneumocystis pneumonia is an atypical fungal infection seen primarily in those with impaired cell-mediated immunity (eg, advanced AIDS). Manifestations often include slowly worsening pulmonary symptoms, hypoxia, and bilateral interstitial infiltrates on chest x-ray. The cystic organism can be visualized using silver stain of respiratory secretions.

rapidly clear the organism. However, patients with **impaired cell-mediated immunity**, particularly those with untreated **AIDS** (CD4 count <200/mm^3), often cannot eliminate the pathogen.

PCP typically manifests with slowly worsening pulmonary symptoms (eg, cough, dyspnea), hypoxia, and chest x-ray evidence of a diffuse, bilateral interstitial infiltrate. Because *P jirovecii* cannot be cultured, diagnosis is made by identifying the organism in respiratory secretions using specialized stains (eg, methenamine silver stain).

This patient also has oral pharyngeal candidiasis (white patches on the oral mucosa), an opportunistic infection often seen in those with impaired cell-mediated immunity.

(Choice A) Aspiration pneumonia is common in patients who have impaired levels of consciousness. It usually presents with cough productive of foul-smelling sputum, dyspnea, fever, and a lobar infiltrate on chest x-ray. Most cases are caused by a mixture of anaerobic organisms.

(Choices B and E) Cigarette smoking impairs the ability of the cilia to clear mucus, which can lead to recurrent bacterial pneumonia. Patients with splenectomy are at increased risk for fulminant bacterial infections, particularly with encapsulated organisms such as *Streptococcus pneumoniae*. Bacterial pneumonia usually presents with cough productive of sputum, dyspnea, fever, and a lobar infiltrate on chest x-ray. The presence of diffuse interstitial infiltrates and a positive silver stain make PCP more likely.

(Choice C) The humoral antibody response is important for the elimination of pathogenic bacterial and viral infections. Although viral pneumonia can cause bilateral interstitial infiltrates, viruses are not identified on silver stain.

Educational objective:
Pneumocystis pneumonia is an atypical fungal infection seen primarily in those with impaired cell-mediated immunity (eg, advanced AIDS). Manifestations often include slowly worsening pulmonary symptoms, hypoxia, and bilateral interstitial infiltrates on chest x-ray. The cystic organism can be visualized using silver stain of respiratory secretions.

Pathophysiology	Infectious Diseases	Pneumocystis pneumonia
Subject	System	Topic

Copyright © UWorld. All rights reserved.

Settings

1
2
3
4

Item 4 of 4
Question Id: 14870

Mark | Previous | Next | Full Screen | Tutorial | Lab Values | Notes | Calculator | Reverse Color | Text Zoom | Settings

Exhibit Display

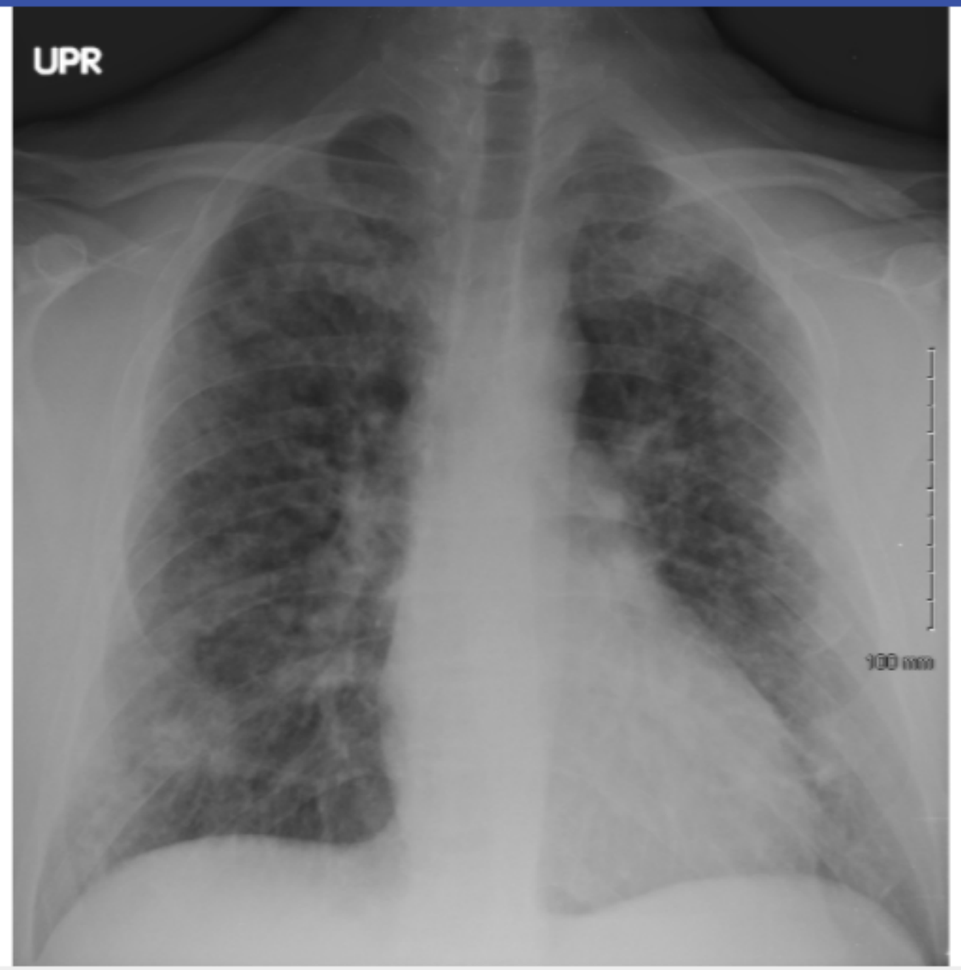

Zoom In | Zoom Out | Reset | Add To New Card | Existing Card

presence of diffuse interstitial infiltrates and a positive silver stain make PCP more likely.

Block Time Remaining: 00:01:58
TUTOR

3 | Feedback | Suspend | End Block

Settings

1
2
3
4

Item 4 of 4
Question Id: 14870

Mark | Previous | Next | Full Screen | Tutorial | Lab Values | Notes | Calculator | Reverse Color | Text Zoom | Settings

Exhibit Display

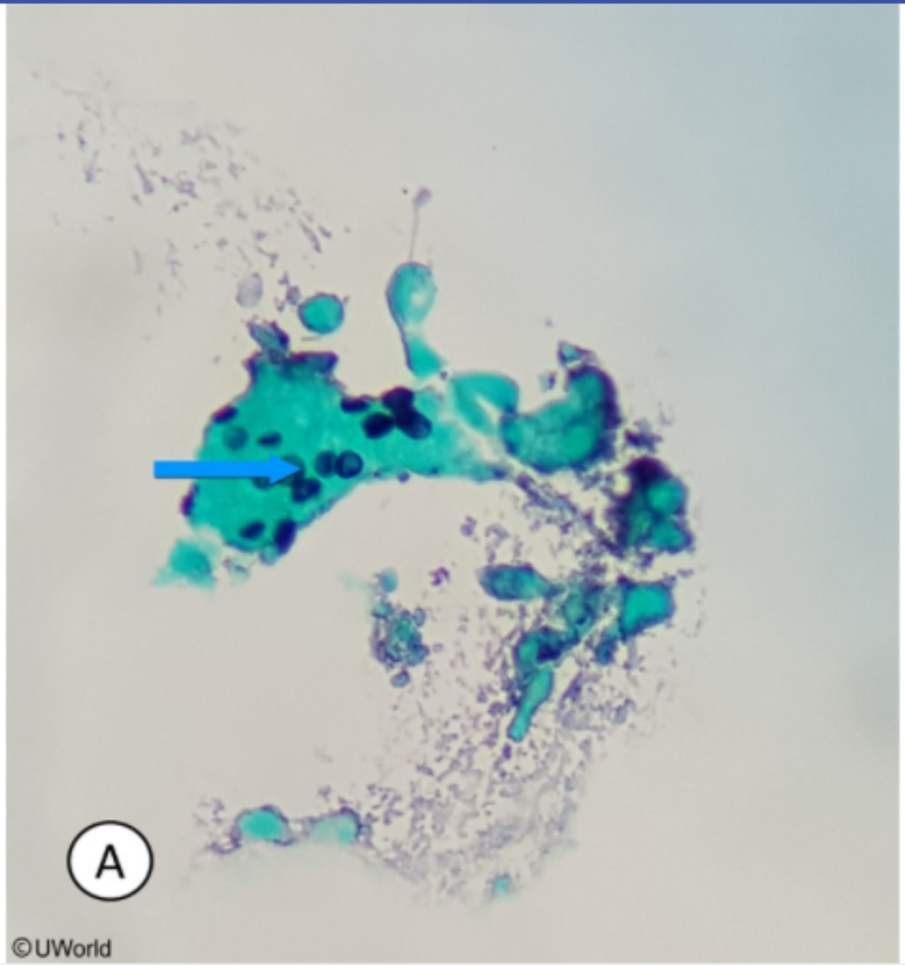

Zoom In | Zoom Out | Reset | Add To New Card | Existing Card

presence of diffuse interstitial infiltrates and a positive silver stain make PCP more likely.

Block Time Remaining: 00:01:58
TUTOR

3 | Feedback | Suspend | End Block